

ANATOMICAL VARIATIONS OF THE CHORDA TYMPANI NERVE

DRAGOSLAVA R. DJERIĆ, M.D., PH. D.

From the Clinic of Otorhinolaryngology, University Clinical Center, Pasterova, Belgrade, Yugoslavia.

ABSTRACT

The author studied anatomical variations of the origin of the chorda tympani nerve from the mastoid portion of the facial nerve. The studies were performed on 200 specimens of human temporal bone. It was found that the chorda tympani may arise from the facial nerve in three levels: most commonly from the mid third of its mastoid segment (70%), less commonly from the proximal third (20%), and very rarely from the distal third (10%). Knowledge of these variations has a certain value in surgical intervention of the middle ear.

MJIRI, Vol. 7, No. 1, 7-8, 1993.

Keywords: Chorda tympani, anatomy, surgical significance

INTRODUCTION

The chorda tympani nerve is the second branch of the nervus intermedius segment of the facial nerve and runs upward and anteriorly over the incus and under the malleus. The chorda tympani nerve traverses the tympanic cavity and exits the temporal bone through the petrotympanic fissure to join the lingual nerve. The chorda tympani nerve contains preganglionic secretory fibers to the submaxillary ganglion, and postganglionic fibers from which mediate secretory impulses to the submandibular and sublingual salivary glands, and to the small salivary glands in the oral cavity. It also carries sensory (taste fibers) from the anterior two-thirds of the tongue.

The chorda tympani nerve may show variations and anomalies in relation to its origin from the facial nerve as well as its course through the tympanic cavity. Saito et al. described that the chorda tympani originates below the stapedial branch of the facial nerve and a short distance above the stylomastoid foramen.¹ May cited that the chorda tympani usually arises from the distal third of the mastoid segment of the facial nerve.² Nager and Proctor noted that the origin of the chorda tympani may vary from 1 mm distal to 11 mm proximal to the stylomastoid foramen. They also observed an extratemporal origin of the chorda (2%), where it traveled in its own separate canaliculus parallel to the facial canal. Durcan et al. reported a bifurcation of the chorda tympani nerve in 3 cases.⁴

The purpose of this study is to examine and define anatomical variations of the origin of the chorda tympani nerve from the facial nerve which are of surgical significance.

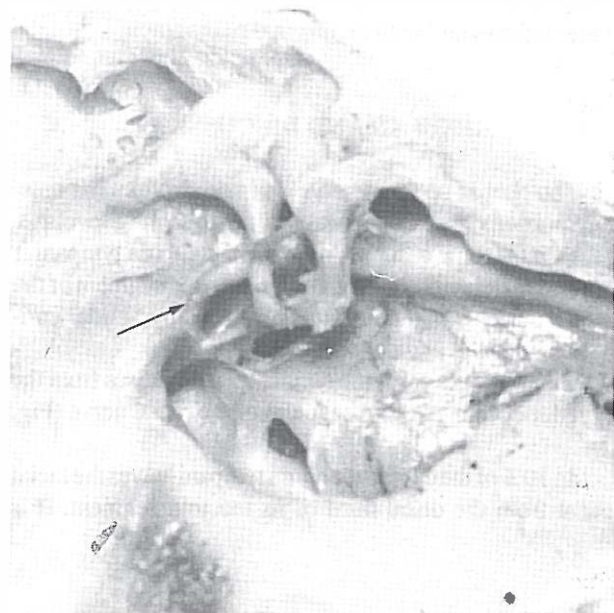


Fig. 1. Sagittal section of the temporal bone.

The origin of the chorda tympani is located in the proximal third of the mastoid segment of the facial nerve (arrow).

Variations of the Chorda Tympani Nerve

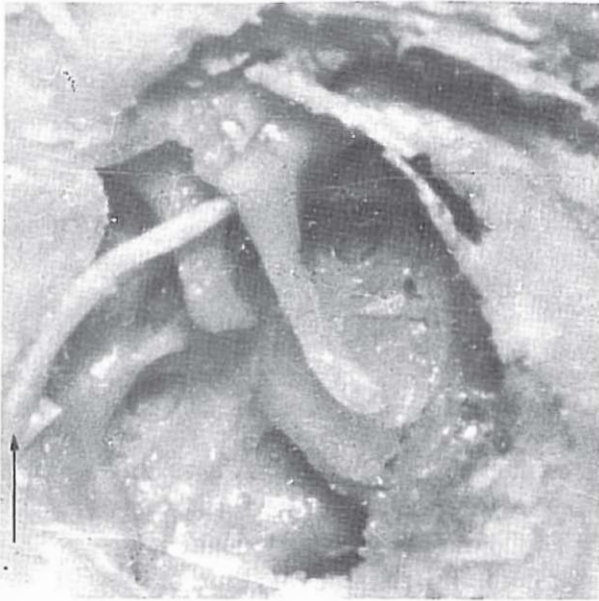


Fig. 2. Sagittal section of the temporal bone.
The origin of the chorda tympani nerve is located in the mid third of the mastoid segment of the facial nerve (arrow).

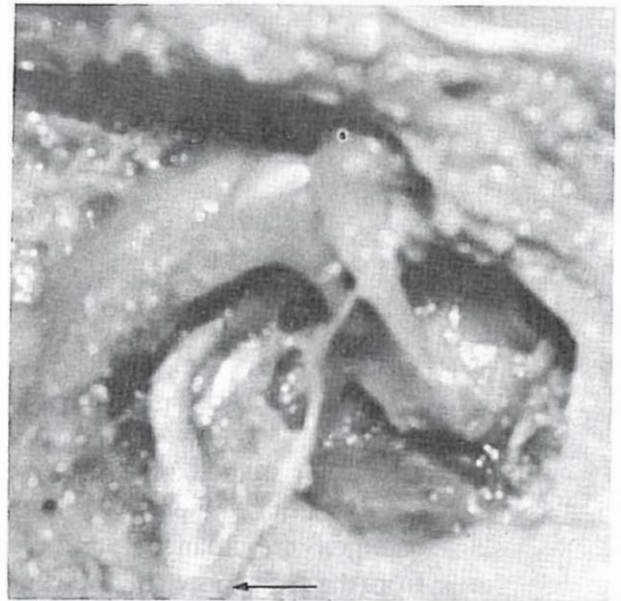


Fig. 3. Frontal section of the temporal bone.
The origin of the chorda tympani nerve is located in the distal third of the mastoid portion of the facial nerve (arrow).

MATERIAL AND METHOD

Studies were performed on 200 specimens of human temporal bones of adults of both sexes. The temporal bones were fixed in 10% buffered formalin, decalcified in 5% nitric acid, and rinsed with distilled water. Cutting was performed in sagittal and/or frontal planes. The examination was performed under an operating microscope and results were documented with an original photograph.

RESULTS AND DISCUSSION

The chorda tympani nerve takes origin from the mastoid portion of the facial nerve in the following levels:

In 20% of the cases the origin of the chorda tympani is located in the proximal third of the mastoid segment of the facial nerve. It is usually at level of the pyramidal eminence (Fig. 1).

In 70% of the cases the chorda tympani arises from the mid third of the mastoid segment of the facial nerve (Fig. 2).

In 10% of the cases the chorda tympani leaves the facial canal from the distal third of its mastoid segment. It is

located about 3 mm proximally to the stylomastoid foramen (Fig. 3).

Knowledge of these variations has a significant value in such surgeries of the middle ear as stapedectomy, posterior tympanotomy, mastoidectomy, decompression of the facial nerve, and others. In these interventions, otosurgeon must recognize and show the chorda tympani nerve and avoid its damage. Function of this nerve might be disrupted not only by cutting it but also with any kind of damage as traction and others.

REFERENCES

1. Saito H, et al: Course of the sensory component of the nervus intermedius in the temporal bone. *Ann Otol Rhinol Laryngol* 79: 960-6, 1970.
2. May M: *The Facial nerve*. New York: George Thieme Verlag, 21-44, 1986.
3. Nager G, Proctor B: Anatomical variations and anomalies involving the facial canal. *Ann Otol Rhinol Laryngol* 91: 45-61, 1982.
4. Durcan D, et al: Bifurcation of the facial nerve. *Arch Otolaryngol* 86: 619-31, 1967.