

Original Articles: Clinical Sciences

SYNCHRONOUS SURGICAL REMOVAL OF SUSPICIOUS OVARIAN METASTASES FROM COLORECTAL CANCER

MOHAMMAD TALEBPOOR,* M.D., MOJGAN KARBAKHSH,** M.D.,
M.P.H., SHOKOOFEH SABETI,*** M.D., AND MOOSA ZARGAR,# M.D.

*From Sina Trauma & Surgery Research Center, Sina Hospital, Tehran University of Medical Sciences,
Tehran, I.R. Iran.*

ABSTRACT

Metastatic ovarian cancers occur in 3-8 percent of women undergoing surgical resection of a primary colorectal cancer. In this study we examined the characteristics of women with colorectal cancer for whom synchronous oophorectomy had been performed.

In this cross-sectional study, records of patients with colorectal cancer from April 1991 through October 1999 who had undergone surgery for both colorectal cancer resection and oophorectomy for suspicious ovarian metastasis in the Cancer Institute, Imam Khomeini Medical Center, were reviewed. SPSS version 10 was used for statistical analysis.

The studied cases (n= 82) comprised 44.1 percent of all recorded cases of women with colorectal cancer during this period (N= 186). The mean age of our cases was 52.19 years. 54.9% of the studied women were in stage C of colorectal cancer. The commonest pathology of tumors was adenocarcinoma (89%). Well differentiated carcinoma was observed in 43.9%, followed by moderately differentiated carcinoma in 37.8%, poorly differentiated in 12.2% and unspecified in 6.1%. 22 of our patients (26.8%) had gross abnormalities of ovaries at operation. In 13 cases (15.8% of our 82 studied cases and 6.99% of all 186 women with colorectal cancer), tumoral involvement of ovaries was proven through pathologic examination. 10 out of these 13 cases were among those with gross abnormalities of ovaries at operation ($p= 0.048$). Among the 13 patients with ovarian metastasis, 11 cases (84.6%) were in stage C at operation ($p= 0.02$) and 7 (53.8%) had well differentiated carcinoma ($p= 0.04$).

Patients with ovarian metastases of colorectal origin are generally peri- or post-menopausal. Like similar studies, in our setting, about 7 percent of all recorded female

*Corresponding contributor. *Assistant Professor of Surgery, Sina Hospital, Tehran, Iran.

**Assistant Professor of Community Medicine, Sina Trauma and Surgery Research Center, Tehran, Iran.

***Clinical investigator, Tehran University of Medical Sciences, Tehran, Iran.

#Associate Professor of Surgery; Head, Sina Trauma and Surgery Re-

search Center, Tehran, Iran.

Address: Sina Trauma & Surgery Research Center, Sina General Hospital, Hassan-Abad Sq., Imam-Khomeini St, Tehran Iran.

Telephone: +98 21 671 7422 - +98 21 670 5140 - +98 21 670 5511

+98 21 670 5503 - +98 21 670 5576 - +98 21 670 5524

P.O.Box: 11365/3876, Fax: +98 21 6705140, E-mail:

Ovarian Metastases from Colorectal Cancer

cases with colorectal cancer turned out to have ovarian metastases in surgical pathologic examination. In fact, 15.8% of our 82 cases sustaining surgery for "colorectal cancer and suspicious ovarian metastasis" proved to have ovarian metastasis. We recommend that prophylactic oophorectomy be performed in postmenopausal women with advanced stage colorectal cancer or any other woman with colorectal cancer with gross abnormality of the ovaries at operation.

MJIRI, Vol. 18, No. 4, 285-288, 2005.

Keywords: Ovarian metastasis, Colorectal cancer, Oophorectomy.

INTRODUCTION

Colorectal cancer is a common malignancy among women, which may metastasize to the ovaries. Metastatic ovarian cancers occur in 3-8 percent of women undergoing surgical resection of a primary colorectal cancer.¹ In this study we examined the characteristics of women with colorectal cancer for whom synchronous oophorectomy had been performed.

MATERIAL AND METHODS

In this cross-sectional study, records of patients with colorectal cancer from April 1991 through October 1999 who had undergone surgery for both colorectal cancer resection and oophorectomy for suspicious ovarian metastasis (either because of the advanced nature of the primary tumor or gross abnormality of the ovaries at laparotomy) in the Cancer Institute, Imam Khomeini Medical Center, were reviewed. In these 82 cases, the following characteristics were studied: age at diagnosis, menstrual status, anatomical site of GI involvement, stage of colorectal cancer, macroscopic abnormalities of ovaries at surgery, co-morbidities, ovarian metastases, tumor pathology, tumor grades, peritoneal involvement, CEA, lymph node involvement and distant metastases. In order to calculate the prevalence of ovarian metastasis in women with colorectal cancer, the number of the latter according to medical records in the Cancer Institute were also counted. SPSS version 10 was used for statistical analysis.

$\alpha = 0.05$ was considered as the level of significance.

RESULTS

The studied cases ($n = 82$) comprised 44.1 percent of all recorded cases of women with colorectal cancer during this period ($N = 186$). The mean age of our cases was 52.19 years (0.95CI = 49.06-55.33). The age distribution of these patients is demonstrated in Figure 1. Fifty-five of our cases (67.1%) were postmenopausal at the time of the study.

In 64 of our patients (78%), the site of colorectal can-

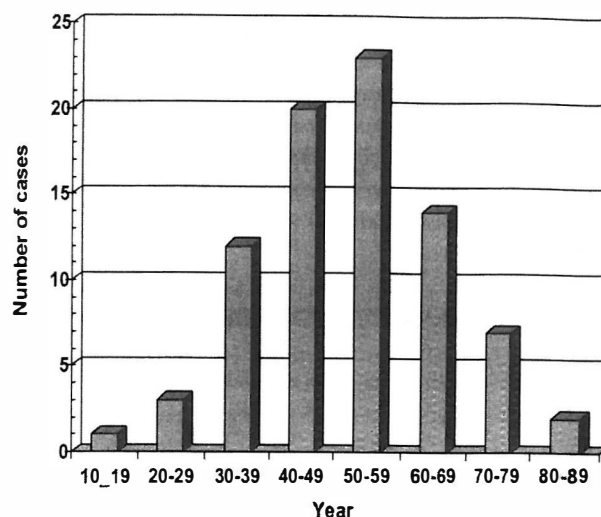


Fig. 1. The age distribution of patients undergoing synchronous oophorectomy for suspicious metastatic ovarian carcinoma from colorectal cancer.

cer had been the rectum, in 13 (15.8%) the colon was primarily involved and in 3 (3.6%), both colon and rectum were cancerous.

In 45 cases (54.9%), regional lymph nodes were involved. In fact, more than half of these women (54.9%) were in stage C of colorectal cancer, 30.5% in stage B, and 8.5% in stage A (and 6.1% were unknown). The most common pathology of tumors was adenocarcinoma (89%). Other observed pathologies were squamous cell carcinoma in 3 (3.6%), anaplastic tumor in 2 (2.4%) and colloid carcinoma in 1 (1.2%).

Considering the grading of tumors, well differentiated carcinoma was observed in 36 (43.9%), followed by moderately differentiated carcinoma in 31 (37.8%), poorly differentiated in 10 (12.2%) and unspecified in 5 cases (6.1%).

22 of our patients (26.8%) had gross abnormalities of the ovaries at operation. In 13 cases (15.8% of our 82 studied cases and 6.99% of all 186 women with colorectal cancer), tumoral involvement of the ovaries was proven

through pathologic examination. 10 out of these 13 cases were among those with gross abnormalities of ovaries at operation ($p= 0.048$). Among the 13 patients with ovarian metastasis, 11 cases (84.6%) were in stage C at operation ($p= 0.02$) and 7 (53.8%) had well differentiated carcinoma ($p= 0.04$). 12 of our patients (14.4%) had liver and lung metastasis who were all in stage C of colorectal cancer.

DISCUSSION

The ovaries provide fertile soil for metastases and are the most commonly involved organs in the female genital tract, regardless of the location of the primary tumor. The recognition of an ovarian tumor as metastatic is of vital clinical importance, determining the appropriate management and the likely outcome of the patient. Such recognition will also depend on awareness of the frequency of metastases to the ovary from different primary sites. There is a general agreement that most ovarian metastases are from the breast, gastrointestinal tract and female genital tract.² In fact, the most commonly occurring metastatic carcinoma to mimic primary ovarian carcinoma is that of large bowel origin.³ According to Iranian National Cancer Statistics in 1999,⁴ colorectal cancer is the 5th most common cancer in Iranian women (with adjusted incidence of 5.2 in 100,000) and the 7th most common reason for cancer-related death among women (with adjusted death rate of 2.7 in 100,000).

Patients with ovarian metastases of colorectal origin are generally peri- or postmenopausal.⁵ In our study, 67.1 percent of the cases suspicious of having metastatic ovarian tumor from colorectal cancer were postmenopausal. This has an important clinical implication for the surgeon as some experts even recommend that bilateral prophylactic oophorectomy should be performed in all postmenopausal women at the time of initial colorectal surgery.^{5,6}

The exact incidence of ovarian metastasis from colorectal cancer is difficult to determine. In post-mortem studies, 3-5% of female patients demonstrated colorectal ovarian metastases.^{7,8} In clinical studies, however, the rate varies from 0 to 8.6% with a median overall incidence of 3.4%.⁹ In our setting, about 7 percent of all recorded female cases with colorectal cancer (in the defined cross-sectioned time period) turned out to have ovarian metastases in surgical pathologic examination. In fact, 15.8% of our 82 cases undergoing surgery for "colorectal cancer and suspicious ovarian metastasis" proved to have ovarian metastasis.

In our study, the macroscopic involvement of ovaries was evident in 10 out of 13 cases with ovarian metastasis (76.9%). This also has a surgical implication as some authors recommend that oophorectomy should be

performed when the ovaries are macroscopically affected.⁶

Although it is said that the differentiation of the primary colorectal cancer is not a risk factor for the development of ovarian metastasis,⁶⁻¹⁰ we observed a higher frequency of metastasis in those with well-differentiated carcinoma; this might have been due to the more smooth nature of colorectal cancer in these patients which provided them with a higher opportunity to come to the hands of surgeons for resection (and thus being included in our dataset).

We also observed that colorectal tumors in stage C had more frequently metastasized to the ovaries. Other studies support this relationship by indicating that most bowel tumors with ovarian metastases are Duke's stage B or more advanced.⁹

Although there is no evidence that prophylactic bilateral oophorectomy at the time of colorectal resection gives a survival advantage,¹¹⁻¹³ some authors believe that prophylactic oophorectomy may reduce the chance of a second laparotomy for metastatic disease. In addition, the ovaries appear to be a fertile bed for metastases and a sanctuary site from chemotherapy.⁹ It should also be noted that women with colorectal carcinoma have an increased risk of developing primary ovarian carcinoma.⁵ So in the case of prophylactic oophorectomy, the increased risk of developing primary ovarian cancer is also abolished.¹⁴

We recommend that prophylactic oophorectomy be performed in postmenopausal women with advanced stage colorectal cancer or any other patient with colorectal cancer with gross abnormality of the ovaries at operation.

ACKNOWLEDGEMENT

We thank all the technical staff of the Cancer Institute at Iman Khomeini Medical Center, Tehran University of Medical Sciences, especially Mr. Hojjat Zeraati, director of medical recording sector, Cancer Institute for his kind assistance in access to necessary datasets.

REFERENCES

1. Rayson D, Bouttell E, Whiston F, Stitt L: Outcome after ovarian/adnexal metastatectomy in metastatic colorectal carcinoma. *J Surg Oncol* Nov 75(3): 186-92, 2000.
2. Russell P, Farnsworth A: Tumors metastatic to the ovaries. Metastases from the female genital tract and breasts. In: Russell P, Farnsworth A, (eds.), *Surgical Pathology of the ovaries*. Chapter 53, 2nd edition, Churchill Livingstone, pp. 597-608, 1997.
3. Daya D, Frank GL: Metastatic ovarian carcinoma of large intestinal origin simulating primary ovarian carcinoma.

Ovarian Metastases from Colorectal Cancer

- American Journal of Clinical Pathology 97: 738-751, 1992.
4. Shamsa AZ, Mohgheghi MH: National Project for Cancer Registry. Proposing a model by the National Cancer Registry. Final report of the project sponsored by Cancer Institute of Tehran University of Medical Sciences and the Deputy of Research, Ministry of Health, Treatment and Medical Education. Islamic Republic of Iran, 2002.
 5. Russel P, Farnsworth A: Metastatic gastrointestinal carcinomas and carcinoids. In: Russel P, Farnsworth A, (eds.), Surgical Pathology of the Ovaries. Chapter 54, 2nd edition, Churchill Livingstone, pp. 609-624, 1997.
 6. Perdomo JA, Hizuta A, Iwagaki H, Takasa S, et al: Ovarian metastasis in patients with colorectal carcinoma. Acta Med Okayama Feb; 48(1): 43-6, 1994.
 7. Koves I, Vamosi-Nagy I, Besnyak I: Ovarian metastases of colorectal tumours. Eur J Surg Oncol 19 (Suppl.1): 633-5, 1993.
 8. Fujiwara K, Ohishi Y, Koike H, Sawada S, Moriya T, Kohna I: Clinical implications of metastases to the ovary. Gynecol Oncol 59: 124-128, 1995.
 9. Pitt J, Dawson PM: Oophorectomy in women with colorectal cancer. European Journal of Surgical Oncology 25: 432-438, 1999.
 10. Herrera-Ornelas L, Mittleman A: Results of synchronous surgical removal of primary colorectal adenocarcinoma and ovarian metastases. Oncology 41: 96-100, 1984.
 11. Cutail R, Lesser ML, Enker WE: Prophylactic oophorectomy in surgery for large-bowel cancer. Dis Colon Rectum 26: 6-11, 1982.
 12. Ballantyne GH, Reigel MM, Wolfe BG, Ilstrup DM: Oophorectomy and colon cancer; impact on survival. Ann Surg 202: 209-14, 1985.
 13. Sielezneff I, Salle E, Antoine K, Thirion X, et al: Simultaneous bilateral oophorectomy does not improve prognosis of postmenopausal women undergoing colorectal resection for cancer. Dis Colon Rectum 40: 1299-302, 1997.
 14. Schofield A, Pitt J, Biring G, Dawson PM. Oophorectomy in primary colorectal cancer. Ann R Coll Surg Engl May; 83 (2): 81-4, 2001.