

## RIGHT VENTRICULAR FATTY INFILTRATION IN MITRAL STENOSIS, A RARE CAUSE OF SURGICAL FAILURE.

\* F. NOOHI, M.D., \*\* A. MOHEBBI, M.D., \*\*\* A.A. PETROSSIANS,  
M.D., \*\*\*\* D. EKHTERAII, M.D., AND † A. ALGHABI, M.D.

*From the Cardiovascular Research Center, Rajaie Heart Hospital, Iran University of Medical Sciences,  
Tehran, Islamic Republic of Iran.*

### ABSTRACT

A 47 year-old female died after mitral valve replacement. Post-cardio-pulmonary bypass right ventricle was not able to pump despite good left ventricular contractility. At microscopic examination, diffuse right ventricular fatty infiltration was found. We found no previous report of this pathology in patients with mitral stenosis.

*MJIRI, Vol. 6, No. 4, 307-308, 1993.*

*Keywords: Fatty infiltration, Cardiopulmonary bypass, Right ventricle*

### CASE REPORT

A 47 year-old female referred with dyspnea and palpitation (New York Heart Association functional class II). The patient was a known case of rheumatic fever and mitral stenosis being followed in another institution. She had a history of an episode of emboli to femoral artery for which embolectomy was done successfully years back.

On admission, physical examination showed a well-nourished and well-developed female with a weight of 62 kg, a heart rate of 65 beats per min, and blood pressure of 110/80mmHg. There were rales in both lower lung fields. A diastolic rumbling murmur with presystolic accentuation and an opening snap was heard at the left sternal border and axilla. Liver was palpated 1cm below right costal margin. Electrocardiography showed atrial fibrillation with normal axis without rapid ventricular response. CXR showed straightening of left heart border and pulmonary knob was prominent. Two dimensional echocardiography showed left atrial

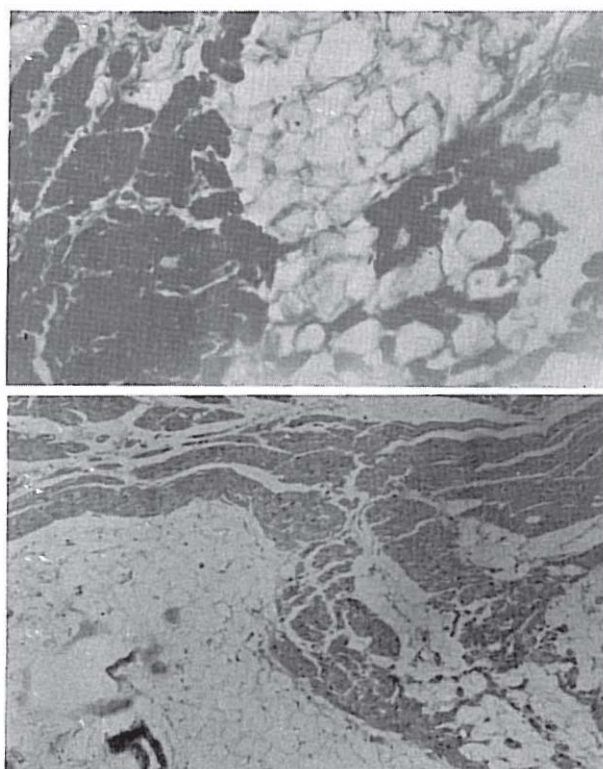
\* Associate Professor,

\*\* Assistant Professor, and

\*\*\* Fellow in Adult Cardiology,

\*\*\*\* Assistant Professor in Cardiac Surgery,

† Pathologist



**Figs. 1 and 2:** Fatty infiltration extending from epicardial to endocardial area compressing muscle bundles.

## Fatty Infiltration in MS

enlargement (4.75cm), mitral valve area 1.32cm, LVEDD: 4.85 and LVESD: 3.50cm, right ventricular internal diameters were normal. Cardiac catheterization revealed pulmonary pressure 48/28mmHg, elevated wedge pressure (30mmHg) and dome shaped and irregular mitral valve.

The patient was treated with digoxin, triamterene and hydrochlorothiazide and consulted for surgical intervention. Mitral valve replacement was suggested. The patient underwent operation for mitral valve replacement but unfortunately after operation and during post-pump period, right ventricle was not able to beat. Left ventricle contracted normally despite the fact that right ventricle could not function. At necropsy, the heart weighed 300g. Endocardial surface was normal, left ventricle was normal. Section of the right ventricle showed that bundles of myocardium have been separated from each other by abundant mature fat tissue. The trapped bundles were also atrophic. This fatty infiltration of the myocardium involves two-thirds of the thickness of the ventricle beneath the epicardium. No evidence of inflammation or infarction was seen.

## DISCUSSION

There is only cardiomyopathy and heart failure with low ejection fraction which causes pump failure. Right ventricular fatty infiltration has never been reported either as consequence of mitral stenosis or a cause of pump failure. Fatty infiltration of the right ventricle has been reported in cases with obesity,<sup>1,2</sup> but rarely reported in normal weight persons. In this rare case which was proved by pathological examination, this rare phenomenon is demonstrated but the mechanism of this process is not clear.

## REFERENCES

1. Bedford E: The story of fatty heart: a disease of Victorian times. *Brith Hearth Journal* 34:23, 1972.
2. Saphir O, Corrigan M: Fatty infiltration of the myocardium. *Arch Inter Med.* 52:410, 1933.