

PITUITARY DEPENDENT CUSHING'S SYNDROME IN IRAN

DJ. MOFID, M.D., A.A.M.S. GHAZI, M.D., A.A.
TAVAKKOLPOUR, M.D., AND M.T. SALEHIAN, M.D.

*From the Department of Surgery, Taleghani Hospital, Shaheed Beheshti University of Medical Sciences, Tehran,
Islamic Republic of Iran.*

ABSTRACT

During a 5-year experience with 32 adrenal tumors with different basic problems in the Department of Endocrinology, Taleghani Hospital, 25 were found pituitary dependent Cushing's syndrome, "Cushing's disease." The treatment of patients with Cushing's disease depends on the presence or absence of pituitary tumor. If no pituitary tumor is demonstrated, irradiation can be given to the pituitary gland and if a pituitary tumor is present, hypophysectomy is the treatment of choice. If pituitary ablation fails to relieve the symptoms of Cushing's syndrome, bilateral adrenalectomy is usually performed through the posterior approach. With regard to the poor results of radiation and hypophysectomy in Iran, these patients were referred directly for bilateral adrenalectomy to the Department of Surgery, Taleghani Hospital. The disease was predominately seen in the young age group, females were more frequently affected than males and the common manifestation of hyperadrenocorticism were obesity, plethora, amenorrhea, and hirsutism. The diagnosis was made by a series of laboratory, roentgenographic, and C.T. scan studies. The surgical ablation of the target organs was usually performed by the posterior approach, and the pathologic results of operated patients were nodular hyperplasia and diffuse hyperplasia.

MJIRI, Vol.5, No. 1,2, 29-33, 1991

INTRODUCTION

In 1932, Harvey Cushing described a syndrome characterized by weakness, central obesity, cutaneous stria, plethora, diabetes mellitus, hypertension, and osteoporosis.¹ He believed that it represented a disorder of the pituitary gland that he called "pituitary basophilism." It was later established that the findings were secondary to excessive production of cortisol.

Cushing's syndrome may be caused by three basic problems:

(1) Cushing's disease,² resulting from excess production of ACTH by the pituitary gland owing to either a pituitary adenoma or, more commonly, increased production of corticotropin releasing factor (C.R.F.)

Table I. Estimated frequency of manifestations of 27 of 32 hyperadrenocorticism in Taleghani Hospital and the literature

Signs and symptoms	Literature (189 case) %	Taleghani Hospital (27 case) %
obesity	97	69
plethora	50	96
amenorrhea	81	94
hirsutism	69	94
fatigue and weakness	50	81
cutaneous stria	67	78
hemorrhagic manifestations	23	79
diabetes mellitus (FBS>140 mg/dl)	20	69
personality changes	66	63
hypertension (BP>160/90 mm Hg)	85	52

Cushing's Syndrome in Iran

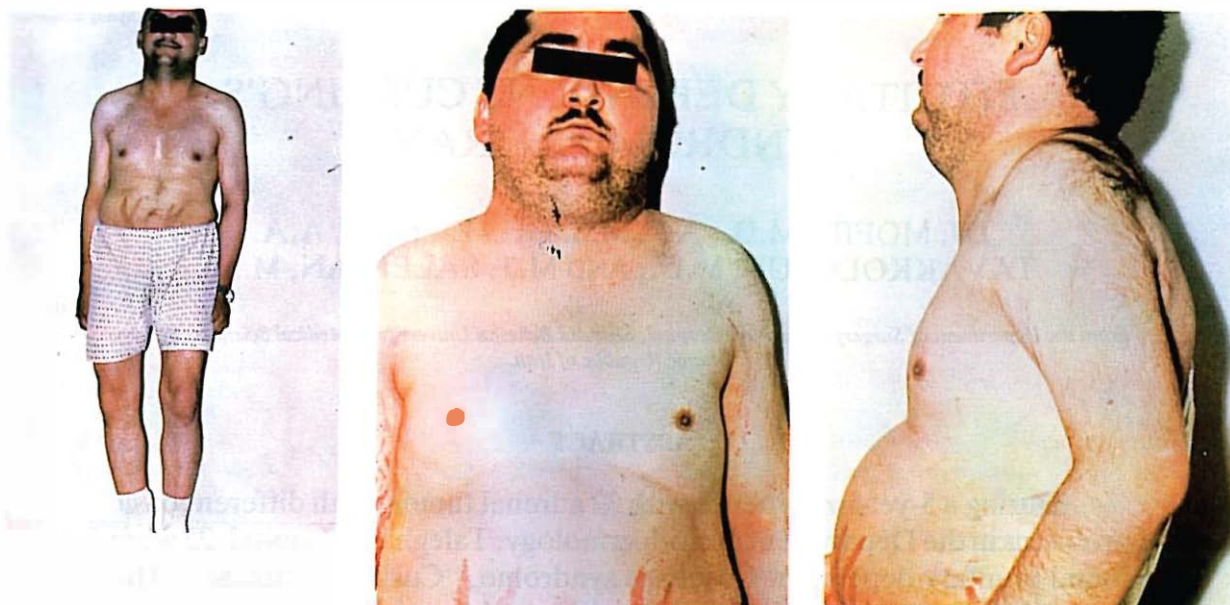

Fig 1. Cushing's syndrome. A: Despite the marked obesity and protuberance of the abdomen, the extremities are thin. B: Lateral view of the same patient.

Table II. Types of Cushing's syndrome in Taleghani Hospital

pituitary dependent Cushing's syndrome	25
Cushing's syndrome due to oat cell carcinoma of the lung	1
Cushing's syndrome due to a renal carcinoma	1
Cushing's syndrome due to adrenal tumor	1
under work-up	4
total	32

by the hypothalamus, which accounts for about 70% of all cases of Cushing's syndrome.

(2) An extra adrenal ACTH producing tumor, most commonly oat cell carcinoma of the lung, thymic tumors, and islet cell tumor of the pancreas which accounts for 5 to 10 percent of all cases of Cushing's syndrome.³

(3) Primary tumor of the adrenal cortex, either benign adenoma or malignant adenocarcinoma or nodular dysplasia which accounts for about 20 percent of all cases of Cushing's syndrome (Table II).²

With regard to the Endocrinology Department of Taleghani Hospital experiences, the efficacy and result of radiation and hypophysectomy is not good enough and valuable in Iran. Therefore, the Endocrinology Ward referred patients with Cushing's disease for bilateral adrenalectomy to the Surgery Ward.

MATERIALS AND METHODS

The differential diagnosis in Cushing's syndrome is made by a series of laboratory and other studies. All patients had high serum cortisol levels, with the loss of normal circadian rhythm of cortisol.⁵ Low doses of dexamethasone (2 mg) will suppress serum cortisol

Table III. Dexamethasone suppression test. The effect of a low and high dose of dexamethasone on 17-OHCS, 17-KS, and urine free cortisol in Taleghani Hospital cases

Test	Serum Cortisol	Urine Free Cortisol	17-Ketosteroids	17-OH Corticosteroids
Base	41.5 ± 24	719 ± 806.9 Range: 128-2756	17.4 ± 10.2	21.5 ± 12.6
Low Dose	25 ± 8.7	Range: 128-2756	15.7 ± 10.2	11.5 ± 8.8
High Dose	19.7 ± 17	Range: 128-2756	15.9 ± 13.7	9.9 ± 8.1

Normal Range: (1) Cortisol: 8-28 µg/dl
(2) 17-Ketosteroids: 5-14 mg/24 hr
(3) 17-OH corticoids: 9-17 mg/24 hr
(4) Urine free cortisol: 35-120 µg/24 hr

level in normal subjects but not in patients with Cushing's syndrome.⁶ High doses of dexamethasone (2 mg four times for two days) will suppress cortisol level in patients with bilateral adrenal hyperplasia due to Cushing's disease.

Those patients in whom high doses of dexamethasone does not suppress serum cortisol level, will have either a primary adrenal tumor or an extra-adrenal ACTH producing tumor. The ACTH level then must be measured. If it is low, it indicates suppression by the cortisol produced by the adrenal tumor, whereas if it is high, it indicates excess ACTH production from an extra-adrenal source.

Urinary free cortisol is usually elevated, as are the metabolites of cortisol (17-hydroxycorticosteroids). In patients exhibiting virilism, the 17-ketosteroids are usually elevated (Table III).⁷

It is important for the surgeon to localize an adrenal tumor causing Cushing's syndrome. CT-scanning has

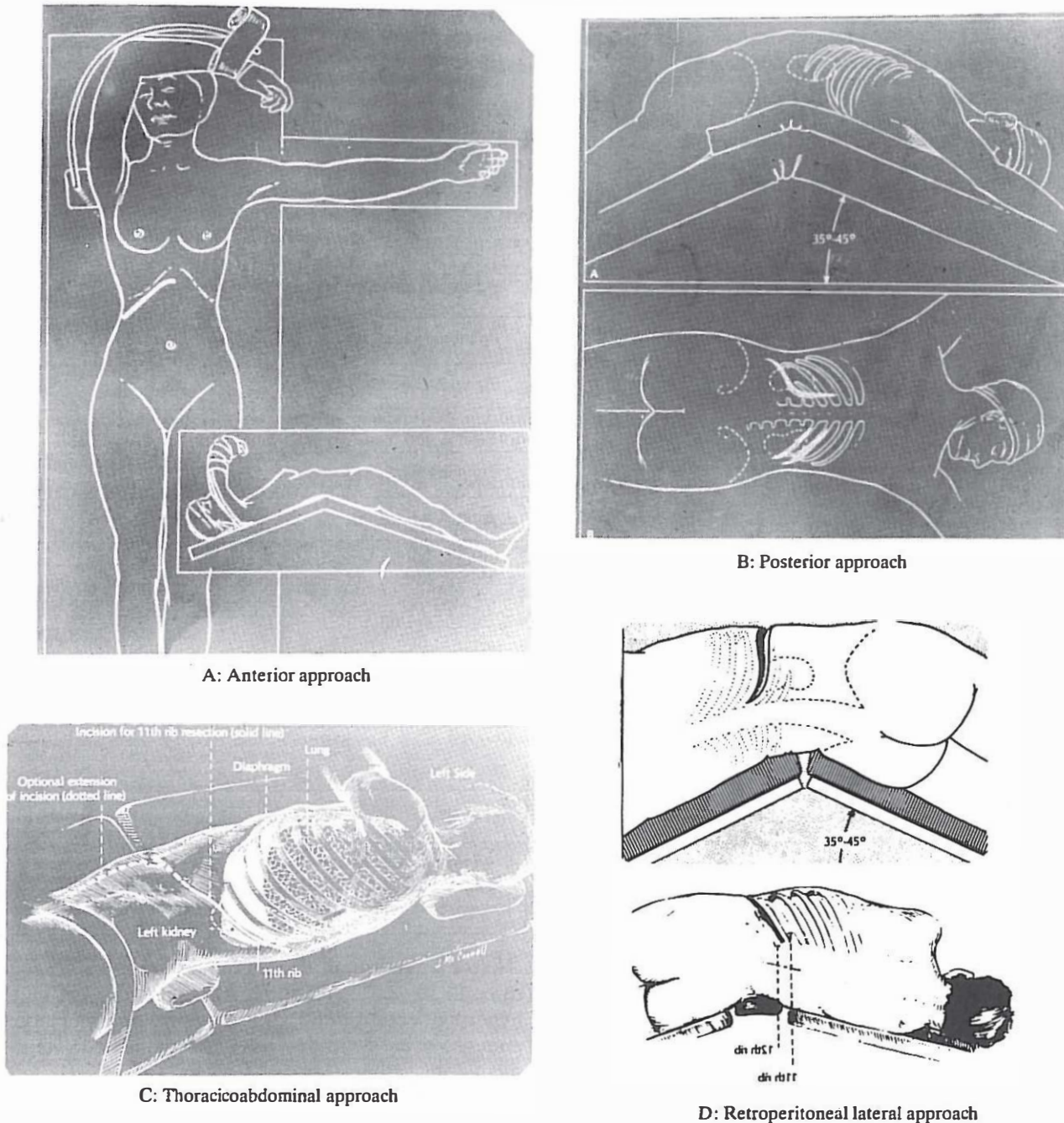


Figure 2. Four different approaches of adrenalectomy.

been both cost effective and accurate in localizing adrenal tumor as well as delineating their relationship to surrounding structures.⁸

Adrenal angiography and adrenal venogram, are seldom obtained,⁹ and a polytomogram of the sella turcica will usually identify small pituitary tumors.

The treatment of patients with Cushing's disease depends on the presence or absence of a pituitary tumor. If no pituitary tumor is demonstrated irradiation can be given to the pituitary gland. If a pituitary tumor is present, hypophysectomy is the treatment of

choice.¹¹ If these procedures fail to relieve the symptoms of Cushing's disease, bilateral adrenalectomy is performed.¹² Radical adrenalectomy is indicated in most cases of primary adrenal tumor. Since it may be difficult for the surgeon to be sure whether the patient has a benign or malignant adenoma preoperatively in most patients, this procedure is easily performed through a posterior approach. The posterior approach, performed through incision on each side of the spine, through the bed of the 11th or 12th rib, with the patient lying prone, is better tolerated postoperatively but

Cushing's Syndrome in Iran

Table IV. Comparisons of different approaches in the treatment of Cushing's syndrome in Taleghani Hospital

Posterior approach	21
anterior approach	2
lateral approach	1
thoracoabdominal approach	1
total	25

gives only limited exposure. The anterior or transperitoneal approach through a bilateral subcostal incision, anterior Chevron incision, is used mostly for pheochromocytoma. Unfortunately, the postoperative period is painful. Ileus is a problem and the patient is exposed to the risks of poor healing, such as evisceration. If the adrenal tumor is quite large and particularly if it involves the right adrenal gland, a thoracoabdominal approach should be used. This gives a better exposure, allows excellent vascular control, and permits removal of very large adrenal tumors.

A lateral approach through the bed of the 11th rib, exposing the adrenal retroperitoneally, is seldom used because it gives rather poor exposure to the adrenal gland (Fig. 2), (Table IV).

RESULTS

The treatment of patients with Cushing's syndrome due to extra-adrenal ACTH-producing tumor is removal of the primary tumor, if possible. Unfortunately, many of these tumors are malignant and have already metastasized. In these cases bilateral total adrenalectomy through the posterior approach should be considered,¹² if the neoplastic process is not far advanced.

All patients having surgical extirpation of an adrenal tumor involving one adrenal gland or bilateral adrenalectomy should be prepared with cortisol administration preoperatively, intraoperatively, and postoperatively. Since adrenal carcinomas are resistant to radiotherapy and not dramatically responsive to chemotherapy with mitotane (O,P-DDD, Lysodren), (a DDT derivative that is toxic to the adrenal cortex but has serious side effects at effective doses) complete surgical removal offers the only real hope for survival in adrenal carcinomas.¹³

Surgical results and comparison of mortality and complications of 25 cases by the author in Taleghani Hospital and Professor K. Rhamy of Vanderbilt University, Nashville, Tennessee,¹⁴ is presented in Table V. In our experience, the results of treatment in Cushing's disease are excellent unless one is dealing with adrenocortical carcinoma.

Approximately 10 percent of patients subjected to bilateral adrenalectomy will develop a pituitary tumor that is nearly always an ACTH chromophobe adenoma

Table V

	28 cases Professor K. Rhamy	25 cases Taleghani Hospital
Mortality	3.4%	-
Wound Infection (staphylococcal)	21%	Two Cases
Laceration of Vena Cava	3%	-
Laceration of Adrenal Vein	-	Two Cases
Pulmonary Embolism	3%	-
Renal Failure	3%	-
Nephrectomy*	-	One Case
Pulmonary Infusion	3%	-
Acute Cholecystitis	13%	-

* During traction on the right kidney, the renal vein and the renal pedicle was injured and repair or autotransplantation of the injured kidney was not possible. The pathologic report of the injured kidney was chronic pyelonephritis.

Table VI. Pathologic results of 25 operated patients with Cushing's syndrome

Nodular Hyperplasia	Diffuse Hyperplasia	No of cases	Sex
69/4%	30/6%	17	Female
12/5%	87/5%	8	Male
52%	48%	25	Total

(Nelson's syndrome). These tumors are usually seen three to 10 years after surgical treatment. Over time hyperpigmentation and, if the adenoma becomes large enough, visual symptoms will be accompanied. Treatment of the tumor, when identified, is hypophysectomy.

In our series three cases of Nelson's syndrome ultimately developed.

DISCUSSION

Surgical management of adrenal disease varies and depends on the disease itself. Accurate preoperative diagnosis and localization of the lesion is important in planning the proper surgical approach of the lesion.

Owing to the diagnostic, localization, and surgical techniques that are now available, the result of treating Cushing's disease by bilateral adrenalectomy is good and acceptable as compared to the poor results and

efficacy of radiation and hypophysectomy in Iran.

The surgical outlook in patients with benign adenoma producing Cushing's syndrome should be excellent. The prognosis in patients with malignant adenocarcinoma producing Cushing's syndrome, nonfunctioning adrenal carcinomas, and extra-adrenal ACTH producing Cushing's syndrome are less favorable and depend primarily on the extent of the disease found at the surgery. The wide variety of adrenal disease requiring surgery continues to make this an exciting and ever-challenging field for the surgeon.

REFERENCES

- 1- Cushing H: The basophil adenomas of the pituitary body and their clinical manifestation (pituitary basophilism). *Bull Johns Hopkins Hosp* 1:137,1932.
- 2- Krieger DT: Physiopathology of Cushing's disease. *Endocrine Rev* 4:22, 1983.
- 3- Inura H, Matsukura S, et al: Studies on ectopic ACTH-producing tumors. II. Clinical and biochemical features of 30 cases. *Cancer* 35:1430, 1975.
- 4- Meador CK, Bowdoin B, et al: Primary adrenocortical nodular dysplasia: a rare cause of Cushing's syndrome. *J Clin Endocrinol* 27:1255, 1967.
- 5- Aschoff J: Circadian rhythms: general features and endocrinological aspects. In: Krieger DT (ed): *Endocrine Rhythms*. New York: Raven, 1974.
- 6- Asfeldt WH: Simplified dexamethasone suppression test. *Acta Endocrinol* 61: 219, 1969.
- 7- Bruke CW, Bearwell CG: Cushing's syndrome: an evaluation of the clinical usefulness of urinary free cortisol and other urinary steroid measurements in diagnosis. *QT Med* 42: 175, 1973.
- 8- Cuerin CK, Wahner HW, Gorman CA: Computed tomographic scanning versus radioisotope imaging in adrenocortical diagnosis. *AM J Med* 75:653, 1983.
- 9- Corrigan DF, Schaff M, Whaley RA: Selective venous sampling to differentiate ectopic ACTH secretion from pituitary Cushing's syndrome. *N Engl J Med* 296:861, 1977.
- 10- Linfoot JA: Heavy-ion alpha-particle therapy of pituitary tumors. In: Linfoot JA (ed): *Recent Advances in the Diagnosis and Treatment of Pituitary Tumors*. New York: Raven, 1975.
- 11- Salassa RM, Lauis ER, Carpenter PC: Transsphenoidal removal of pituitary adenoma in Cushing's disease. *Mayo Clin Proc* 53:24, 1978.
- 12- Stewart BH: *Operative Urology*. Baltimore: Williams and Wilkins, 1975.
- 13- Lutan JP, Mahjoudeau JA, Bouchard P: Treatment of Cushing's disease by O-P' -DDD. *N Engl J Med* 300:459, 1979.
- 14- Rhamy RK: Cushing's syndrome. In: Glenn JF (ed). *Urologic Surgery*. third edition, 1983.
- 15- Nelson DH, Sprunt JG: Pituitary tumors postadrenalectomy for Cushing's syndrome. *Proc Int Congr Endocrinol*, 1964.