

THE PROCESS OF TREATMENT OF PSYCHOFLEXED HAND WITH DYNAMIC SPLINT

MUHAMMAD-HADI NOURAI, M.D.

From the Orthopedic Department, Isfahan University of Medical Sciences, Isfahan, Islamic Republic of Iran.

ABSTRACT

This study presents the results of the treatment afforded to seven patients with the diagnosis of psychoflexed hands. These patients had referred for treatment during the years 1984 through 1989. On the average each patient received 3.5 years of follow-up. The average age for the group was 28 years. The group included one woman; the rest were male. Treatment procedure consisted of serial casting, passive manipulation, active exercises and dynamic splint. Psychotherapy was given throughout the treatment period. Psychiatric consultations were also sought.

Of this number, three had excellent results, two were graded as good and one as fair. The seventh case had to be excluded because the patient developed acute psychotherapeutic problems.

In contrast with other techniques that undertake the treatment of the flexion deformity of the hand without regard to psychic problems or those that undertake such treatment from psychological approaches only, both of which have had poor results, the technique used in this program seems to be a good plan of treatment for this illness because it is continuous, costs less and because the patient is constantly in touch with orthopedic specialists and with a psychiatrist.

MJIRI, Vol.5, No. 1,2, 39-42, 1991

INTRODUCTION

“Body and soul, of each other they're aware, they well respond, to each other's flare”

(Mowlavi)

Psychosomatic medical care is a branch of medicine which as a matter of fact, was known long before man became aware of the complexities of body and soul, as he knew that temperament, character and conduct, in other words, the psychic apparatus, is a reflection of bodily functions and actions and their qualitative and quantitative conditions. While the same psychic apparatus and behavioural traits, in turn, impress those bodily functions, and just as long lasting physical ailments may change psychic states, psychic illnesses,

too, can affect and even alter the physical limbs and organs.

In this study we present the discussion and investigation of a known and defined illness caused by the effects of psychic ailments on upper extremities and a new plan for its treatment by dynamic splint, together and in conjunction with psychiatric care and its long-term beneficial effects.

Psychoflexed hand is a medical condition which, in the absence of any organic defect in the brain, cerebral nuclei, spinal column and cord, peripheral nerves and finger joints, forces a gradual bending inward of fingers (mostly the 3rd, 4th and 5th fingers), and the metacarpophalangeal, the proximal interphalangeal and distal interphalangeal joints, resulting in the long run,

Psychoflexed Hand With Dynamic Splint

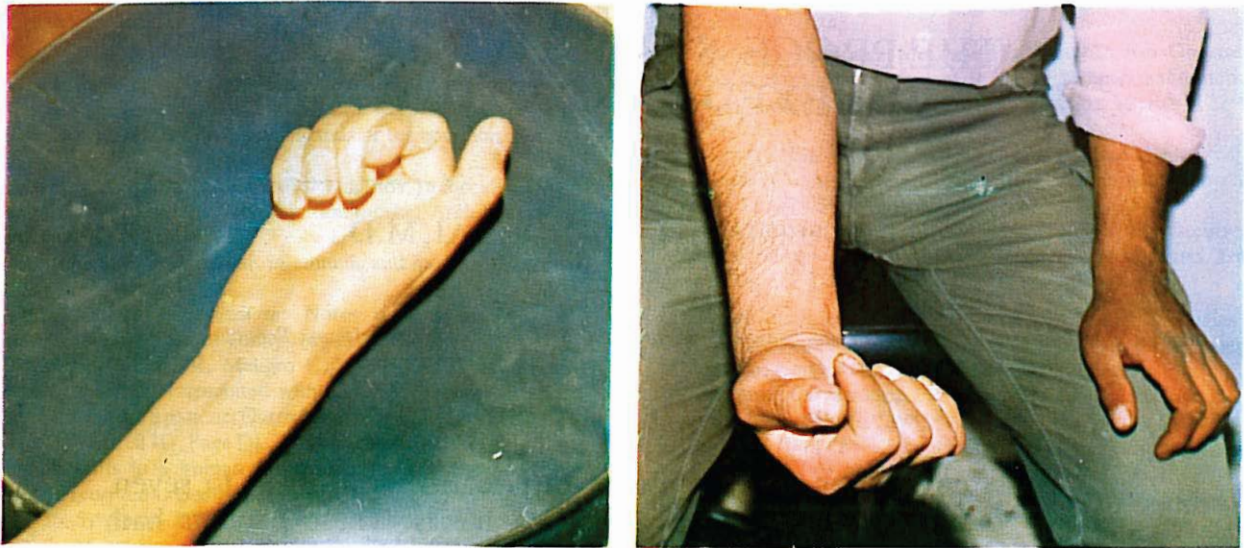


Fig. 1. A patient with psychoflexed hand, who is unable to actively extend his fingers.

in stiffening and contracture of the joints and in severe cases, drives the finger nails into the palm, causing injury, infection, and maceration.

MATERIAL AND METHODS

Seven patients have been studied for this survey between the years 1984-1989 in an orthopedic clinic. Their average age was 28, the average length of illness three years, follow-up period from one to six years, and average length of time $3\frac{1}{2}$ years. Of this group one was female, the other six were male.

The procedure begins with checking the patients for organic damage to the limbs, for Dupuytren's contracture, arthrogryposis multiplex congenita, peripheral nerve damage, and spastic hand due to stroke or cerebral palsy. After ruling out such afflictions and other organic diseases of the brain and spinal cord and ruling out neuropathies and myopathies, as testified to in psychiatric consultation and as indicated in the results of EEG, EMG, NCV, the patient would then be placed under treatment for a diagnosis of psychoflexed hand.

Throughout the whole period of therapy, orthopedic and psychiatric treatment is carried out and the patient is advised that his personal decision to get well is imperative (psychiatric specialists will be consulted respecting this point) and treatment would be initiated when we are confident of the patient's firm decision to get well. It is no use to start treatment without such assurance because the length of treatment would make the patient give it up as useless.

First, a series of splint fittings and casting for improvement of flexion contracture in the proximal

interphalangeal, distal interphalangeal and in the metacarpophalangeal joints were administered and then the dynamic splint was prepared and applied. At first the dynamic splint was used on a 24-hour basis, except for washing and bathing. However, when the patients could have active extension of the hand, the time was cut in half and the free time was spent in strengthening extensor muscles of the wrists and fingers which had grown weak during the illness period. And, when the power of the extensor muscles was on par with those of the contralateral limb, the patients were allowed to use the dynamic splints only during the nights. The splints were removed after three months.

RESULTS

Range of Motion

The range of motions in the MP, PIP and DIP finger joints were studied and noted in all the cases that were treated, none was adversely affected by the use of this technique.

Table I

Range of Motion (degrees)	BEFORE TREATMENT			LAST FOLLOW-UP			
	MP	PIP	DIP	MP	PIP	DIP	Result
Case No 1	20	0	0	80	70	30	Good
Case No 2	25	5	0	80	60	25	Good
Case No 3	20	10	5	90	85	20	Excellent
Case No 4	20	0	5	70	45	30	Fair
Case No 5	30	10	5	90	90	35	Excellent
Case No 6	20	10	5	90	90	40	Excellent
Case No 7	10	0	0	60	20	5	Poor
Mean	22.5	6	3.3	83	73	30	

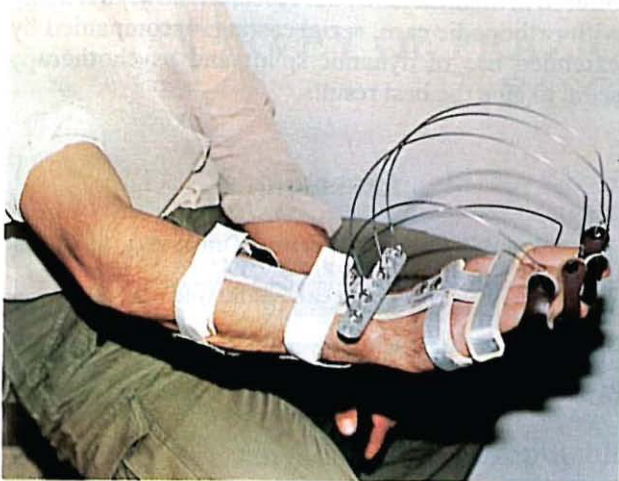


Fig. 2. Treatment with dynamic splint.

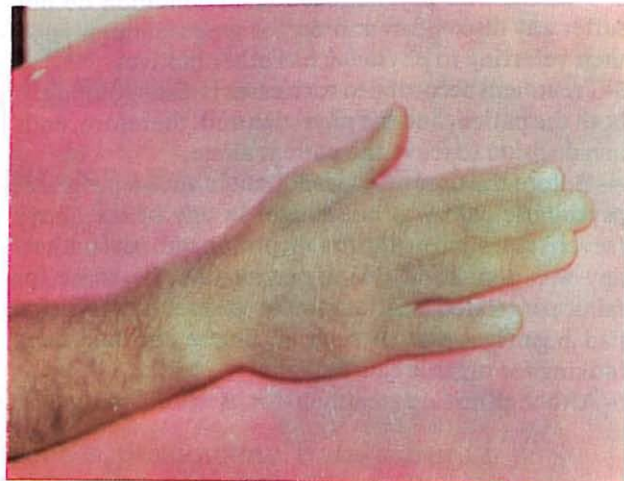


Fig. 3. The end result of treatment.

In one instance in which acute mental illness developed and because of this, treatment with dynamic splint was not possible, preliminary therapy was stopped. Even in this case motions in the last follow-up were not decreased; there was about 20 degrees of active range of motion in the PIP joint, 60 degrees in the MP joint and 5 degrees in the DIP joint (whereas before treatment there was only 10 degrees of motion in the MP joint and less than 5 degrees in each of the PIP and DIP joints (case 7 of the Table I).

In the other six cases, the range of motion in the PIP joint had an average of 6 degrees before, and 73 degrees after treatment in the MP and DIP joints. These figures were 22.5 and 3.5 degrees before and 83 and 30 degrees after treatment, respectively.

In general, the result was excellent in three cases, good in two, and fair in one case. One case is graded as poor because continuation of treatment was not possible.

Complications

There was one instance of skin injury on the back of a patient's hand. This was due to tightness of the dynamic splint causing excessive pressure by the brace. The injury was cured by routine treatment.

There were two cases in which the patients were embarrassed to use the dynamic splints, but with adequate explanation by the psychiatrist they ceased to worry and their treatment continued.

DISCUSSION

At least two types of damage accompanied by severe psychic depression and other mental disorders are mentioned:

1- The psychoflexed hand (reported by Frykman): in

this condition the 3rd, 4th and 5th fingers are bent or flexed inward with gradually increased contracture and maceration into the palm and thus become irreparable; sanitation of the hand becomes difficult and a foul odor emanates from the palm. Moreover, additional infection is caused by the penetration of the finger nails into the flesh of the palms.

The condition is the same in either hand, and should be distinguished from conditions such as Dupuytren's contracture and arthrogyrosis multiplex, for these conditions are easily distinguished by an experienced orthopedic surgeon.

A more severe psychoflexed condition termed "clenched fist syndrome" is reported by Vasile and Simmons.² In this condition, the entire hand becomes clenched, however with more emphasis on the three medial fingers.

2- The second type of damage results from a condition called psychoextended hand which is similar to psychoflexed except that the three medial fingers show a hyperextended condition of the proximal and distal interphalangeal joint(s) and a flexed condition of the metacarpophalangeal joint. Gradually, however, by stretch of the ligaments, the proximal interphalangeal joint moves in the direction of extension and hyperextension.

Patients with these afflictions do not care about their condition and do not seek treatment and cure. Sometimes they allow operation but the surgeon should know that surgical procedures from casting to amputation of the fingertips or fixation of the fingers with pins alone are not of much use, and that the patient's determination to get well and psychosomatic care can influence the treatment course. We conclude, that:

1- Psychoflex hand is a medical condition that is caused in the upper limbs by the effects of mental depression without prior brain or limb damage.

Psychoflexed Hand With Dynamic Splint

2- Patients with psychoflexed hand condition do not suffer any discomfort and do not seek treatment, and their referring to physician has other motives.

3- Treatment accorded to such cases is disappointing to both the patient and the physician and, therefore, ends in a decision to leave the patient alone.

4- Before the process of treatment in such a program, psychiatric care was not sought in any of the above (seven) cases and no thorough, prolonged, psychotherapy was done, and this appears to be the cause for failure of related treatments plus the fact the physician had been ignorant of such an illness and had been looking for organic causes.

5- Although no sure treatment for psychoflexed hand is

offered in medical texts, our research shows that along with orthopedic care, serial casting, accompanied by extended use of dynamic splint and psychotherapy seem to give the best results.

REFERENCES

- 1- Crenshaw AH: Campbell's Operative Orthopedics, 7th ed, Philadelphia: W.B. Saunders, P. 268-9, 1987.
- 2- Simmons BP, Vasile PG: The clenched fist syndrome. *J Hand Surg* 5:420, 1980
- 3- Spiegel D, Chase RA: The treatment of contracture of the hand using selfhypnosis. *J Hand Surg* 5:428, 1980.