



Evaluating the Efficacy of Orthoses in the Conservative Treatment of Thoracolumbar Fractures: A Systematic Review

Mohammad Taghi Karimi¹, Abolghasem Fallahzadeh Abarghuei^{2*} 

Received: 29 Aug 2023

Published: 3 Jun 2024

Abstract

Background: Thoracolumbar fractures are common traumatic injuries that can be treated conservatively or by surgery, depending on the type and severity of the injury. This study aimed to determine the efficiency of various orthoses used for these fractures based on the available literature.

Methods: Between 1950 and 2023, a search was conducted in some databases, including PubMed Central and MEDLINE, ISI Web of Knowledge, Cochrane-centered Register of Controlled Trial (CCTR), Embase, and Scopus. Some keywords—such as conservative treatment, orthoses, brace, and cast—were used in combination with thoracolumbar fracture, burst fracture, and compressive fracture. The quality of the studies was evaluated using the PEDro scale. Two researchers independently reviewed the studies.

Results: Based on the results of the included studies, orthosis is not necessary for stable burst and compression fractures. Based on the inclusion criteria, 20 papers were selected for the final analysis, 12 of which were on the use of spinal braces and casting (with quality between 1 and 6), 2 on the no-treatment approach, and 6 on comparing the outputs of treatment with spinal braces with no braces.

Conclusion: Although the use of orthosis and cast is one of the conservative treatments recommended for patients with thoracolumbar fractures, it seems that for stable burst fractures and compression fractures, the use of a brace does not provide any benefits. However, the use of a brace or cast is recommended for burst fractures with more than 1 column fracture.

Keywords: Thoracolumbar Fractures, Compression Fractures, Burst Fractures, Orthosis, Conservative Treatment

Conflicts of Interest: None declared

Funding: This systematic review was supported by Shiraz University of Medical Sciences.

*This work has been published under CC BY-NC-SA 1.0 license.

Copyright© Iran University of Medical Sciences

Cite this article as: Karimi MT, Fallahzadeh Abarghuei A. Evaluating the Efficacy of Orthoses in the Conservative Treatment of Thoracolumbar Fractures: A Systematic Review. *Med J Islam Repub Iran.* 2024 (3 Jun);38:62. <https://doi.org/10.47176/mjiri.38.62>

Introduction

Thoracolumbar fractures are common traumatic injuries classified as compression, burst flexion-dislocation, and fracture-dislocation injuries (1). It seems that every year, an estimated 8000 severe thoracic and lumbar spine fractures occur in Germany, with >2/3 occurring in the thoracolumbar junction (2, 3). This type of fracture may be due to trauma, mainly road traffic accidents and falling, or due to osteoporosis, mostly in the elderly. The treatment choice

depends on the type of injuries, the severity, and the age of the patients.

For traumatic thoracolumbar fractures, treatment includes rest, physical therapy exercise, brace, casting, and surgery (4-6). However, the main question posted here is which type of treatment approach is more appropriate for patients with thoracolumbar fractures. Nonoperative management of thoracolumbar fractures aimed to stabilize the

Corresponding author: Dr Abolghasem Fallahzadeh Abarghuei, fallahzadehm@sums.ac.ir

¹ Rehabilitation Sciences Research Center, Shiraz University of Medical Sciences, Shiraz, Iran

² Department of Occupational Therapy, School of Rehabilitation Sciences, Shiraz University of Medical Sciences, Shiraz, Iran

↑What is “already known” in this topic:

Conservative management of thoracolumbar fractures aims to stabilize the spine by limiting motion. It consists of bed rest, closed reduction, braces, and a body cast. Although braces and casting are recommended for thoracolumbar fractures, it is controversial which kind of fractures this strategy is more successful for.

→What this article adds:

The use of a brace does not benefit patients with stable burst fractures and compression fractures. However, a brace or cast is recommended for burst fractures with more than 1 column involvement.

spine by limiting motion and consists of bed rest, closed reduction, use of braces, and body cast (1, 7, 8). Although it has been mentioned that the choice of treatment approach is based on the amount of stability of the spine and associated neurological deficiency, it is still controversial whether the use of a conservative treatment approach is successful in the treatment of thoracolumbar fractures or not. The study of Bailey et al (7) on 96 patients with thoracolumbar fractures, showed that treating a neurologically intact thoracolumbar burst fracture with thoracolumbar sacral orthosis (TLSO) is equivalent to no TLSO at least 3 months after injury. Also, the results of a study by Stadhouders et al showed that for burst fracture, no difference was seen between the parameters (pain, disability, kyphosis, and height loss of vertebra) before and after the use of a brace (9). However, the study by Dai et al found that conservative treatment is a safe and effective method of treating burst fracture, even for some users with neurological deficits (6). Therefore, this systematic review aimed to determine the efficiency of various orthoses used for thoracolumbar fractures based on the available literature.

Methods

Search Strategy

A search was conducted in various databases, including PubMed Central and MEDLINE, ISI Web of Knowledge, Cochrane-centered Register of Controlled Trials (CCTR), Embase, and Scopus. Keywords such as thoracolumbar fractures, burst fractures, and compression fractures were used in combination with conservative treatment, orthoses, braces, and casts. The search was conducted between 1950 and 2023.

The 2 main criteria for selecting studies were population (only studies on thoracolumbar fractures were selected) and language (only studies reported in English were selected). The nature of the studies and the outcome variables were not considered in the selection of studies.

Type of Studies

Although the main focus of this study was on randomized clinical trials, due to the lack of such studies on this topic, other types of studies were also selected. Some low-evidence studies, such as abstracts, conference articles, editorial comments, and expert opinions, were excluded from the final list. Studies on traumatic thoracolumbar fractures were included in this study.

Participants

The studies focused on traumatic thoracolumbar fractures were selected in this study.

Interventions

This study selected studies on the use of conservative treatment, which includes bracing, casting, resting, and exercise. The studies focused on surgery or on comparing surgery and conservative treatment were excluded from the review.

Outcomes

The main outcome measures selected in this study include X-ray measures (Kyphotic angle, decrease in vertebral height, and distance between pedicles), time of hospitalization, and return to work. This review also selected the amount of neurological deficiency in the patients.

Secondary Outcomes

The need for surgery and other complications were selected as secondary outcomes.

Selection of the Studies

Based on the aforementioned criteria, 2 researchers independently reviewed the studies, mainly based on their titles and abstracts. If there was a disagreement between the 2 researchers, a third reviewer checked the results.

Data Extraction and Management

This review was done based on the PICO (population, intervention, comparison, and outcomes) style. This means that the data for each study was categorized into population, intervention, comparison, and outcomes.

Quality Assessment and Determination of the Risk of Bias

Based on the Pedro tool, the quality of the studies was checked (10, 11). It is a reliable tool to check the quality of studies. The trustworthiness and relevance of the published papers were determined based on this scale. The Pedro scale has a high degree of reliability in assessing the quality of various research studies. This scale comprises 11 items, including the inclusion criteria and source, random allocation, allocation concealment, baseline comparability, patient blinding, therapists blinding, assessment blinding, follow-up, intention to treat analysis, between-group comparison, and point estimate and variability.

Results

A total of 100 papers were found on this topic based on the mentioned keywords. However, 65 papers were selected based on the abstracts and titles. Twenty studies were chosen for final analysis based on the inclusion criteria, which restricted the research to papers on spine fractures resulting from traumatic injuries and the use of conservative treatment.

The PRISMA (Preferred Reporting Items for Systematic Reviews and Meta-Analyses) flow chart is presented in Figure 1.

There were 12 studies on the use of spinal braces and casting as 2 necessary conservative treatments used for patients with fractures in the thoracolumbar area (Table 1). The quality of the studies varied between 1 and 6 based on the Pedro scale (Table 2). There were only 2 studies on the output of treatment of spinal fractures based on no treatment approach, with a quality of 1. Also, 4 studies compared the outputs of treatment with spinal braces with no braces. The quality of this group of studies varied between 2 and 6. Comparison between the outputs of treatment ap-

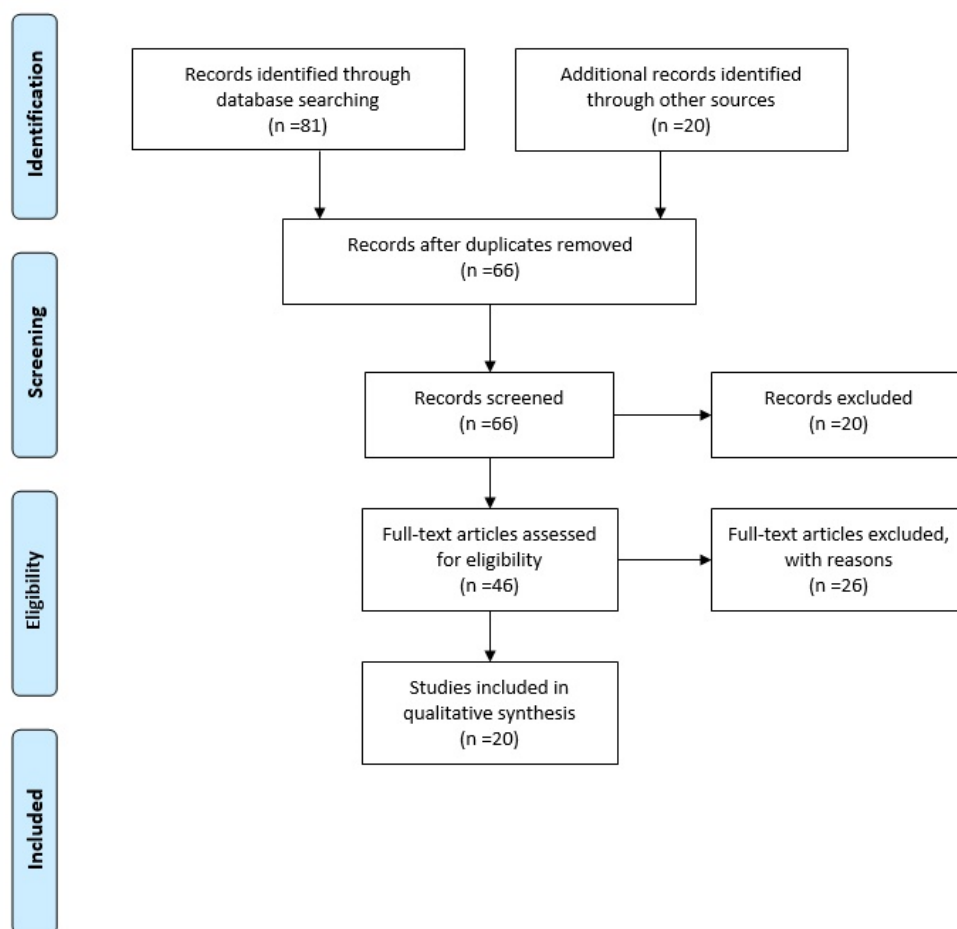


Figure 1. The flow diagram shows the selection process of studies in this systematic review

proaches based on the type of fractures was done in 2 studies. The quality of these studies was 3 and 4. The outputs of the selected studies confirmed the following points:

Neurological intact patients with stable thoracolumbar fractures had similar radiological and clinical outcomes at the 6-month follow-up (12).

Brace treatment with physical therapy is an excellent

treatment to be used for those with compressive fractures at the lumbar and thoracic spine (9).

Surgery is not required for burst fractures with intact posterior longitudinal ligament (PLL) (13).

Conservative treatment is a safe and effective method for burst fracture, even for those with neurological deficiency (6).

Table 1. Studies Done on the Fracture of Thoracolumbar

Authors	Type of Study	Methods	Results
Cankaya et al (4) 2015	Cross-sectional	Participants: 21 elderly subjects with thoracolumbar fractures Age> 60 Intervention: TLSO customized. The brace was used for a whole day for 3 months and then for half a day for another 3 months. Comparison: kyphotic angle, percentage of height loss, and Pain	The results showed an increase in the local kyphosis angle from 16 to 23 degrees and height loss from 19 to 32 % (At the 6-month follow-up). In the final follow-up, the average pain score was 1.62.
Shamji, et al (12) 2014	RCT	Participants: 33 patients with stable, single-level thoracolumbar burst fractures between T12 and L2 who are not neurologically deficient. Age:49-54 Intervention: No treatment (no brace) and with TLSO Comparison: Gait, disability, QOL, kyphotic progression and loss of vertebral height, hospital stay time Follow up: 6 months	The results showed that although there was no difference between the two groups in anterior loss of vertebral body height and kyphotic progression, the length of hospital stay was significantly shorter in the no-brace group compared to the brace group. Neurologically intact patients with stable thoracolumbar fractures treated with and without braces had the same radiographic and clinical outcomes at the 6 months follow-up.

Table 1. Continued

Authors	Type of Study	Methods	Results
Stadhouders, et al (9) 2009	RCT	Participants: 133 patients with thoracolumbar fractures (108 in the compression group and 25 in the burst group without neurological damage with less than 50% loss of height of the anterior column and with less than 30% reduction in the spinal cord. level of lesion: T4-T11 Primary outcome measures are pain, disability, kyphosis, and height loss of the vertebra. Intervention: Compression group received: 1) physical therapy + postural instruction 2) plaster cast for 6,12 weeks 3) brace for 6weeks Burst fracture group: Brace or plaster cast for 12 weeks	For the compression fracture group, physical therapy and a brace were considered tolerable. Pain and disability decreased more with bracing. No difference in the effect of treatment on residual deformity. For burst fracture: no difference was seen between the abovementioned parameters before and after using a brace. Using a brace and performing supplementary physical therapy is a suitable treatment option for compressive fracture of the lumbar and thoracic spine.
Bailey, et al (14) 2009	RCT	Participants: 47 patients with burst fractures (between T11 and L3). Age: <60 with no neurological deficit Intervention: Group 1: no treatment, Group 2: TLSO brace Outcome: disability, pain, functional outcome, QOL and Complications	Based on the study results, no difference was observed between the groups for any of the outcome measures. Therefore, a thoracolumbar burst fracture in exclusion of a posterior ligaments complex injury is probably stable and does not require a brace.
Tropiano, et al (15) 2003	Retrospective review	Participants: 45 patients with thoracolumbar and lumbar burst fracture Intervention: closed reduction and casting Comparison: pain, employment status, neurological function, vertebral kyphosis, anterior body compression	The results showed that 64% of the patients had minimal or no pain. The significant correction of vertebral wedging from 18 to 5 degrees was from Closed reduction results. Closed reduction and casting of thoracolumbar and lumbar bursts is a sure approach that leads to acceptable functional and radiographic outcomes.
Weinstein, et al (16) 1987	Retrospective study	Participants: 83 patients with fracture Average time from injury to follow-up: 20.2 years Average time on follow up: 43 months Most common site: T12-L2 Comparison: pain, kyphosis	Pain score of follow-up: 3.5 No decreases in neurological status at follow-up. Kyphotic angle: 26.4 degrees at flexion and 16.8 degrees at extension.
Dai, et al (6) 2008	Retrospective study	Participants: 127 patients without thoracolumbar burst fracture (Denis type B) Follow up: 7.2 years Age: 37 Intervention: conservative treatment Comparison: loss of kyphosis correction (LKC) and pain	Most patients reported acceptable results regarding pain and work. Conservative treatment is a safe and effective method of treatment for burst fractures, even for some users with neurological deficits.
Alimohammadi, et al (17) 2020	Retrospective study	Participants: 67 patients with single-level acute thoracolumbar burst fracture level of lesion: T3-L2 Age: 18-65 Intervention: TLSO Comparison: Pain, vertebral body compression rate (VBCR), percentage of anterior height compression, Cobb angle, interpedicular distance, and canal compromise	For 23.6% of the subjects, non-operative treatment failed and required surgery. After 42 months of follow-up, functional outcome was satisfactory in 91.65% of the subjects. Despite the decrease in anterior vertebral body compression, the change did not significantly.
Bailey, et al (7) 2014	RCT	Participants: Those with burst fracture between T10 and L3 (96 subjects). Kyphotic angle lower than 35° Neurological intact (16-60 years) Age: 40 Intervention: brace or no brace + brace used for 10 weeks. 47 patients used TLSO, and 49 had no orthosis outcome: pain, satisfaction, and kyphosis	The results of this study showed that three months after the injury, treating a neurologically intact thoracolumbar burst fracture with TLSO is similar to no TLSO. There was no difference in QOL, satisfaction, or length of stay between both groups.

There is no difference between quality of life and length of hospital stay in treatment with and without a brace (7).

Compression fracture with a kyphotic angle of <30° can be treated conservatively (13).

The probability of failure of conservative treatment is higher in people with greater interpedicular distance (9).

Discussion

The results of this study showed that orthosis is not nec-

essary for some thoracolumbar fractures (stable burst fracture and compression fracture), but it is suggested for some fractures, such as burst fractures with more than 1 column involvement.

In this study, a total of 20 studies were finally selected on this topic, with quality varied between 1 and 6. The most conservative treatment mentioned in these studies includes no treatment, use of TLSO braces, and casting. The main reasons for the low quality of these studies were the limited

Table 1. Continued

Authors	Type of Study	Method	Results
Celebi, et al (18) 2004	Retrospective study	Participant: 26 patients with single-level thoracolumbar fracture without posterior column involvement Age: 36 years Intervention: hyperextension orthosis for 16-24 weeks Comparison: pain, work scale, kyphosis angle, and residual canal stenosis	Functional results were excellent or good in 65.3% and poor in 7.7%. There was a significant increase in Cobb angle after follow-up. Although conservative treatment of thoracolumbar fracture has considerable efficiency, it may have poor results in a small percentage of patients. Some of the patients may require surgery due to pain.
Ağuş, et al (19) 2005	Cross-sectional	Participant: 29 neurological intact patients with 2 or 3-column injuries thoracolumbar burst fractures. Divided into those with one-column and 2-column fractures Intervention: conservative treatment Comparison: local kyphosis angle, anterior and posterior height, and encroachment	The vertebral column deformity after injury was stable in G1, while it was progressive in G2. It seems that nonoperative treatment could be an alternative method for neurologically intact 2 and 3-column injured Denis type A, B, and C thoracolumbar burst fracture.
Tezer, et al (13) 2005	Retrospective review	Participants: 48 patients with thoracolumbar fractures Follow-up: 66 months 32 with compression type fracture and 16 with burst type fracture with no neurological deficit Age: 18-62 Intervention: 29 with orthosis, 13 by body cast, and 6 by bed rest. Comparison: pain, kyphosis angle, and functional score	In patients with wedge fractures, there were significant changes in scoliosis and wedging index. In patients with burst fractures, the vertebral index, wedge index, and height index increased after treatment. Compression fractures with kyphosis angles less than 30 are stable and can be treated conservatively. For burst fracture, conservative treatment should be used if no neurological deficit and the ligaments are intact.
Alanay, et al (20) 2004	Prospective study	Participant: 15 patients with intact neurologically burst fracture (T11-L2) Age: 28 Intervention: 3 months body cast Comparison: local kyphosis angle, sagittal index, percentage of compression of anterior body height, function and pain	PLL integrity is not a key to preventing loss of correction gained by non-surgical management of burst fracture. The magnitude of residual deformity usually remained constant. Patient satisfaction seems to be high.
Öztürk, et al (21) 2012	Retrospective study	Participant: 26 patients with burst fracture between T11-L2 (without any neurological problem). Age: 46.03 years Intervention: customized TLSO Comparison: Denis pain, functional scales, local kyphosis, angle, sagittal index, and height loss percentage Mean follow-up: 41.3	The results showed an increase in the local kyphosis angle, sagittal index, and height loss percentage values at follow-up. Also, the average period of returning to work is 3.64 months. The conservative treatment of stable thoracolumbar burst fracture is widely accepted.
Chow, et al (22) 1996	Retrospective study	Participant: 26 patients with unstable burst fractures in the thoracolumbar region (T11-L2) Follow-up: 24 months Intervention: hyperextension cast or brace Outcome: Pain, ability to work, ability to perform recreational activities, and overall satisfaction Mean follow-up: 34.3 months	79% of the patients had no pain, and 78% of them returned to work. Non-operative treatment of thoracolumbar burst fracture with hyperextension casting or bracing was proven to be a safe and effective method of treatment. It seems that ligament injury of the posterior column is not a contraindication for non-operative management of burst fracture.
Cantor, et al (8) 1993	Cross-sectional	Participant: 18 neurologically intact patients with burst fracture Intervention: total contact orthosis Follow-up average: 19 months Comparison: pain and kyphosis	Mean kyphosis was 19 at the time of injury and 20 at follow-up. In the care with PLL and thoracolumbar burst fracture, early mobilization in total contact TLSO leads to acceptable functional outcomes.
Shen (23) 1999	Retrospective review	Participant: 38 patients with single-level burst fractures between T11-L2 Age: 37 years Follow up: 4.1 years Intervention: 9 with Jewett brace and no treatment for remainders Comparison: pain	The initial kyphosis angle was 20 degrees at the initial and 24 at follow-up. The presence of vertical lamina fracture and spinous process fractures are not contra-indication for conservative treatment. Although braces and activity restrictions can be necessary for pain control, they may not change long-term outcomes.

number of patients, the low follow-up period, and no attempt to blind the patients and researchers regarding the type of interventions used. However, it should be emphasized that in most of the available studies, the efficiency of

the treatment approach was determined based on radiological assessments—such as kyphosis angle, anterior and posterior height, and the Cobb angle.

There were 11 studies on the efficiency of bracing and casting on the output of treatment of spinal fractures. In the

Table 1. Continued

Authors	Type of Study	Method	Results
Stadhouder, et al (9) 2009	Prospective RCT	Participant: 67 patients with single-level acute traumatic thoracolumbar burst fracture Age: 18-66 Intervention: TLSO Comparison: vertebral body compression rate (VBCR), percentage of anterior height compression (PAHC), Cobb angle, Interpedicular distance (IPD), and Canal compromise	Nearly 23.6% of the subjects failed non-operative treatment and had to receive surgery. Older patients and those with greater interpedicular distance are at a greater risk for failure of conservative treatment.
Tonbul, et al (24) 2008	Retrospective study	Participant: 43 patients with thoracolumbar compression fractures Age: 39 years Intervention: body cast for 2 months and then TLSO for 4 months Comparison: kyphotic angle, pain, functional scales, sagittal index Mean follow-up: 7.5 years	For kyphotic angles less than 30 degrees, compression fractures can be treated conservatively. Casting does not influence the radiographic parameters in the long term.
Page, et al (25) 2022	retrospective study	Participant: 112 patients with thoracolumbar burst fractures from T11 to L2. 61 patients with A3 fractures and 51 with A4 fractures Age: 54.5 and 61.4 years Follow up: 1 year Intervention: lumbar orthosis Comparison: Upright radiographs	The results of a 1-year follow-up showed that the average change in Cobb's angle in A3 fractures and A4 fractures was 4.1 and 6.1 (p = 0.021). Also, the kyphotic and Gardner angles in A4 fractures significantly worsened in the same period (p = 0.05 and p = 0.026, respectively).

Table 2. Results of Quality Assessment Based on the Pedro Scale

References	Eligibility criteria	Random allocation	Hidden allocation	initial similarity between the groups	Blind individuals	Blind therapists	Blind evaluators	Outcome measures in 85% of the samples	Analysis of intention to treat	Comparison between groups	Effect size	Score
(4)	Yes	No	No	Yes	No	No	No	Yes	No	No	No	2/10
(12)	Yes	Yes	No	Yes	No	No	Yes	Yes	No	Yes	No	5/10
(9)	Yes	Yes	No	Yes	No	No	No	Yes	No	Yes	No	4/10
(14)	Yes	Yes	Yes	Yes	No	No	Yes	Yes	No	Yes	No	6/10
(15)	Yes	No	No	Yes	No	No	No	Yes	No	No	No	2/10
(6)	Yes	No	No	Yes	No	No	No	No	No	No	No	1/10
(17)	Yes	No	No	Yes	No	No	No	No	No	No	No	1/10
(7)	Yes	Yes	Yes	Yes	No	No	Yes	Yes	No	Yes	No	6/10
(26)	Yes	No	No	Yes	No	No	No	Yes	No	No	No	2/10
(13)	Yes	No	No	Yes	No	No	No	Yes	No	Yes	No	3/10
(18)	Yes	No	No	Yes	No	No	No	Yes	No	No	No	2/10
(19)	Yes	No	No	Yes	No	No	No	Yes	No	Yes	No	3/10
(20)	Yes	No	No	Yes	No	No	No	Yes	No	No	No	2/10
(21)	Yes	No	No	Yes	No	No	No	Yes	No	No	No	2/10
(22)	Yes	No	No	Yes	No	No	No	Yes	No	No	No	2/10
(8)	Yes	No	No	Yes	No	No	No	Yes	No	No	No	2/10
(23)	Yes	No	No	Yes	No	No	No	Yes	No	No	No	2/10
(9)	Yes	Yes	No	Yes	No	No	No	Yes	No	Yes	No	4/10
(24)	Yes	No	No	Yes	No	No	No	Yes	No	No	No	2/10
(25)	Yes	No	No	Yes	No	No	No	Yes	No	Yes	No	3/10

research by Cancaya et al, the effect of custom-made TLSO was evaluated on 21 elderly patients (4). Their study showed that the mean local kyphosis angle increased from 19% to 32% in those with burst fractures. In another study done by Tropiano et al, it was determined that 64% of the patients treated with casting had minimal or no pain (15). Moreover, their vertebral wedging decreased from 15° to 5°. In contrast, 23.6% of the patients in the research done by Alimohammad et al received surgery due to failure in the use of TLSO (17). They also showed that although the anterior body compression rate was reduced, the reduction was not significant. Celebi et al showed that although conservative treatment may have considerable efficiency, it may have poor results in a small percentage of the patients

(18), patients with single-level thoracolumbar fracture participated in this study). In the studies above, the type of fracture was burst fracture with only 1 column injury. In the research done by Haluk et al, patients with 2- or 3-column injured thoracolumbar burst fractures were selected (19). They showed that vertebral column deformity after injury was stable in those with burst fracture with 1 column, while it progressed in those with 2-column injury. Based on their research, conservative treatment could be used as an alternative method for neurologically intact with 2- or 3-column injuries.

In the research done by Alanay et al, it was mentioned that PLL integrity is not a key factor for nonsurgical treatment of burst fractures. The output of treatment with a body

cast was satisfactory, and the amount of deformity remained constant. The use of customized TLSO was also evaluated for the patients with burst fractures. Although TLSO did not influence kyphotic angle or height loss values, it can be used for stable burst fractures. The output of the research by Chow et al also supports the point that the integrity of PLL is not a key factor in the use of conservative treatment in burst fractures (22).

The suitability of a body cast for compressive fracture was evaluated by Tanbul et al. They showed that a body cast is a promising approach for compressive fractures with a kyphotic angle of less than 30° . However, it does not influence radiographic parameters (24). Based on the available studies, a brace and cast are recommended for compression fractures of the thoracolumbar. However, it should not be used for kyphotic angles $<30^\circ$. The brace does not influence the kyphotic angle or anterior height loss of the vertebra.

Regarding burst fractures, some studies confirmed that the success of bracing and casting depends on the integrity of the PLL. However, based on available evidence, the integrity of the PLL is not a key factor in selecting the treatment approach (20, 26). It can be concluded that the use of conservative treatment for burst fracture depends on the stability of the spinal column. Braces and casts seem to be used for stable burst fracture (only 1 column is involved). It should also be emphasized that brace use does not influence kyphotic angle and anterior height loss of vertebra.

The second question posed here is whether the type of fractures influences the output of treatment with bracing. There were 2 studies that specifically compared the output of treatment with conservative treatment in various types of fractures. The quality of these studies was 3 and 4.

In the research done by Standhouder et al, 133 patients with thoracolumbar fractures with compressive and burst fractures participated (9). The patients received plaster cast, physical therapy, and bracing in the compressive fracture group and a brace or cast in the burst fracture group. The outputs of this study showed that pain and disability decreased in the compressive fracture group, but this approach did not influence the residual deformity. In constant, there was no difference between the pain score, residual deformity, and disability in the burst group (9). It was concluded that a brace, cast, and physical therapy are good treatment choices for compressive fractures of the lumbar and thoracic spine. In another study by Mehmatt et al, the patients with burst and compressive fractures were followed for 77 months. They showed that the use of orthoses influenced scoliosis and wedging index in the compressive group; however, in patients with burst fractures, wedge index, and height increased after the follow-up (13). Based on the results of this study, compression fractures with a kyphotic angle of $<30^\circ$ are stable and can be treated conservatively. Burst fractures with no neurological deficiency and intact ligaments can be treated with orthoses.

Based on the above-mentioned studies, conservative treatment can be used for those with compressive fractures, especially for those with a kyphotic angle $<30^\circ$. It seems that the use of a brace does not influence the outcomes of

treatment of burst fractures. It should be stressed that neither the kyphotic angle nor the anterior height of the vertebra was controlled by the use of a brace.

The next question that should be answered in this review is the difference between no treatment and the use of a brace. Four studies compared the outputs of treatment with and without the use of casts and bracing. The quality of these studies varied between 2 and 6.

In the research done by Shamji et al, the outputs of treatment based on the kyphotic angle, anterior loss of vertebral height, and time of hospitalization were compared in 2 groups of patients with fractures between T12 and L2 treated with and without a brace (12). This study showed that the time of hospitalization was less in the nontreatment group. Moreover, there was no difference between the kyphotic angle or the loss of anterior vertebral height between groups. In another study done by Bailey et al, on stable burst fracture (fractures between T11 and L3 with intact ligaments), no difference was found in disability, pain, functional outcome, and quality of life (QOL) in those treated with and without a brace (14). Bailey et al also showed that for those with stable burst fracture between T10 and L3, the outputs of treatment on the kyphotic angle, QOL, length of hospital stay, and satisfaction were the same (7). Shen was the other researcher who evaluated the output of the use of the Jewett brace and no brace on burst fractures between T11-L2 (23). They showed that the long-term result of pain control was the same for both groups. According to the mentioned studies, it can be concluded that the results of treatment with and without a brace on pain were the same.

It seems that the use of a brace did not influence the kyphotic angle, QOL, anterior height loss, and pain in those with stable fractures. A comparison was made for stable fractures. Based on the above-mentioned studies, it can be concluded that for stable fractures (both compression and burst fractures), the results of treatment with and without orthoses are the same. However, the use of braces or casts is recommended for burst fractures involving more than 1 column. Moreover, for both compression and burst fractures, the use of orthoses or casts does not influence the kyphotic angle, anterior height loss of vertebra, QOL, or pain.

The main clinical finding of this study for clinicians can be summarized as follows:

1. For compression stable fracture, the use of a brace neither influences pain nor the QOL.
2. For stable burst fractures, the use of a brace is not critical.
3. For burst fractures involving more than 1 column, the use of a brace is recommended.
4. For reduction of kyphosis angle and loss of anterior height of vertebra, the use of a brace is not recommended.

Clinicians can use the results of this study to treat thoracolumbar spine fractures based on a scientific approach. It seems that braces are unnecessary for stable wedge fractures. Prescription of spinal braces based on the results of this review would decrease the cost of treatment.

Limitations of the Study and Suggestions for Future Research

The main limitation associated with this systematic review was the lack of enough randomized controlled trial (RCT) studies. Moreover, the quality of available studies was low. Some of the studies had relatively short follow-up periods. Therefore, it is recommended that in future studies, RCT studies be done with more patients and longer follow-up periods.

Conclusion

Orthoses and casts are among the conservative treatments recommended for patients with thoracolumbar fractures. It seems that a brace does not benefit stable burst fractures and compression fractures. However, a brace or cast is recommended for burst fractures with more than 1 column involvement (for patients with no neurological problems). It should be noted that the use of a brace does not influence the kyphotic angle, anterior body height loss, pain, and QOL.

Authors' Contributions

M.T.K. and A.F.A. researched the literature and conceived the study. A.F.A. was involved in conception, design, and data collection. M.T.K. performed the analysis and interpretation and wrote the first draft. Both authors reviewed and edited the manuscript and approved the final version.

Ethical Considerations

This study was approved by the Ethics Committee of Shiraz University of Medical Sciences (SUMS). The ethics code: IR.SUMS.REC.1400.353.

Acknowledgment

The authors thank Shiraz University of Medical Sciences for supporting this paper.

Conflict of Interests

The authors declare that they have no competing interests.

References

- Bakhsheshian J, Dahdaleh NS, Fakurnejad S, Scheer JK, Smith ZA. Evidence-based management of traumatic thoracolumbar burst fractures: a systematic review of nonoperative management. *Neurosurg Focus*. 2014;37(1):E1.
- Spiegel UJ, Fischer K, Schmidt J, Schnoor J, Delank S, Josten C, et al. The Conservative Treatment of Traumatic Thoracolumbar Vertebral Fractures. *Dtsch Arztebl Int*. 2018;115(42):697-704.
- Bühren V. [Injuries to the thoracic and lumbar spine]. *Unfallchirurg*. 2003;106(1):55-68; quiz -9.
- Cankaya D, Yilmaz S, Deveci A, Dundar A, Yoldas B, Toprak A, et al. Clinical and radiological outcomes of conservative treatment after stable post-traumatic thoracolumbar fractures in elderly: Is it really best option for all elderly patients? *Ann Med Surg (Lond)*. 2015;4(4):346-50.
- Verheyden AP, Spiegel UJ, Ekkerlein H, Gercek E, Hauck S, Josten C, et al. Treatment of Fractures of the Thoracolumbar Spine: Recommendations of the Spine Section of the German Society for Orthopaedics and Trauma (DGOU). *Global Spine J*. 2018;8(2 Suppl):34S-45S.
- Dai LY, Jiang LS, Jiang SD. Conservative treatment of thoracolumbar burst fractures: a long-term follow-up results with special reference to the load sharing classification. *Spine (Phila Pa 1976)*. 2008;33(23):2536-44.
- Bailey CS, Urquhart JC, Dvorak MF, Nadeau M, Boyd MC, Thomas KC, et al. Orthosis versus no orthosis for the treatment of thoracolumbar burst fractures without neurologic injury: a multicenter prospective randomized equivalence trial. *Spine J*. 2014;14(11):2557-64.
- Cantor JB, Lebowitz NH, Garvey T, Eismont FJ. Nonoperative management of stable thoracolumbar burst fractures with early ambulation and bracing. *Spine*. 1993;18(8):971-6.
- Stadhouders A, Buskens E, Vergroesen DA, Fidler MW, de Nies F, Oner FC. Nonoperative treatment of thoracic and lumbar spine fractures: a prospective randomized study of different treatment options. *J Orthop Trauma*. 2009;23(8):588-94.
- de Morton NA. The PEDro scale is a valid measure of the methodological quality of clinical trials: a demographic study. *Aust J Physiother*. 2009;55(2):129-33.
- Matos AP, Pegorari MS. How to Classify Clinical Trials Using the PEDro Scale? *J Lasers Med Sci*. 2020;11(1):1-2.
- Shamji MF, Roffey DM, Young DK, Reindl R, Wai EK. A pilot evaluation of the role of bracing in stable thoracolumbar burst fractures without neurological deficit. *J Spinal Disord Tech*. 2014;27(7):370-5.
- Tezer M, Erturer RE, Ozturk C, Ozturk I, Kuzgun U. Conservative treatment of fractures of the thoracolumbar spine. *Int Orthop*. 2005;29(2):78-82.
- Bailey CS, Dvorak MF, Thomas KC, Boyd MC, Paquett S, Kwon BK, et al. Comparison of thoracolumbosacral orthosis and no orthosis for the treatment of thoracolumbar burst fractures: interim analysis of a multicenter randomized clinical equivalence trial. *J Neurosurg Spine*. 2009;11(3):295-303.
- Tropiano P, Huang RC, Louis CA, Poitout DG, Louis RP. Functional and Radiographic Outcome of Thoracolumbar and Lumbar Burst Fractures Managed by Closed Orthopaedic Reduction and Casting. *Spine*. 2003;28(21):2459-65.
- Weinstein JN, Collalto P, Lehmann TR. Long-term follow-up of nonoperatively treated thoracolumbar spine fractures. *J Orthop Trauma*. 1987;1(2):152-9.
- Alimohammadi E, Bagheri SR, Ahadi P, Cheshmehkaboodi S, Hadidi H, Maleki S, et al. Predictors of the failure of conservative treatment in patients with a thoracolumbar burst fracture. *J Orthop Surg Res*. 2020;15(1):514.
- Celebi L, Muratli HH, Doğan O, Yağmurlu MF, Aktekin CN, Biçimoğlu A. [The efficacy of non-operative treatment of burst fractures of the thoracolumbar vertebrae]. *Acta Orthop Traumatol Turc*. 2004;38(1):16-22.
- Ağuş H, Kayali C, Arslantaş M. Nonoperative treatment of burst-type thoracolumbar vertebra fractures: clinical and radiological results of 29 patients. *Eur Spine J*. 2005;14(6):536-40.
- Alanay A, Yazici M, Acaroglu E, Turhan E, Cila A, Surat A. Course of nonsurgical management of burst fractures with intact posterior ligamentous complex: an MRI study. *Spine (Phila Pa 1976)*. 2004;29(21):2425-31.
- Öztürk I, Ertürer E, Sönmez MM, Sarı S, Şeker A, Seçkin MF. Early mobilization with customized TLSO brace in thoracolumbar burst fractures. *Acta Orthop Traumatol Turc*. 2012;46(5):373-8.
- Chow GH, Nelson BJ, Gebhard JS, Brugman JL, Brown CW, Donaldson DH. Functional Outcome of Thoracolumbar Burst Fractures Managed With Hyperextension Casting or Bracing and Early Mobilization. *Spine*. 1996;21(18):2170-5.
- Shen WJ, Shen YS. Nonsurgical treatment of three-column thoracolumbar junction burst fractures without neurologic deficit. *Spine (Phila Pa 1976)*. 1999;24(4):412-5.
- Tonbul M, Yilmaz MR, Ozbaydar MU, Adaş M, Altan E. [Long-term results of conservative treatment for thoracolumbar compression fractures]. *Acta Orthop Traumatol Turc*. 2008;42(2):80-3.
- Page PS, Parmar VK, Bond E, Josiah DT. Radiographic Outcomes of Thoracolumbar AOSpine A3 and A4 Fractures Treated With External Bracing. *Cureus*. 2022;14(2):e22490.
- Aligizakis A, Katonis P, Stergiopoulos K, Galanakis I, Karabekios S, Hadjipavlou A. Functional outcome of burst fractures of the thoracolumbar spine managed non-operatively, with early ambulation, evaluated using the load sharing classification. *Acta Orthop Belg*. 2002;68(3):279-87.