

## COMPARISON OF UROLOGICAL COMPLICATIONS OF BARRY'S AND MODIFIED LICHT'S TECHNIQUES OF EXTRAVESICAL URETERONEOCYSTOSTOMY IN RENAL TRANSPLANT PATIENTS IN URUMIEH

A. TAGHIZADEH AFSHARI, M.D., AND M.R. MOHAMMADI-  
FALLAH, M.D.

*From the Department of Kidney Transplantation, Taleghani Hospital, Urumieh University of Medical  
Sciences, Urumieh, Islamic Republic of Iran.*

### ABSTRACT

Between April 5, 1988 and Sept. 3, 1992, 204 cases of kidney transplantation were performed using modified Licht's implantation technique and from Sept. 4, 1992 to Sept. 3, 1993, 57 cases were done with Barry's method. Age ranged from 11 to 60 years and in both groups had nearly similar distribution. Kidneys were provided from live donors. Immunosuppressive therapy was similar in all patients and included cyclosporin A, azathioprine and corticosteroids.<sup>1-3</sup>

After transplantation, all patients were followed and meticulous attention was paid to determining the occurrence of possible urologic complications. Sonography, I.V.U. and/or radioisotope scanning was performed as indicated. In this study, 15 patients (7%) in the Licht group and one patient (2%) in the Barry group developed urological complications.

*MJIRI, Vol. 12, No. 2, 105-108, 1998.*

**Keywords:** Kidney transplantation, complications, ureteral reimplantation.

### INTRODUCTION

Urological complications represent a significant cause of morbidity associated with renal transplantation.<sup>3</sup> Most recent series report an incidence of urological complications of less than 10%.<sup>3</sup> The majority of these complications are associated with ureteroneocystostomy performed during transplantation. Therefore, controversy remains as to the most appropriate method of ureteroneocystostomy in renal transplantation.

Many medical centers advocate the use of the transvesical technique of ureteral reimplantation while other centers have used an extravascular approach with good results.

We report our experience comparing the modified Licht extravascular ureteroneocystostomy and the unstented

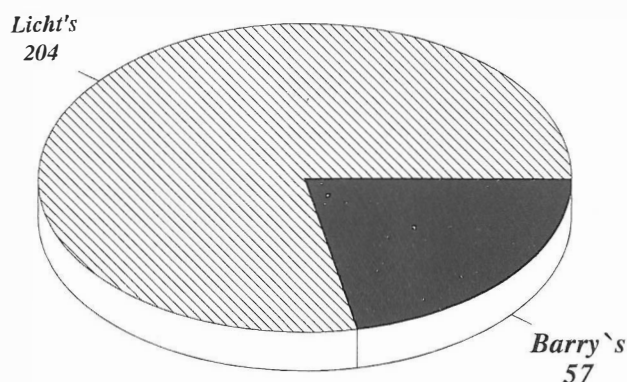


Fig. 1. The study groups.

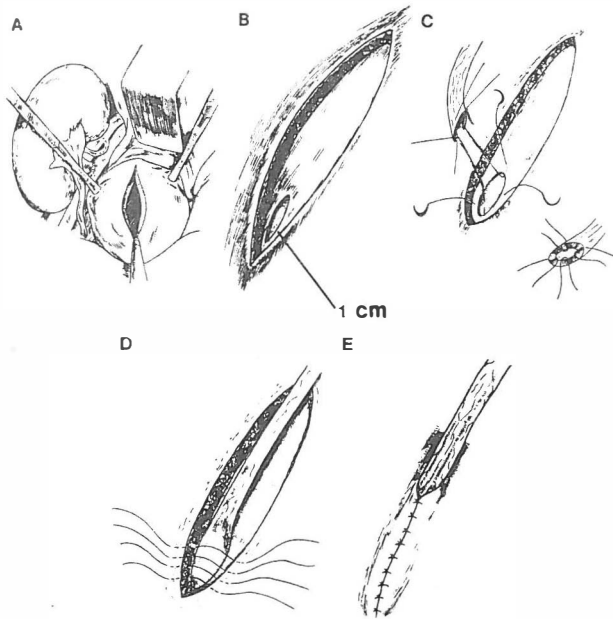


Fig. 2. The modified Licht technique.

parallel incision extravesical ureteroneocystostomy technique in 261 consecutive renal transplants.

**MATERIALS AND METHODS**

Renal transplantation has been performed in Taleghani Medical Center of Urumieh Medical School since May, 1988. Between May 1988 and October 1992, 261 cases of renal transplantation have been performed in this center (Fig. 1). Age span was 11 to 60 years. Donor nephrectomy was done via flank approach<sup>2,4</sup> and the kidney was cooled and irrigated with 500 mL Ringer solution at 4°C containing 10000 units of heparin, 10 mL of 1% lidocaine and 1 mL bicarbonate.<sup>3,4</sup> Most of the renal implantations were done in the right iliac fossa with end to end internal iliac arterial anastomosis. After arterial anastomosis of the graft and removal of the vascular clamps and being certain of ureteral urinary flow of the transplanted kidney, the ureter was prepared for implantation. We do not use a ureteral stent for ureteral implantation.

For comparison of urologic complications, implantation was done by two methods, namely modified Licht and Barry techniques.

**Modified Licht technique<sup>5-7</sup>**

A 3-cm incision is made on the posterolateral aspect of the bladder. The perivesical fat, adventitia and muscle of the bladder wall are incised to expose the mucosa over the entire length of the incision. The edges of the bladder muscle are undermined by pushing the mucosa away from

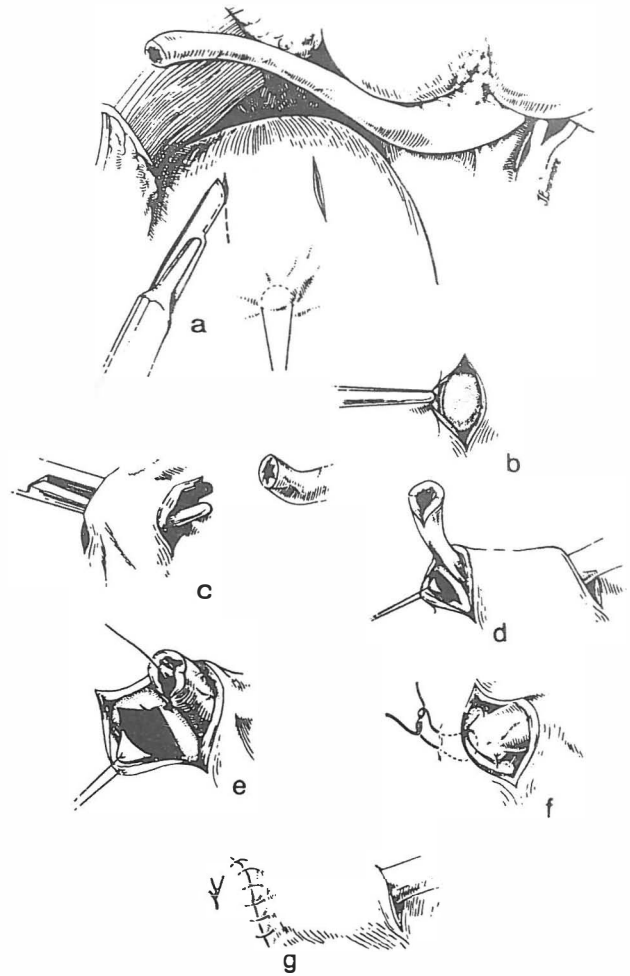


Fig. 3. The external tunnel method (Barry).

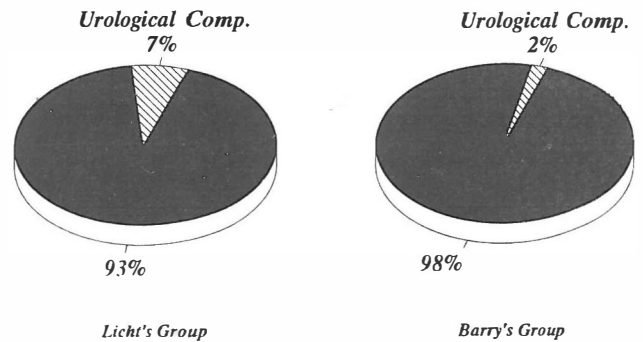


Fig. 4. Complication rates of both groups.

the muscle. The distal end of the allograft ureter is spatulated over a short distance. A small opening (0.5 cm) is made in the bladder mucosa at the distal end of the incision and a mucosa-to-mucosa anastomosis is made between the ureter and the bladder using interrupted or continuous 4-0 chromic catgut sutures. At the distal aspect of the suture line, one bite is inserted through the entire bladder wall to anchor the ureter and prevent it from pulling out of the tunnel. The

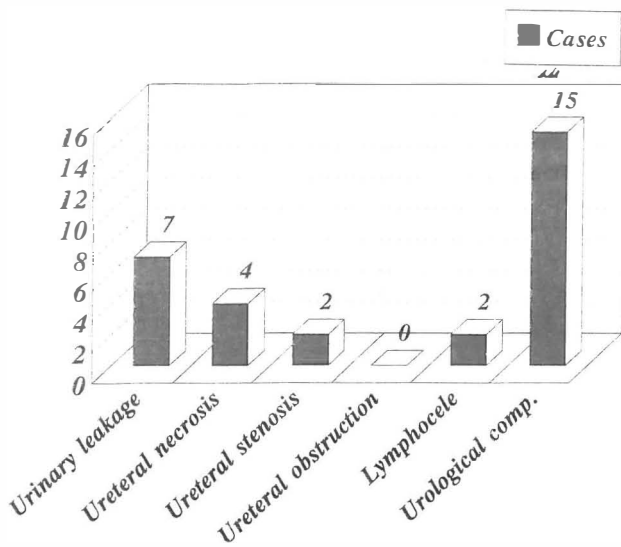


Fig. 5. Urological complications in the Licht group.

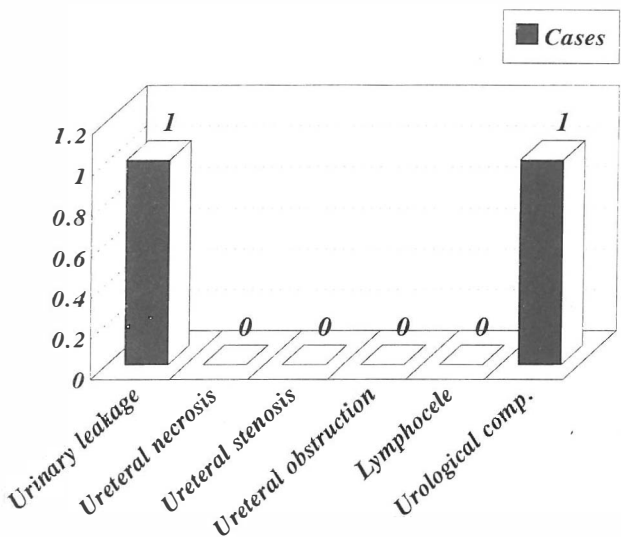


Fig. 6. Urological complications in the Barry group.

bladder muscle is then reapproximated loosely over the ureter with interrupted 3-0 chromic catgut sutures (Fig. 2).

**External tunnel method (Barry)<sup>4,6</sup>**

This technique is also easily done and does not need another incision for cystostomy. An incision 1 cm long is made with the scalpel on the anterolateral aspect of the bladder through the adventitia and muscularis, down to the submucosa. A second incision is made 3 cm from the first one and with a curved clamp, a tunnel is made 2 cm wide between these two incisions. A small opening (0.5 cm) is made in the bladder mucosa at the site of the second incision. The ureter is drawn through the tunnel and

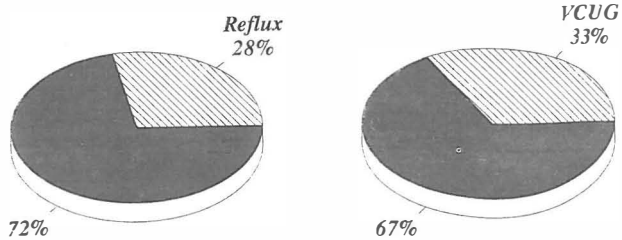


Fig. 7. Reflux rate and VCUg performance in the Licht group.

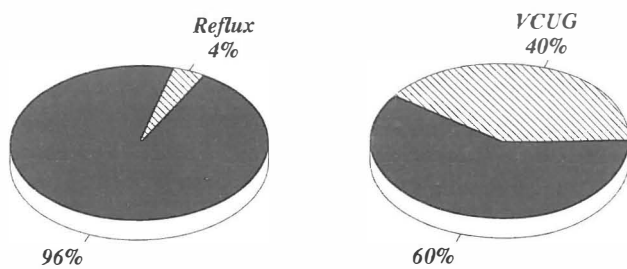


Fig. 8. Reflux rate and VCUg performance in the Barry group.

spatulated for a short distance and sutured to the opening with three sutures of 4-0 chromic catgut. A fourth suture is placed through the full thickness of the tip of the ureter and the entire bladder wall 1 cm distal to the mucosal opening and tied. The distal bladder opening is closed with 3-0 chromic catgut sutures – all layers but the mucosa. A stent is not needed (Fig. 3).

**RESULTS**

In this study, 15 cases (7%) of the modified Licht group and one case (2%) of the Barry group developed urologic complications (Fig. 4). Urinary leak occurred in 7 cases (3%) and in one case (2%) of the modified Licht and Barry group, respectively. Urinary leak improved in 3 patients with catheterization and antibiotic therapy alone.

In four patients urinary leak was due to necrosis at the site of anastomosis, necessitating open surgery and repair. All four patients belonged to the modified Licht group. No necrosis occurred in the Barry group. Urinary leak was seen between 5 to 14 days post-transplantation.

Ureteral stricture was seen in two cases (1%) of the Licht group, and both cases underwent open surgery and reimplantation. No such complication was seen in the Barry group. Two cases (1%) in the modified Licht group developed lymphocele. One subsided spontaneously without any complication, while the other one, which by exerting pressure on the ureter caused hydronephrosis, improved after intraperitoneal drainage (Figs. 5,6).

In 67 cases in the Licht group, voiding cystourethrography (VCUG) was done after 3 months. 19 cases (28%) had ureteral reflux into the transplanted kidney.

## Extravesical Ureteroneocystostomy—Comparison of Techniques

In the Barry group, 23 cases (40%) had VCUG, and only one patient had reflux (Figs. 7,8).

### DISCUSSION

Although transvesical ureteroneocystostomy was the method of choice in kidney transplantation,<sup>1,2,4,5,7</sup> more recently the lower complication rates of extravesical methods compared with transvesical methods have become obvious. In spite of the above mentioned fact, there is still much controversy regarding the proper technique.<sup>2,6,7</sup>

In this study two extravesical techniques (modified Licht's and Barry's) have been compared with respect to urological complications. Though the two groups did not have the same number of patients, in both groups specimens were from live donors. Regarding the sex of the patients, men were outnumbered in the Licht group. However, we do not think gender will have any effect on ureteral complications. Urologic complications in the Licht group were more frequent than in the Barry group (7% vs. 2%). Urological complications in the Barry group were comparable to what Barry et al. reported in 1000 cases of kidney transplantations (2.1%). Kas et al. have reported a 5.9% rate of urological complications with the modified Licht method, which is comparable to our study group (7%).

### REFERENCES

1. Debruyen FMJ, Hoistma AJ, Avedsen EH, Oosterhof GON: Surgical treatment of urological complications in kidney transplantation. *World Journal of Urology* 139: 65-75, 1988.
2. Hrair-George J, Oblan M, Miler CU, Hatchett RL, Azizkhan RG, Lacey SR: Modified extravesical ureteral reimplantation in pediatric renal transplantation; 5 years of experience. *J Urology* 147: 1340-2, 1992.
3. Thrasher JB, Temple DR, Spees EK: Extravesical versus Leadbetter-Politano ureteroneocystostomy. *J Urology* 144(11): 1105-9, 1990.
4. Barry JM: Renal transplantation. In: Walsh PC, Retik AB, Stamey TA, Vaughan ED Jr, (eds.), *Campbell's Urology*. Sixth ed, Vol 3, Philadelphia: W.B. Saunders, pp. 2500-1, 1992.
5. Lee HM: Surgical Techniques of Renal Transplantation, In: Morris PJ, (ed.), *Kidney Transplantation*. Philadelphia: W.B. Saunders Company, pp. 127-137, 1994.
6. Lee HM: Surgical techniques of transplantation. In: Morris PJ, (ed.), *Kidney Transplantation, Principals and Practice*. 3rd ed, Chapter 22, Philadelphia: W.B. Saunders, p. 511, 1988.
7. Kirkman RL, Tilney NL: Surgical complications in the transplant recipient. In: Allen RDM, Chapman JR, (eds.), *Renal Transplantation*. New York: Churchill Livingstone, p 231-43, 1989.
8. Gibbons WS, Barry JM, Hefty TR: Complications following unstented parallel incision extravesical ureteroneocystostomy in 1000 kidney transplants. *J Urology* 148 (7): 30-40, 1992.
9. Reinberg Y, Bumgardner G, Aliabadi H: Urological aspects of renal transplantation. *Urology* 143 (6): 1087-1092, 1990.

1. Debruyen FMJ, Hoistma AJ, Avedsen EH, Oosterhof GON: