

# ACUTE LOWER LIMB ISCHEMIA DUE TO FEMOROPOPLITEAL EMBOLISM OF HYDATID CYST

SEYYED MASSOUD KHATAMI, M.D.

*From the Department of Surgery, Baqiatallah Hospital, Baqiatallah University of Medical Sciences,  
Tehran, I.R. Iran.*

## ABSTRACT

In addition to the liver, human hydatidosis has been reported in the lung, brain, abdominal viscera, muscles, and heart chambers. Infarction of the brain has also been documented. Arterial embolism of the lower extremities by hydatid cyst, however, is extremely rare. In the presented case, acute ischemia of the patient's left leg led to gangrene and amputation. Complete workup for localization of the primary focus of hydatid cyst was inconclusive; however, the most probable explanation is spontaneous rupture of a left ventricular wall hydatid cyst which subsequently embolized to the aorta and lodged in the left femoral artery.

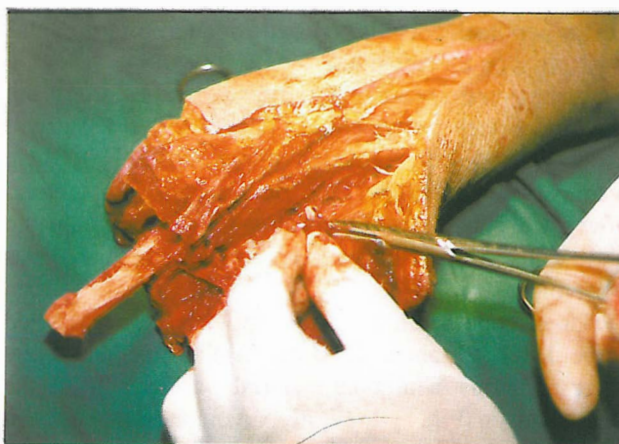
*MJIRI, Vol. 12, No. 2, 163-165, 1998.*

## INTRODUCTION

Hydatidosis or echinococcosis due to the cestode *Echinococcus granulosus* is a disease which has been reported worldwide, but is endemic in Asia, the Middle East, North Africa and Australia.<sup>6</sup> The adult worm or taenia lives in the small intestine of carnivores such as dogs, foxes, and wolves as the main host. Taenia eggs are excreted in the feces of these animals and either directly or by contamination of plants, fruits or vegetables, enter the gut of herbivores where the enzymes dissolve the eggs and the larvae are released. The larvae then travel to the liver or lungs and continue the cycle by growing a scolex and asexual reproduction.<sup>3</sup> The parasite again enters the main host as these contaminated animals are eaten by carnivores.

Man is an intermediate or accidental host of this parasite, and is infested by consuming contaminated plants or vegetables, or by contact with dogs. The larvae travel through the gut wall and 60-75% are filtered by the liver, and a few travel directly to the lungs to produce a hydatid

cyst there. The hydatid cyst has two layers, the laminated membrane and the germinative layer. Rupture of the germinative layer leads to production of daughter cysts. Intracystic pressure is high, about 300 cmH<sub>2</sub>O, and the fluid is alkaline.<sup>5</sup> Intraperitoneal cyst rupture can lead to anaphylactic shock, and rarely, increased IgE levels can lead to a polyarthritis.



**Fig. 1.** Amputated leg demonstrating presence of whitish material (daughter cyst) inside lumen of popliteal artery. Diameter of artery is greater than normal.

Correspondence: S. M. Khatami, M.D.  
Assistant Professor and Chief, Dept. of Surgery,  
Baqiatallah University of Medical Sciences,  
Vanak Square, Tehran, I.R. Iran.

## Femoropopliteal Embolism of Hydatid Cyst

Growth of hydatid cysts has been seen in the spleen, muscles, bones, and brain. Hydatid cyst of the myocardium, especially the left ventricle, has also been reported and may impinge on the coronary arteries. Embolism of the cyst to intracerebral arteries leading to brain infarction has also been rarely reported,<sup>8</sup> which is probably due to rupture of a left ventricular hydatid cyst, but embolism to peripheral limb arteries is extremely rare. Rupture of right ventricular hydatid cyst leading to multiple pulmonary emboli has also been rarely reported.<sup>2</sup>

Various serologic tests have been developed for diagnosis, such as Casoni test, serum immunoelectrophoresis, complement fixation and ELISA. Primary treatment of hydatid cyst is surgical extirpation, and for cases with diffuse involvement or where surgery is not feasible, drug therapy with mebendazole or albendazole is administered.

### Case report

A 22 year old male from the village of Mazandan was referred with severe left leg pain and cyanosis of the left toes from 7 days ago. He said the pain started after walking a short distance (about 300 meters) in the left calf. He was given analgesics by a physician, but tolerated the severe pain in his home despite the drugs and local therapy prescribed. He presented to us with severe pain and cyanosis of the toes of the left leg. He had no history of past illness, used no other medications, and did not smoke.

On physical examination, the patient appeared ill. Vital signs were stable and general examination was unremarkable except for the left leg. This limb was cold and immobile from below the knee, and mottling of the skin was present in the calf and dorsum of the foot. Calf muscles were tense and tender to palpation. The third and fourth toes were completely cyanosed and skin demarcation was at the proximal phalanges. Femoral pulse was normal bilaterally, but the popliteal, dorsalis pedis and tibialis posterior pulse was absent on the left side.

Embolectomy was attempted via the femoral artery, but the balloon catheter which was passed with difficulty to about 20 cm distally extracted no clot material and there was no arterial backflow. Flow from the proximal femoral artery was intact. Distal leg pulses remained impalpable and due to gangrene and fever, below knee amputation was performed.

Upon amputation, the distal popliteal artery was noted to be distended, about 2.5-3 cm in diameter, and white colored fibrous membrane material was seen inside the arterial lumen (Fig. 1). In Fig. 2, part of the artery has been removed and shows the white, daughter cyst-like material inside its lumen. The artery along with its embolized contents was sent for pathological examination. The pathology report was "germinative layer of hydatid cyst"

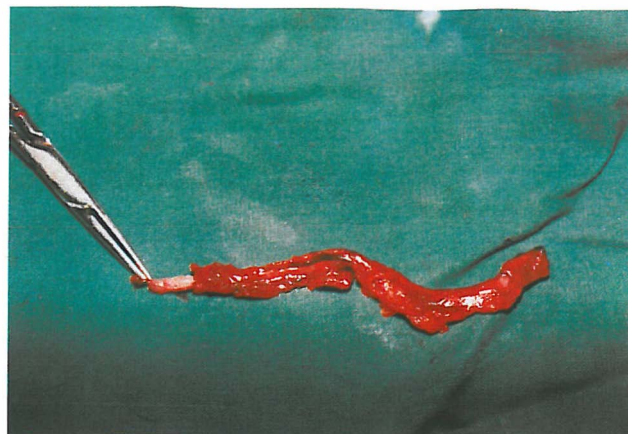


Fig. 2. Removed specimen of popliteal artery distended with daughter cysts.

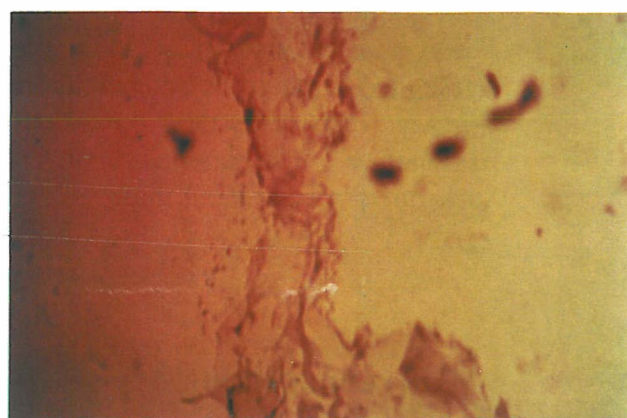


Fig. 3. Microscopic details of daughter cyst wall.

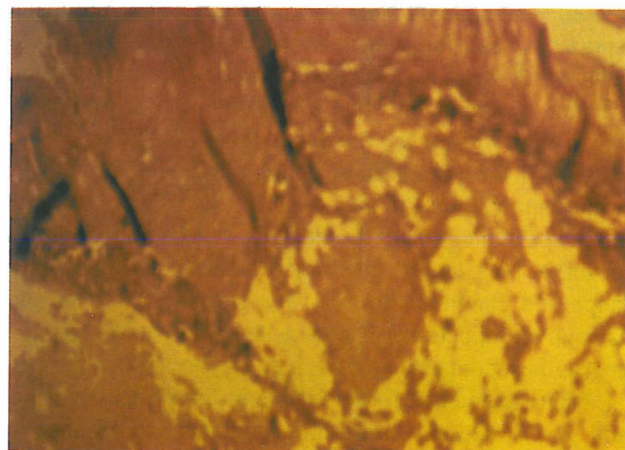


Fig. 4. Microscopic view of arterial wall showing fibrosis and inflammation.

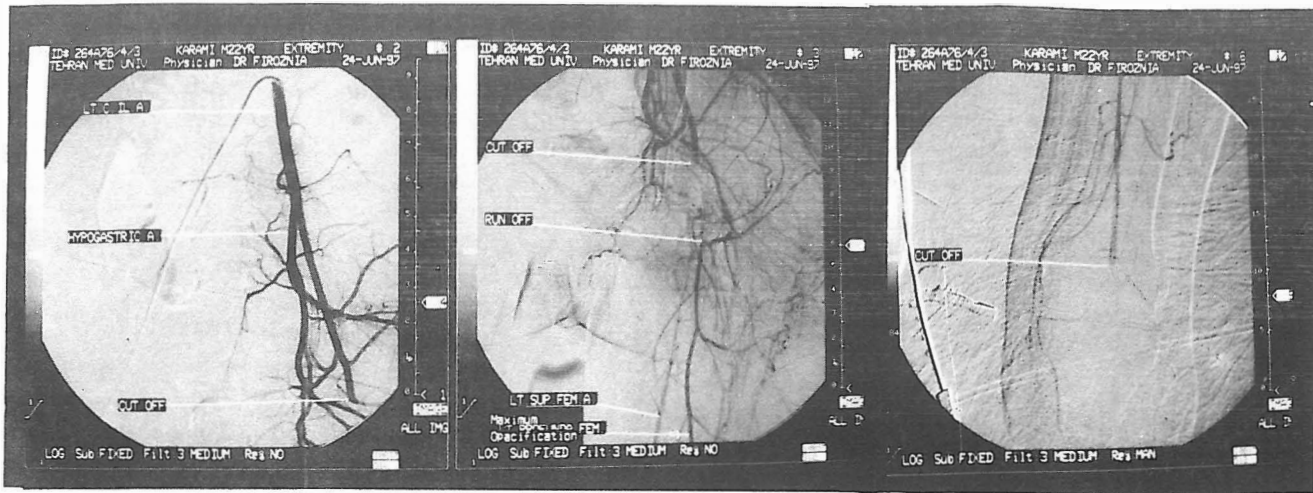
and the arterial wall showed "fibrosis with areas of calcification and signs of inflammation" (Figs. 3,4).

Complete evaluation for localization of the primary cyst focus was undertaken. Angiography of the aorta, common, deep and superficial femoral artery with digital



A

B



**Fig. 5.** Digital subtraction angiography. **A**, Occlusion of left common femoral artery with delayed run-off in the superficial and deep femoral arteries. **B**, Occlusion of left popliteal artery behind the knee joint.

subtraction angiography was performed. The aortic bifurcation and right femoral vessels were patent, but the left common femoral artery was completely occluded. The left deep femoral artery was visualized by collaterals with faint visualization of the superficial femoral artery. The segment between the superficial femoral and popliteal artery again showed complete occlusion, with collaterals via the genicular arteries.

Echocardiography (transthoracic and transesophageal) revealed no abnormalities in any of the heart chambers. Thoracic and abdominal CT scan with and without contrast was normal. Immunoelectrophoresis was positive for hydatid cyst, and the patient was administered albendazole in adequate dose.

## DISCUSSION

This case comprises a very rare presentation of hydatid cyst. With respect to the fact that the primary focus of the cyst was not found on extensive workup and growth of the cyst is not possible in large arteries due to the velocity of blood flow, two probabilities exist. First, the hydatid cyst may have grown adjacent to a major artery such as the aorta or iliac vessels and eroded into the vessel with progressive growth. However, this would necessitate massive bleeding due to erosion of the vessel wall. Furthermore, remnants of the cyst should easily be visualized on angiographic evaluation, but this was not the case. The second probability is that the cyst—with growth in the myocardial wall, most likely the left ventricle—suddenly ruptured into the left ventricular chamber and daughter cysts were embolized to the aorta, left iliac vessels and left lower extremity. Although no remains of the cyst were picked up on echocardiography, this is still the strongest probability.

Reports of hydatid cyst in various chambers of the heart exist in the literature.<sup>6</sup> Gibson reported 48 cases of cardiac hydatid cyst, and the left ventricle was the most commonly

involved chamber.<sup>2</sup> Generally, about 1-2% of hydatid cysts occur in the heart. Larvae reach the myocardium via the coronary arteries and lead to cyst production which rupture into the cardiac chambers.<sup>2</sup> It has been stated that cardiac hydatid cyst occurs in childhood and presents in young adulthood, which is in accord with the presented case.

We conclude that cardiac hydatid cyst may embolize via the aorta and cause acute arterial occlusion and ischemic complications. Therefore, cardiac hydatid cyst must be treated urgently by surgery to prevent serious complications such as cerebral or peripheral embolism and ischemia. Effects of cyst fluid on the arterial wall may be a cause of arterial inflammation and fibrosis, and merits further studies.

## REFERENCES

1. Pasaoglu I, Dogon R, Hazan E, Oram M: Right ventricular hydatid cyst causing recurrent pulmonary emboli. *Eur J Cardiothorac Surg* 6 (3): 161-63, 1992.
2. Gibson DS: Cardiac hydatid cyst. *Thorax* 19: 151-58, 1964.
3. Barenas SA, Lillemo K: Liver abscess and hydatid cyst. In: Zinner M, Schwartz SI, Ellis H, (eds.). *Maingot's Abdominal Operations*. Norwalk: Appleton and Lange, Vol. II, 1994.
4. Carena J, Smuckler C, Sejanovich G: Multiple cerebral hydatid disease. *Medicin B Aires* 54 (3): 245-47, 1994.
5. Schwartz SI: Liver. In: Schwartz SI, Shires GT, Spencer FC, Storer EH, (eds.). *Principles of Surgery*. 6th ed, New York: McGraw-Hill, 1994.
6. Saidi F: *Surgery of Hydatid Disease*. London: W. B. Saunders Co, p. 302, 1970.
7. Hamani KA, Zbir E: Hydatid cyst of the heart. *Arch Mal Coeur Vaise* 85 (1): 95-98, 1992.
8. Jidden M, Benomar A, Yahaoui M, Chkili T, Boukhrissi N: Cerebral vascular accident due to hydatid embolism. *J Neuroradiol* 23 (2): 74-8, 1996.

