

PHEOCHROMOCYTOMA OF URINARY BLADDER: REPORT OF A CASE AND BRIEF REVIEW OF THE LITERATURE

S.M. HOMAYOUNI, M.D., S.Z. LATIFZADEH, M.D., AND
M.H. KALANTAR MOTAMEDI, M.D.*

*From the Department of Internal Medicine, Shohada Medical Center, Shahid Beheshti University of Medical Sciences, and the *Dept. of Cardiovascular Surgery, Baqiat. University of Medical Sciences, Tehran, Islamic Republic of Iran.*

ABSTRACT

A case of pheochromocytoma of the bladder is presented with a review of the literature. We discuss general management principles of bladder pheochromocytoma. Successful diagnosis and treatment of this lesion requires a high index of suspicion based upon the patient's symptom complex, allowing preoperative preparation prior to surgical treatment.

MJIRI, Vol. 12, No. 2, 171-176, 1998.

INTRODUCTION

Pheochromocytomas are chromaffin cell tumors that are derived from neuroectodermal tissue of the adrenal gland and sympathetic paraganglia. These tumors can arise anywhere in the body from the skull (glomus and carotid bodies) to the bladder and prostatic glands. Pheochromocytomas of the urinary bladder are rare tumors, accounting for approximately 1% of extraadrenal pheochromocytomas and 0.06% of bladder tumors.

We report a case of vesical pheochromocytoma in a patient with a twelve year history of post-micturitional palpitation and anxiety and other related symptoms such as blurred vision, headache and occasional dysuria which was mismanaged for a long time before correct diagnosis.

The symptom complex, radiographic diagnosis and subsequent treatment of this entity are reviewed.

Case report

A 25 year old male was admitted to our department because of anxiety and palpitations associated with

Correspondence: S.M. Homayouni, M.D., Dept. of Internal Medicine, Shohada Medical Center, Shahid Beheshti University of Medical Sciences, Tehran, I.R. Iran.

micturition. He had a twelve year history of postmicturitional throbs in the chest. At the time after each voiding he developed headache, diaphoresis, flushing, light-headedness, chest pain and palpitations. These symptoms occurred as paroxysms with a few minutes' duration. He experienced these attacks sometimes after defecation and on some occasions, spontaneously. In this regard he sought medical attention frequently and had taken different medications for controlling headache and chest discomfort but the symptoms were not improved. There was also a history of periodic presence of dysuria, frequency and dribbling. He said the severity of each attack was distinct from others. The above problems continued until 2-3 years ago, when he noticed a slight decrease in intensity of symptoms. In the few previous months, anxiety, blurring of vision, and postural dizziness and fainting after micturition (or with no precipitating cause) had been the chief complaints.

The past medical history was negative other than redness of the eyes and conjunctival congestion during the past 10 years. He had never had high blood pressure, and he smoked five cigarettes per day over a period of seven years. In his close relatives, family history was negative and his wife and child are both healthy.

His blood pressure was 150/90 mmHg and pulse rate




Fig. 1. ECG tracing before and after urination.

was 72 bpm at rest. After micturition it increased to 180/110 mmHg and heart rate dropped to 64 bpm (Fig. 1). In the head and neck the only positive finding was conjunctival congestion. Examination of the heart and chest was unremarkable. The abdomen was normal without any palpable mass. After deep palpation of the abdomen the blood pressure was not changed. Digital rectal examination was negative. Laboratory data revealed normal urinalysis, blood counts and chemical values. Routine X-ray showed normal findings. Sonography of the abdomen and pelvis was unrevealing. Successive 24-hour urine collections showed vanillylmandelic acid values of 14.5 mg per day and 15 mg per day. (normal: 0.5-12 mg/day). Electrocardiography at rest was normal but after voiding the normal sinus rhythm changed to junctional rhythm, T waves became negative in leads V_2 - V_4 , and the heart rate decreased to 40-50 bpm. The arrhythmia disappeared without any intervention in a few minutes.

For further evaluation intravenous pyelography was done. The radiologist reported that the left wall of the bladder had a filling defect (Figs. 2,3). Computerized tomography was performed with contrast agent which indicated the presence of a pelvic mass adjoining to the bladder wall (Fig. 4).

Regarding the classic clinical findings and revealing laboratory and imaging techniques, with the probable diagnosis of vesical pheochromocytoma, the patient was placed on phenoxybenzamine for 10 days and then propranolol was added. He was prepared for operation with prophylactic antibiotics, hydration, large bowel enema and reservation of blood. Ten minutes after the induction of anesthesia, he had a hypertensive crisis which was managed

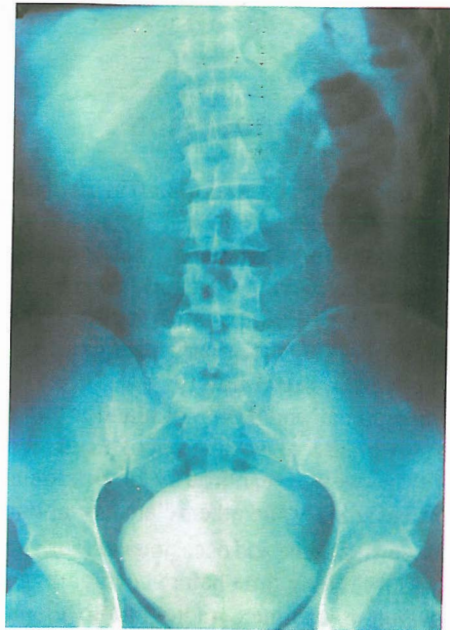


Fig. 2. IVP showing filling defect on the left side of the bladder.

with a change in dosage of halogenated anesthetics and nitroprusside. Abdominal and pelvic exploration via midline incision showed a mass completely attached to and infiltrating the bladder wall. Partial cystectomy was performed. A smaller tumor was found in the draining lymphatic system of the bladder. Both masses were excised

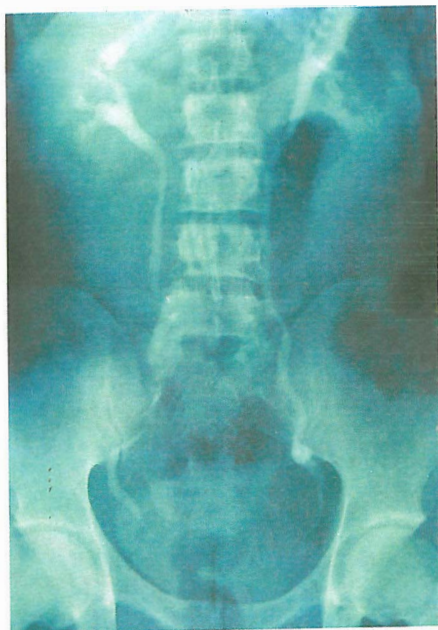

Fig. 3. IVP showing deviation of the left ureter.

and sent for pathologic diagnosis (Figs. 5,6). The first tumor was 4×5.5×7 cm in size and weighed 60 gr and the second was 2×3×4.5 cm in size and weighed 15 gr. During the first postoperative day the patient experienced a gradual drop in blood pressure which was corrected with administration of crystalloid fluids (Fig. 7). Two weeks after operation the patient was discharged from the hospital in excellent health. He did not return for follow up.

DISCUSSION

Zimmerman, Biron and MacMahon reported the first case of pheochromocytoma of the urinary bladder in 1953.²⁸ Thirty years later, in 1985, Das, Lowe and Bulusu raised the number of reported cases to 100 by introducing three new patients.⁵ In 1991 Sweetser, Ohl and Thompson reviewed the literature and increased the number of cases to 168,²⁵ after collecting the dispersed cases.³ Despite other cases being reported thereafter, the number of reported cases has not exceeded 200 so far.²⁶

Literally, paraganglia refers to the collection of neural crest cells which are distributed all over the body. These are collateral autonomic ganglia and include the adrenal medulla, chemoreceptors (aortic and carotid bodies), vagal bodies and small groups of cells which are dependent to the neck, chest and abdominal sympathetic ganglia. Functional paraganglion tumors are known as extra-adrenal pheochromocytomas.²⁶ About 1% of all pheochromocytomas occur in the urinary bladder.²⁰ The primary bladder pheochromocytoma is derived from the

remainder of the embryonic chromaffin cells in the sympathetic plexus of the bladder wall.¹² For pathologic classification of these tumors there is a lack of general agreement, but most researchers favor the classification system proposed by Glenner and Grimley in 1974. Based on this scheme the bladder pheochromocytoma is classified as "visceral-autonomic type". Histologically, paragangliomas including the bladder are composed of two groups of cells: the chief cells (type 1) are round or oval and contain neurosecretory granules in which catecholamines are reserved, and the sustentacular cells (type 2) that are located around the chief cells with less percentage. It must be noted that histological criteria for malignancy in this tumor as other endocrine tumors are not discrete. In paraganglioma and pheochromocytoma, malignant behavior may not be predicted by the presence of nuclear atypia, increased numbers of mitoses or capsular and vascular invasion. The only valuable criterion for diagnosis of malignant nature is existence of paraganglial tissue in areas other than its native places such as lymph nodes, bone, liver and lung.^{6,7,14,15,27} Therefore the presented case in this report can be assigned as malignant due to the invasion by the tumor of the draining lymph nodes.

Based on the afore-said definitions, about 10-15% of pheochromocytomas of the urinary bladder are malignant^{5,6,10,22,25} and so far, only 20 cases of malignant tumors of this type have been reported.²¹ Unlike adrenal malignant tumors, pheochromocytoma of the bladder is seen in association with other diseases such as neurofibromatosis,² renal cell carcinoma^{7,24} and transitional cell carcinoma of the bladder.¹⁷

The age of onset of the disease is between 11-78 years (mean age 41) and it is distributed evenly among men and women, probably with a slight increase in females. Most of these tumors are hormonally active (38%) and in 34-41% of cases are located in the dome or trigone of the urinary bladder near the ureteral orifice and grow intramurally or submucosally.^{4,10,12,20,25,26}

The release of catecholamines into the circulation during micturition causes a complex of diverse symptoms including headache, palpitation, hypertension, blurred vision and sweating. The most common complaint is painless hematuria and the most common finding in these patients is intermittent hypertension, present in 55-60% and 65-70% of the patients, respectively.^{2,4,5,10,12,26} The blood pressure of these patients is often normal between micturitions. Dysuria and suprapubic pain is observed in 9% of the patients. For diagnosis, particularly at the onset of headache, sweating and palpitation following urination, there must be a high index of suspicion. These symptoms may become established after fullness of the bladder, abdominal palpation, defecation, intercourse, rectal examination and sometimes following paroxysmal psychological changes.^{4,12,19,26,27}

The symptoms will be intensified if urination is delayed

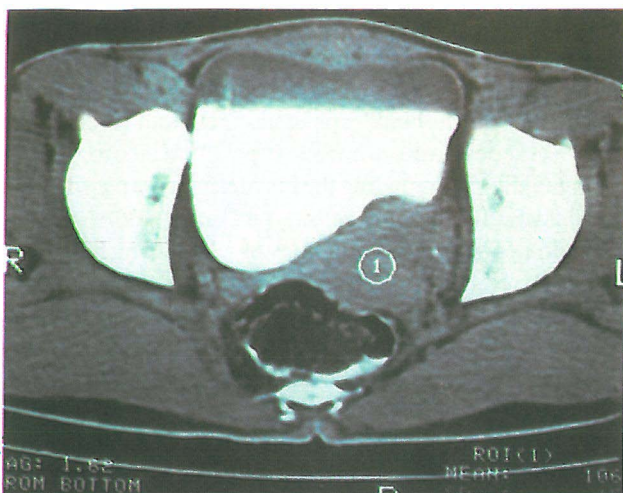


Fig. 4. Patient's CT scan showing the mass effect of the tumor on the bladder wall.

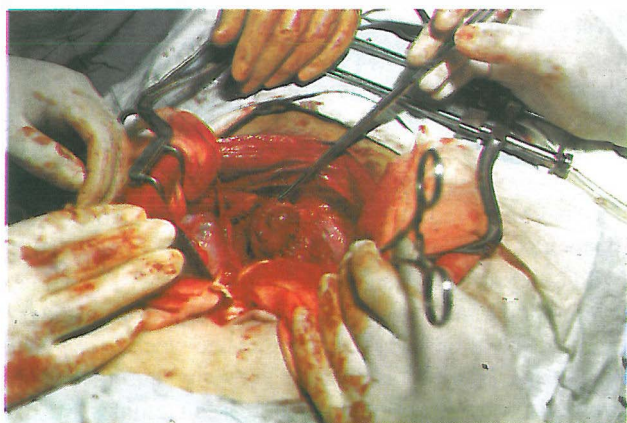


Fig. 5. The resected specimen.

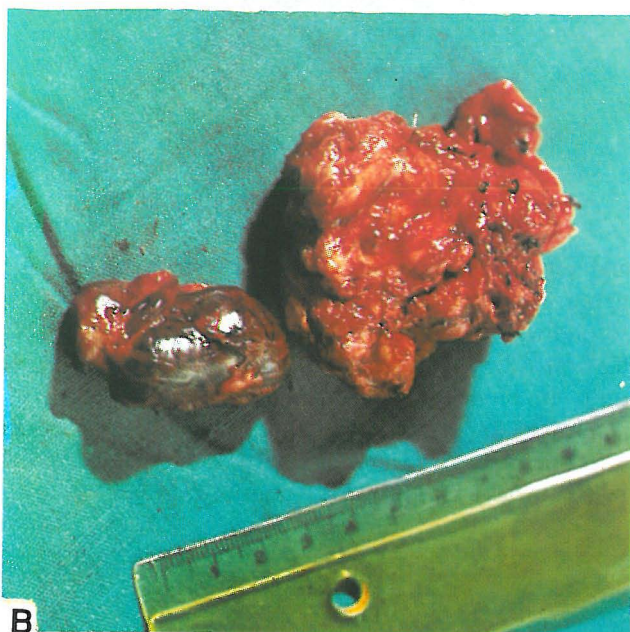
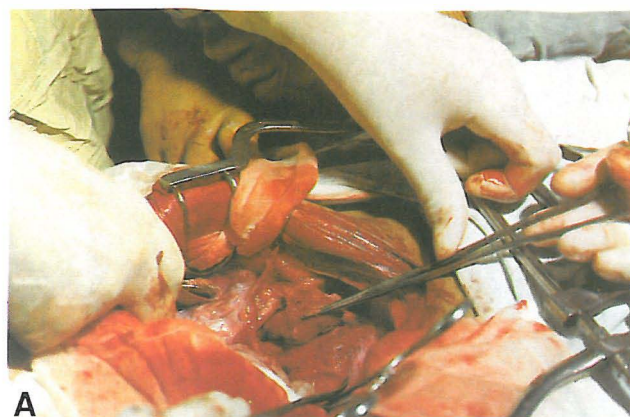


Fig. 6-A,B. Removal of the adjacent tumoral mass.

due to overdilatation of the bladder. Sometimes the onset of hypertension in these patients is associated with appearance of severe headaches and loss of vision. Malignant hypertension and death may occur following the consumption of drugs, use of anesthetics and/or surgery of other parts of the body.²⁵ If cases of stable and transient hypertension are considered together, elevated blood pressure will be present in 65-80% of the patients.²⁷

The diagnosis is confirmed by demonstrating increased urinary excretion of catecholamines (epinephrine and norepinephrine) or their metabolites (metanephrine and vanillylmandelic acid) or increased plasma concentrations of catecholamines, although these tests were negative in a considerable percentage of patients whose disease was proven pathologically, as all urinary bladder pheochromocytomas do not secrete pressor amines.¹⁸ There is no single best test that can be regarded as ideal for this disease and the priority of the tests is determined by the capabilities of the individual laboratory.²⁷

However, Engelman believes that measurement of urinary catecholamines during a period in which the patient is not taking drugs which interfere with the assays, remains the gold standard for diagnosis.⁸ It is worthy to note that in most cases the release of sympathetic amines occurs following urination and often at other times their level in blood or urine is not abnormal. Therefore, in suspicious cases it can be advised to collect 24-hour urine or to take a spot blood or urine sample immediately after a paroxysm. There are reports of urinary bladder pheochromocytoma with a high catecholamine excretion without hypertension.¹¹

In the plain radiograph of the abdomen it is rare to see ring calcification, which is considered pathognomonic for urinary bladder pheochromocytoma by some investigators. A filling defect and/or ureteral obstruction may be seen in IVP but are non-specific. Ultrasound was used in 1984 for

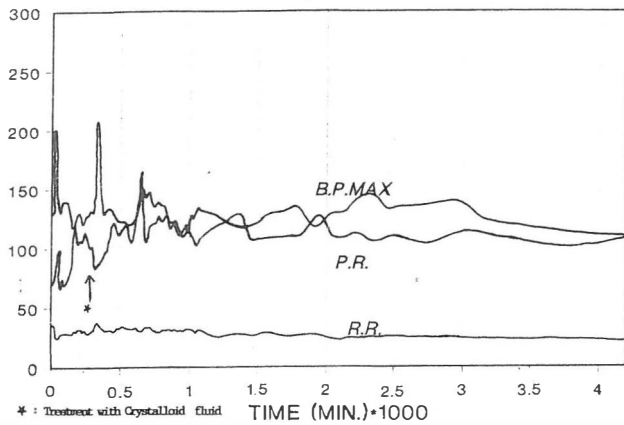


Fig. 7. Perioperative vital signs.

the first time for diagnosing this disease but this method is very non-specific.¹³

Since the introduction of computerized tomographic scan it has been selected as the imaging procedure of choice for the localization of pheochromocytoma at many centers. It was revealed in a review that the sensitivity of CT-scan for the diagnosis of tumor in adrenal pheochromocytoma is 94% and for extra-adrenal tumors is 82%.²⁷

It is important to know that in vesical pheochromocytoma, opacification of the bladder after injection of contrast may produce a false negative result. Magnetic resonance imaging was first used in 1987 for localizing pheochromocytoma of the urinary bladder. The image obtained by T₂-weighted method makes a very proper spatial contrast and this method is performed successfully for pregnant women. There are a few radioisotope agents which have been used for localizing extra-adrenal pheochromocytomas and among them I¹³¹-MIBG and DTPA were more helpful for this purpose. Since the radionuclide agent is excreted in the urine, the imaging may have false positive results, unless arrangements are adopted for good emission of urine from the bladder.

Placement of a Foley or triple-lumen catheter and continuous irrigation of the bladder while performing the procedure will increase the diagnostic power.²⁵ Pheochromocytoma of the urinary bladder can be seen by cystoscopy in 80% of the cases.^{1,7}

Biopsy performed endoscopically can cause problems because of excessive vascularity of the tumors of the bladder.¹³ Cystoscopy usually reveals a submucosal mass, which is located in the trigone of the bladder. Since most of the bladder transitional cell carcinomas involve the mucosa, existence of a submucosal tumor in the trigone or dome of the bladder must create the assumption of vesical pheochromocytoma.²³ Concerning the presentation and diagnosis of our reported case, it must be mentioned that the patient had a ten year history of characteristic symptoms

but these findings were frequently missed by health care providers.

It is noteworthy that our patient had red congested eyes in the past 10 years as a constant finding. At his first visit in our clinic, the electrocardiogram showed typical postvoiding abnormalities. The first attempts for confirming the suggested diagnosis were unrevealing. Excretion of catecholamines was slightly above normal and sonography was negative. Further investigation however showed a pelvic mass related to the bladder wall causing a filling defect in IVP and CT-scan.

Treatment of vesical pheochromocytoma requires surgical excision, usually in the form of partial cystectomy.²⁶ For performing a surgical operation with less complications and better results, all patients must be fully prepared with sympathetic blockade preoperatively. Treatment by α -adrenergic blockers allows us to increase the intravascular volume.

Therefore, treatment with α -blockers starts two weeks before the operation. This is usually done with phenoxybenzamine, and following this blockade, orthostatic hypotension occurs which needs fluid substitution.²⁶ After complete blockade, normalization of blood pressure (when it was high previously), orthostatic hypotension, weight gain, diarrhea, nasal stuffiness and decrease in hematocrit occur. β -blocker drugs are used only when tachycardia or catecholamine-induced arrhythmias are present⁸ and full blockade of α -receptors is instituted.²⁶ For this purpose labetalol is usually used, which also has α -blocker effects. It is worthy to note that the physician must be informed about the disturbance produced by this drug for interpretation of biochemical tests and it is better that they be used after making the definite diagnosis.^{8,27}

In case sympathetic blockade is not done properly, there is always the possibility of sudden-onset catecholamine release and induction of hypertensive crisis and life-threatening events. There are some reports of non-cardiogenic pulmonary edema during operation. Using new and modern techniques and different drugs (such as barbiturates, benzodiazepines, halogenated anesthetics, metacholine,...) during induction and the maintenance phase of anesthesia may decrease the rate of complications.

REFERENCES

1. Bourne RB, Beltaos E: Pheochromocytoma of the bladder. *J Pathol Bact* 98: 361, 1967.
2. Burton EM, Schellhammer PF: Paraganglioma of urinary bladder in patients with neurofibromatosis. *Urology* 27(6): 550-52, 1986.
3. Chen TZ: Pheochromocytoma of the urinary bladder. *Chung Hua Ping* 20(1), 60-2, 1991.
4. Cronan JJ, Huy M: Bladder pheochromocytoma (color

Bladder Pheochromocytoma

- Doppler). *British Journal of Urology* 67: 548-57, 1991.
5. Das S, Bulusu NV, Lowe P: Primary vesical pheochromocytoma. *Urology* 21: 20-25, 1983.
 6. Davis P, Peart WS, Van't Hoff W: Malignant pheochromocytoma with functioning metastases. *Lancet* 2: 274, 1955.
 7. Declerk DP, Catalona WJ: Malignant pheochromocytoma of the bladder. *J Urol* 113(6): 864-8, 1975.
 8. Engelman K, Dweck E: Perivesical pheochromocytoma. *J Nucl Med* 31(6): 1669-74, 1990.
 9. Flanigan RC, Wittmann RP: Malignant pheochromocytoma of urinary bladder. *Urology* 16(4): 386-8, 1980.
 10. Frydenberg M, Ferguson R: Malignant pheochromocytoma of the urinary bladder. *British Journal of Urology* 67: 548-57, 1991.
 11. Gelfand MJ: MIBG scan in children. *Semin Nucl Med* 23(3): 231-42, 1993.
 12. Heyman J, Cheung Y: Bladder pheochromocytoma: evaluation with MRI. *Journal of Urology* 141(6): 1424-6, 1989.
 13. Hull CJ: Pheochromocytoma. *Br J Anesth* 58: 1453-68, 1986.
 14. Hurwitz R, Fitzpatrick T: A neuroectodermal tumor in the bladder. *Journal of Urology* 124(3): 417-21, 1980.
 15. Javaheri P, Raafat J: Malignant pheochromocytoma of the urinary bladder. *Br J Urology* 47(4): 401-5, 1975.
 16. Kolawole TM, Nkposong EO: Ring calcification in a bladder pheochromocytoma. *Brit J Radiol* 48: 931-2, 1975.
 17. Leong CH, Wong KK, Saw D: A symptomatic pheochromocytoma of the bladder coexisting with carcinoma. *Brit J Urol* 48: 123, 1976.
 18. Ludmerer KM, Kissane JM: Micturition-induced hypertension in a 58 year old woman. *Am J Med* 78(2): 307-16, 1985.
 19. Manger WM, Gifford RW, Hoffman BB: Pheochromocytoma: a clinical and experimental overview. *Curr Prob Cancer* 9: 1, 1985.
 20. Melicow MM: One-hundred cases of pheochromocytoma. *Cancer* 40(5): 1987-2004, 1977.
 21. Michel F, Gottegnio B: Report of a case of malignant pheochromocytoma. *Ann Urol Paris* 24(5): 396-9, 1990.
 22. Noldus J, Otto U: Pheochromocytoma of the urinary bladder. *Urologe-A* 30(4): 272-4, 1991.
 23. Ochi K, Yoshioka S, Morita M, Takeuchi M: Pheochromocytoma of the bladder. *J Urology* 17: 228-30, 1961.
 24. Puvaneswary M, Davoren P: Pheochromocytoma of the bladder: ultrasound appearance. *J Clin Ultrasound* 19(2): 111-15, 1991.
 25. Sweetser PM, Ohl DA, Thompson NW: Pheochromocytoma of the urinary bladder. *Surgery* 109: 677-81, 1991.
 26. Thrasher JB, Humphrey PA: Pheochromocytoma of urinary bladder. *Urology* 41(3): 435-9, 1993.
 27. Walen RK, Althausen AF: Extra-adrenal pheochromocytoma. *J Urol* 147(1): 1-10, 1992.
 28. Zimmerman IJ, Biron RE, MacMahon HE: Pheochromocytoma of the urinary bladder. *N Engl J Med* 249: 25, 1953.