

PRIMARY HYPEROXALURIA: REPORT OF FOUR CASES AND REVIEW OF THE LITERATURE

T.J. AJUDANI, M.D., M. GHARAVI, M.D., AND B. BASTANI, M.D.*

*From the Isfahan University of Medical Sciences, Isfahan, Iran, and the *St. Louis University Health Sciences Center, St. Louis, Missouri, USA.*

ABSTRACT

In this paper we will present four cases of primary hyperoxaluria. All patients had a significant past medical history of polyuria (with or without microscopic hematuria) and polydipsia. All patients had a family history of their parents being cousins. Initial evaluation of all patients by ultrasound and plain abdominal films revealed nephrocalcinosis. Their clinical courses showed gradual loss of renal function over the follow-up years. We will also review primary hyperoxalurias and their management in this report.

Keywords: Oxalate, hyperoxaluria, oxalosis, renal failure, transplantation.

MJIRI, Vol. 12, No. 1, 79-84, 1998.

INTRODUCTION

Primary hyperoxaluria is a rare autosomal recessive genetic disorder which is characterized by an excessive amount of oxalate excretion in the urine. Three different types of primary hyperoxaluria have been identified (Table I).¹ Type I, the most common type, is characterized not only by excessive hyperoxaluria but also by glycolic aciduria. Primary hyperoxaluria type I (PH1) is due to deficiency of a hepatic peroxisomal enzyme named alanine glyoxalate aminotransferase (AGT). Figure 1 shows a simplified schematic representation of the metabolic pathways leading to oxalate production, as well as the role of defects in AGT resulting in hyperoxaluria and glycolic aciduria. Primary hyperoxaluria type II (PH2) which is characterized by hyperoxaluria and L-glyceric aciduria, is due to a deficiency of D-glycerate dehydrogenase, an enzyme which is normally present in hepatocytes and white blood cells. Primary hyperoxaluria type III (PH3) is characterized by hyperoxaluria alone and no associated glycolic or glyceric

aciduria. PH3 is due to hyperabsorption of oxalate from the gastrointestinal tract, without any underlying pathology (e.g., fat malabsorption).

Alanine glyoxalate aminotransferase (AGT), deficiency of which is responsible for PH1, is an enzyme that in humans is solely present in the peroxisomes of hepatocytes. So far, several different mutations have been identified in the AGT gene.²⁻⁵ Some have been responsible for abnormal targeting of the enzyme so that it will be stored in the hepatocyte mitochondria rather than peroxisomes, and thus is rendered non-functional. Some other mutations have been responsible for abnormal aggregation of the enzyme in peroxisomes resulting in a non-functional enzyme. Finally, some mutations have been responsible for an unstable AGT protein with a very short half life which is rapidly degraded, resulting in deficiency of the enzyme in the peroxisomes. Because of these different genetic mutations, 50% of patients with PH1 have neither immunoreactivity nor AGT enzyme activity in their liver biopsy. The other 50% of patients show protein immunoreactivity on immunoblots. However, in 20% of them there is no catalytic AGT enzyme activity, indicating a defective protein which is non-functional. In the other 30%, patients not only show immunoreactivity for the protein but also have catalytic enzyme activity.

Address for Correspondence:

Bahar Bastani, M.D.,
Associate Professor of Internal Medicine, Division of Nephrology, St.
Louis University Health Sciences Center, 3635 Vista Avenue, 9N-FDT, St.
Louis, MO, USA, 63110 Phone: 314-577-8765 Fax: 314-771-0784

Hyperoxaluria

Nevertheless, on immunohistochemical staining the AGT protein is found only in the mitochondria (Figure 2). The abnormal targeting of AGT to the mitochondria rather than peroxisomes is responsible for enzyme deficiency in the latter group.

Because of the variety of genetic variations, PH1 can present in a variety of different clinical presentations. In general, three different clinical forms have been described. The infantile type has generally a very rapid progressive course leading to renal failure. The patients do not develop renal stones but diffuse renal oxalosis/calcification. The juvenile form, the most common presentation, clinically presents between the ages of 2-18 years. These patients develop recurrent multiple calcium oxalate nephrolithiasis and progressive renal insufficiency secondary to recurrent pyelonephritis and obstructive complications. The adult form is less common and typically manifests as renal failure of unknown etiology with diffuse renal calcinosis/oxalosis and systemic complications of oxalosis such as livedo reticularis, bullae formation, skin gangrene, osteosclerosis, bone fractures, anemia, digital gangrene, cardiomyopathy and cardiac conduction effects, peripheral neuropathy or mononeuritis multiplex, and visual disturbances due to oxalate crystal deposition retinopathy.

Since the kidneys are the only organ responsible for disposal of oxalate from the body, as the kidney function declines, particularly with a $GFR < 15 \text{ mL/min/1.73m}^2$, oxalate is retained in plasma, resulting in supersaturation and precipitation in tissues, commonly referred to as systemic oxalosis.

Differential diagnosis of hyperoxaluria includes secondary forms of the disorder (Table II). Secondary hyperoxaluria could be due to excessive dietary intake of oxalate or excessive consumption of ascorbic acid (vitamin C) which is converted directly to oxalate in hepatocytes. Other causes of secondary hyperoxaluria include disorders resulting in fat malabsorption such as small bowel resection/bypass or pathology, pancreatic insufficiency, and biliary disorders. As a result of fat malabsorption, free fatty acids that enter the large bowel will bind dietary calcium in a process called saponification. Thus, less calcium will be available to bind oxalate anion, precipitating it as insoluble unabsorbable calcium oxalate salts. The free oxalate will bind to sodium, forming a more soluble salt which is

Table I. Forms of primary hyperoxaluria.

-Type I: Hyperoxaluria & glycolic aciduria (Alanine glyoxalate aminotransferase deficiency)

-Type II: Hyperoxaluria & L-glyceric aciduria (D-glycerate dehydrogenase deficiency)

-Type III: Intestinal (hyperabsorptive) hyperoxaluria

absorbed from the colon contributing to oxalemia and oxaluria. Other less common causes of secondary hyperoxaluria include ethylene glycol (anti-freeze) poisoning and methoxyflurane anesthesia.

In this report, we present four new cases of primary hyperoxaluria who were diagnosed in the pediatric outpatient clinic of Isfahan University of Medical Sciences during the period of 1989-1995.

Case 1

G.B., currently a 13 year old girl (149 cm height, 35 kg weight), was first seen six years earlier. She has a history of polyuria since she was 2 years old, has had frequent urinary tract infections, and a history of leg pain of unknown etiology at age 9. Her family history was significant for her parents being cousins. When first seen at age 7, she was 129 cm in height and weighed 25 kg, had a normal physical examination, normal liver function tests, and normal arterial blood gas values. Initial laboratory evaluation at age 7 revealed a serum creatinine of 0.9 mg/dL; BUN 19 mg/dL; calcium 9.5 mg/dL; phosphorus 4.0 mg/dL; alkaline phosphatase 125 U/L; and creatinine clearance 58 mL/min/1.73 m². Her urinalysis revealed a specific gravity (SG) of 1.008 and urinary pH of 5.0. A 24 hour urine volume was 3200 mL; 24 hour urine calcium was 135 mg; 24 hour uric acid was 657 mg; 24 hour urine oxalate was 152 mg. Ultrasound examination of the kidneys revealed nephrocalcinosis in both kidneys and questionable renal stones but showed no evidence of hydronephrosis (Figure 3). With a clinical impression of primary hyperoxaluria she was treated with high oral fluid intake, oral orthophosphate, and vitamin B₆ (pyridoxine). The latter was discontinued after a few months since there was no beneficial effect. Two years later she was found to have a serum creatinine of 1.3 mg/dL with a creatinine clearance of 54 mL/min/1.73 m². Four years later she was found to have small kidneys (~7.7 cm) on ultrasound. Her serum creatinine was 1.9 mg/dL and creatinine clearance was 38 mL/min/1.73 m². She still had normal liver function tests. At her most recent follow up, six years after her initial visit, her serum creatinine was 2.2 mg/dL; BUN 48 mg/dL; calcium 9.4 mg/dL; phosphorus

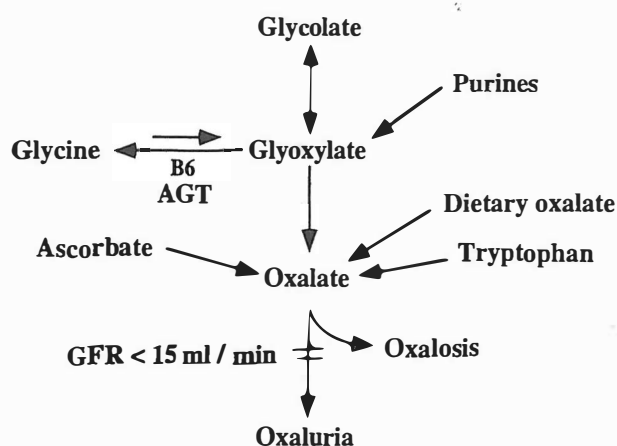
Table II. Secondary hyperoxaluria.

-Increased GI absorption:

- Diet/ascorbic acid
- Small bowel disease (resection/bypass/pathology)
- Chronic pancreatic/biliary tract disease

-Metabolic derangements:

- Ethylene glycol poisoning
- Pyridoxine (B₆) deficiency
- Methoxyflurane anesthesia



Metabolic pathways to oxalate production

Fig. 1. A schematic representation of pathways that lead to oxalate formation. Normally oxalate can be detoxified into glycine by a process of transamination via the enzyme alanine glyoxalate amino-transferase (AGT), with the help of vitamin B₆ (pyridoxine) which functions as a co-factor. Deficiency of AGT in patients with PH1 results in excessive accumulation of glyoxalate which converts to both glycolic acid and oxalic acid resulting in hyperoxaluria and glycolicaciduria. As renal function declines, especially at a GFR <15 mL/min/1.73 m², the kidneys will not be able to excrete adequate amounts of oxalate in urine. This results in oxalate retention and supersaturation of plasma with calcium oxalate, precipitation of calcium oxalate crystals in the tissues, and systemic oxalosis.

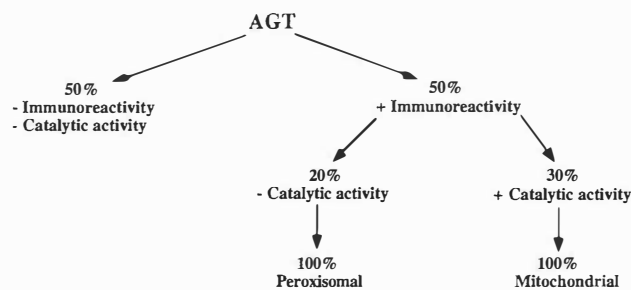


Figure 2

Fig. 2. This figure shows variations in AGT immunoreactivity and enzyme activity in patients with PH1. As described in the text, 50% of the patients show neither immunoreactivity on immunoblots nor enzyme catalytic activity on enzyme assays. The other 50% of the patients show immunoreactivity on the immunoblots indicating the presence of the AGT protein. However, 20% of this group show no catalytic enzyme activity on enzyme assays. In this group, the AGT protein is defective (e.g., abnormal aggregation) and nonfunctional. In the remaining 30% who show protein immunoreactivity on immunoblots and AGT enzyme catalytic activity, on immunohistochemical staining the protein is shown to be localized in the mitochondria rather than in the peroxisomes.

3.6 mg/dL; alkaline phosphatase 60 U/L; and creatinine clearance <30 mL/min/1.73 m². Urine volume was 3,680 mL and her kidneys were 7.3 cm on ultrasound.

Case 2

M.R., a 6 year old boy, was first seen five and one half years earlier. His family history was significant for his parents being cousins. His past medical history revealed significant polyuria and polydypsia since early childhood. He also had a history of pyuria and microscopic hematuria. In his initial visit he was 104 cm high and weighed 15 kg. His physical examination was only significant for a palpable liver edge. He had normal liver function tests. Initial laboratory data revealed a serum creatinine of 0.9 mg/dL; BUN 14 mg/dL; calcium 8.2 mg/dL; phosphorus 5 mg/dL; alkaline phosphatase 29 U/L, and a creatinine clearance of 122 mL/min/1.73 m². Urinalysis revealed an SG of 1.008 with a urine pH of 5.0. 24 hour urine volume was 1500 mL; 24 hour urine calcium was 125 mg; 24 hour urine oxalate was 98 mg. Both plain films of the abdomen and ultrasound of the kidneys revealed bilateral nephrocalcinosis. With the clinical impression of primary hyperoxaluria, the patient was treated with oral orthophosphate and pyridoxine. Two years later, his liver was 4 cm palpable and an ultrasound of the kidneys revealed the right kidney to be 8.1 cm and the left kidney 7.7 cm in size. Four years later, his creatinine clearance was 80 mL/min/1.73 m². An ultrasound of the kidneys revealed bilateral mild cortical atrophy.

Case 3

M.K. was an eight month old boy when he was first seen 4 years ago. His past medical history was significant for fever and dehydration at 35 days of age, which lasted for about one week. His family history was significant for his parents being cousins. He weighed 8.8 kg, and admission laboratory evaluation revealed a serum creatinine of 0.7 mg/dL; BUN 10 mg/dL; calcium 9.7 mg/dL; phosphorus 5.6 mg/dL; and a creatinine clearance of 24 mL/min/1.73 m². Urinalysis urine oxalate was 47 mg. Ultrasound of the kidneys revealed bilateral nephrocalcinosis.

Case 4

M.H., currently a 9 year old boy, was first seen about 2 years earlier. His past medical history is significant for polyuria and polydypsia since early childhood with documented evidence of pyuria and microscopic hematuria. His family history is significant for his parents being cousins. At his first clinic visit at age 7 years old, he weighed 22.0 kg. His initial laboratory evaluation revealed a serum creatinine of 0.75 mg/dL; BUN 14 mg/dL; calcium 9.7 mg/dL; phosphorus 4.8 mg/dL; and alkaline phosphatase 86 U/L. Urinalysis revealed an SG of 1.008 with a urine pH of 5.0. 24 hour urine volume was 2200 mL, 24 hour urine calcium was 190 mg, 24 hour uric acid was 680 mg, and 24

Hyperoxaluria

Table III: Dietary sources of oxalate.

-Vegetables:	celery, beets, eggplant, okra, parsley, green pepper, sweet potato, spinach
-Fruits:	berries, rhubarb
-Beverages:	beer, tea
-Miscellaneous:	chocolate, cocoa, peanut, pecan, soybean

hour urine oxalate was 57 mg. He had normal arterial blood gas values with a pH of 7.4.

DISCUSSION

The diagnosis of hyperoxaluria in our cases were based on the demonstration of excessive amounts of oxalate excretion in 24 hour urine collections. Since urinary excretion of glycolic acid and L-glyceric acid were not quantitated in these patients, we can not be sure of the type of primary hyperoxaluria. However, since PH1 is the most common form of primary hyperoxaluria, these cases are most probably PH1 too. One of the prominent clinical manifestations in our patients was a long history of polyuria and polydypsia and very low urine specific gravity which suggests a defect in urinary concentration mechanisms, possibly due to complicating nephrocalcinosis which was documented in all of our cases with ultrasound studies. Dilute, large urine volumes may have protected our patients from developing recurrent nephrolithiasis which is typically seen in the juvenile form of this disorder.

Management of primary hyperoxaluria^{6,7} includes dietary restriction of oxalate-rich foods (Table III) and restriction of ascorbic acid (vitamin C) intake. The patient should also be placed on a low salt diet since sodium can compete with calcium in binding with dietary oxalate, resulting in a more soluble sodium oxalate salt which will be absorbed in the large bowel. The patient should also receive a regular calcium diet which would bind oxalate in the diet forming insoluble calcium oxalate salt which is excreted in stool. Moreover, the urinary concentration of oxalate should be kept below 40 mg/L (0.4 mmol/L) and the urinary concentration of calcium should be less than 160 mg/L (4 mmol/L). This is to minimize the super-saturation of urine by these two ions which could precipitate as insoluble calcium oxalate salt. To achieve this goal, patients should have >3 liters/1.73 m² of fluid intake. The fluid intake should be distributed evenly throughout the 24 hour period. In order to increase urinary volume, patients can benefit from thiazide diuretics which have the advantage of simultaneously reducing calciuria. However, as kidney function declines to a GFR <25 mL/min, thiazide diuretics

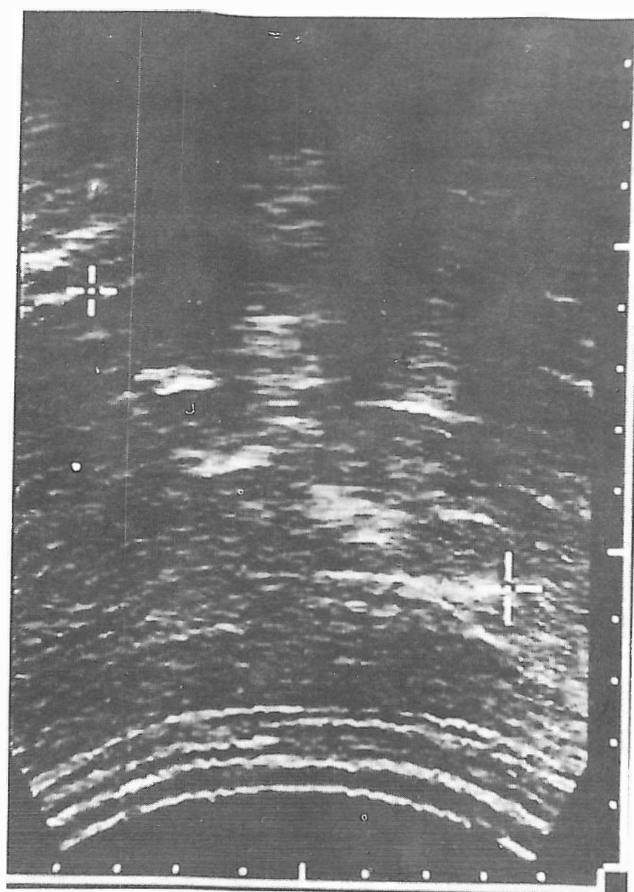


Fig. 3. Ultrasound of the kidney showing multiple areas of calcification in the papillary region suggesting medullary nephrocalcinosis or multiple stones.

may no longer be effective and patients may require loop diuretics which have the disadvantage of increasing calciuria. All patients should receive a trial of pyridoxine (vitamin B₆ at the pharmacologic dose of 300-600 mg/m²/day for a period of 3-6 months), while following serum oxalate levels in patients with advanced renal insufficiency, or 24 hour urine oxalate excretion in patients who have adequate renal function. Approximately 25% of the patients may show some response to this pharmacologic therapy by reducing oxalate generation. These patients may have a genetic defect in their AGT enzyme which reduces its affinity to bind vitamin B₆, a co-factor facilitating transamination (detoxification) of the glyoxalate to glycine. Patients who have maintained significant renal function should also be treated with inhibitors of urinary crystallization which include: sodium citrate 150 mg/kg/day, magnesium hydroxide 300 mg/m²/day and neutral orthophosphate 2 gram/1.73 m²/day.⁶⁻¹⁰

Patients who have reached end stage renal failure should receive maintenance dialysis while awaiting transplantation.^{6,11-14} Hemodialysis has an oxalate clearance rate of 90-120 mL/min/1.73 m², while continuous peritoneal

dialysis has an oxalate clearance rate of 7-8 mL/min/1.73 m². Four hours of hemodialysis has a 33% higher oxalate clearance rate than 48 hours of continuous peritoneal dialysis. However, since patients with primary hyperoxaluria generate very large quantities of oxalate per day (5-10 mg/kg/day), a regular chronic hemodialysis schedule is far insufficient to remove adequate oxalate and result in a negative oxalate balance. In order to achieve a negative balance, the patient should receive daily hemodialysis on an average of 6-8 hours per day, a regimen which is not clinically practical on a long term basis.

Isolated kidney transplantation has been used in patients who have reached end stage renal failure. However, based on the European Dialysis and Transplantation Registry (EDTA) report of 1990, three year renal graft survival has only been 23% for living related donors and 17% for cadaveric kidneys.¹⁵ In their experience, three year patient survival was also unsatisfactory and only 74%. However, the results in the USA have been more promising.¹⁶⁻¹⁸ It has been suggested that in selected patients, particularly those whose primary hyperoxaluria has manifested later in adult life (possibly reflecting a milder form of the disorder), when their GFR is still above 20-30 mL/min/1.73 m², i.e., the total body burden of calcium oxalate is not too much, isolated kidney transplantation may be considered. It has been suggested that these patients receive a living related donor kidney so that they can be vigorously managed before and after transplantation by dialysis to reduce total body stores to calcium oxalate. They should also receive vigorous hydration >3 liters/1.73 m²/day fluid intake, and urinary crystallization inhibitors after transplantation.

With regard to isolated liver transplantation, there is only limited experience with very few patients. At the time of surgery, the patients should undergo native hepatectomy since any residual native liver cells from the patient will continue to synthesize and release large quantities of oxalate. There is no role for auxiliary heterotopic liver transplantation, i.e., leaving the patient's native liver *in situ* and transplanting a cadaveric liver in a different site such as in the pelvic fossa. Not only does the patient's native liver continue to generate large amounts of oxalate but since the native liver—except for deficiency in AGT enzyme—is otherwise perfectly healthy, this will result in disuse atrophy of the transplanted liver. Isolated liver transplantation has been suggested to be used in patients who have significant residual renal function with a GFR ~30-50 mL/min/1.73 m², so that renal function can be preserved when a large body load of calcium oxalate has not accumulated. This mode of therapy should only be considered in patients who show a very aggressive clinical course as manifested by a rapid decline in GFR in the previous year.^{6,19}

Combined liver-kidney transplantation is the standard treatment of choice for these patients.^{5,20-23} This procedure is performed with concomitant removal of the patient's

native liver. For better results, it has been recommended that dual liver-kidney transplantation be performed while there is still residual renal function with a GFR ~20-30 mL/min/1.73 m², and before significant accumulation and expansion of the total body oxalate stores. With this procedure the transplanted liver will stop generating any new oxalate while the transplanted kidney will gradually dispose the oxalate already accumulated in the tissues. The plasma oxalate rapidly declines and reaches normal levels after a few to several months post-transplant. Urinary oxalate excretion rates remain elevated for about 1-2 years depending on the duration of renal failure prior to transplantation and the total body stores of calcium oxalate crystals. With good renal function the calcium oxalate crystals which had precipitated in different tissues are gradually remobilized, enter the plasma, and are excreted by the transplanted kidney. During this period of significant hyperoxaluria post transplantation, the patient should be continued on vigorous oral hydration therapy, as well as inhibitors of urinary crystal formation. More than 60 patients have been treated with this modality and the overall three year patient survival has been ~60%. However, in more recent years there has been significant improvement in outcome, with three year patient survival of 82%, and a three year renal survival, in surviving patients, of 95%.⁶

ACKNOWLEDGEMENT

We would like to thank Ms. Laura Furdek for her secretarial skills in preparing this manuscript.

REFERENCES

1. Morgan SH: The primary hyperoxalurias. In: Cameron S, Davison AM, Grunfeld JP, Kerr D, and Ritz E, (eds.), Oxford Textbook of Clinical Nephrology. New York: Oxford University Press, pp. 2226-2230, 1992.
2. Danpure CJ: Molecular and clinical heterogeneity in primary hyperoxaluria type I. Am J Kid Dis 17: 366-369, 1991.
3. Watts RWE: Primary hyperoxaluria type I. QJ Med 87: 593-600, 1994.
4. Danpure CJ, Jennings PR, Fryer P, Purdue PE, Allsop J: Primary hyperoxaluria type 1: genotypic and phenotypic heterogeneity. J Inher Metab Dis 17: 487-499, 1994.
5. Danpure CJ: Molecular and cell biology of primary hyperoxaluria type 1. Clin Investig 72: 725-727, 1994.
6. Cochat P, Deloraine A, Olive F, Rolland MO, Gillet Y, Divry P, Scharer K: Primary hyperoxaluria type 1: the therapeutic dilemma. Advances in Nephrology 24: 227-242, 1995.
7. Broyer M, Jouvet P, Niaudet P, Daudon M, Revillon Y: Management of oxalosis. Kidney Intl 49: S53: S93-S98, 1996.

Hyperoxaluria

8. Morgan SH, Maher ER, Purkiss P, Watts RWE, Curtis JR: Oxalate metabolism in end stage renal disease: the effect of ascorbic acid and pyridoxine. *Nephrol Dial Transplant* 3: 28-32, 1988.
9. Leumann E, Hoppe B, Neuhaus T: Management of primary hyperoxaluria: efficacy of oral citrate administration. *Pediatr Nephrol* 7: 207-211, 1993.
10. Milliner DS, Eickholt JT, Bergstralh EJ, Wilson DM, Smith LH: Results of long-term treatment with orthophosphate and pyridoxine in patient with primary hyperoxaluria. *N Engl J Med* 331: 1553-1558, 1994.
11. Maggiore Q, Poggi A, Parlongo S, Cerrai T: Oxalate removal by dialysis and haemoperfusion. *Proc EDTA* 16: 717-718, 1979.
12. Watts RWE, Veall N, Purkiss P: Oxalate dynamics and removal rates during haemodialysis and peritoneal dialysis in patients with primary hyperoxaluria and severe renal failure. *Clinical Sciences* 66: 591-597, 1984.
13. Ahmad S, Hatch M: Hyperoxalemia in renal failure and the role of hemoperfusion and hemodialysis in primary oxalosis. *Nephron* 41: 235-240, 1985.
14. Marangella M, Petrarulo M, Cosseddu D, Vitale C, Linair F: Oxalate balance studies in patients on hemodialysis for type 1 primary hyperoxaluria. *Am J Kidney Dis* 19: 546-553, 1992.
15. Broyer M, Brunner FP, Brynner H, Dykes SR, Ehrich JHH: Kidney transplantation in primary oxalosis: data from the EDTA registry. *Nephrol Dial Transplant* 5: 332-336, 1990.
16. Scheinman JI, Najarian JS, Mauer SM: Successful strategies for renal transplantation in primary oxalosis. *Kidney Int* 25: 804-811, 1984.
17. Whelchel JD, Alison DV, Luke RG, Curtis J, Diethelm AG: Successful renal transplantation in hyperoxaluria. *Transplantation* 35: 161-164, 1983.
18. Katz A, Freese D, Danpure CJ, Scheinman JI, Mauer SM: Success of kidney transplantation in oxalosis is unrelated to residual hepatic enzyme activity. *Kidney Int* 42: 1408-1411, 1992.
19. Cochat P, Scharer K: Should liver transplantation be performed before advanced renal insufficiency in primary hyperoxaluria type 1? *Pediatr Nephrol* 7: 212-218, 1993.
20. Watts RWE, Morgan SH, Danpure CJ, Purkiss P, Calen RY, Rolles K, Baker LRI, Mansell MA, Merion RM, Smith LH, Lucey MR: Combined hepatic and renal transplantation in primary hyperoxaluria type 1: clinical report of nine cases. *Am J Med* 90: 179-188, 1991.
21. Lloveras JJ, Durand D, Dupre C, Rischman P, Fourtanier G, That HT, Suc JM: Combined liver-kidney transplantation in primary hyperoxaluria type 1. Prevention of the recidive of calcium oxalate deposits in the renal graft. *Clinical Nephrology* 38: 128-131, 1992.
22. Janssen F, Hall M, Schurmans T, DePauw L, Hooghe L, Gelin M, Goyens P, Kinnaert P: Combined liver and kidney transplantation in primary hyperoxaluria type 1 in children. *Transplantation Proceedings* 26: 110-111, 1994.
23. Toussaint C, Vienne A, DePauw L, Gelin M, Janssen F, Hall M, Schurmans T, Pasteels JL: Combined liver-kidney transplantation in primary hyperoxaluria type 1. *Transplantation* 59: 1700-1704, 1995.