

A COMPARISON OF CORONARY ANGIOGRAPHY RESULTS IN PATIENTS WITH STABLE AND UNSTABLE ANGINA PECTORIS

S. H. AREFI, M.D., AND F. EMAMI, M.D.

From the Department of Cardiology, Tehran University of Medical Sciences, Tehran, Islamic Republic of Iran.

ABSTRACT

To study the newly mentioned significance of the obstructive lesion morphology in coronary artery disease (CAD), a study has been designed to compare this feature between patients having stable angina (SA) or unstable angina (UA) who underwent coronary angiography in Tehran Heart Institute.

Study objectives were detection of the angina producing artery (APA) and its morphologic lesion type, detection of the number of diseased vessels, determining the left ventricular ejection fraction (LVEF) and end-diastolic pressure (LVEDP), and comparing these findings between the two patient groups.

The study population consisted of 205 patients, 141 with SA and 64 with UA, who underwent standard coronary angiography. Lesion types were divided to type I, concentric lesions; type IIA, eccentric broad neck lesions; type IIB, eccentric narrow base lesions; and type III, multiple lesions.

There was no difference in LVEF or LVEDP in the two angina group patients. In the SA group the APA lesion was type I in 25%, type IIA in 39%, type IIB in 9%, and type III in 27% of patients, while these figures were 9.3%, 5.6%, 31.5% and 53.7% respectively in the UA group. The APA in the SA group was the left main stem in 5.7%, the left anterior descending in 41.8% the left circumflex in 14.2%, the right coronary artery in 14.2%, and neither of these vessels in 29.1%. For the UA group, these figures were 0.54%, 21.9%, 14.1%, and 9.9%, respectively.

Review of these results reveals that although there was no quantitative difference between the two groups, the qualitative lesion type differences were significant, a finding in accordance with some theories that focus on atherosclerotic plaque rupture as the etiology of UA.

Keywords: Angina, stable, unstable; angiography, coronary.

MJIRI, Vol. 11, No. 3, 197-201, 1997.

INTRODUCTION

The morphologic study of obstructive lesions in coronary arteries is a relatively new field. 230 patients known to have stable (SA) or unstable angina (UA) underwent coronary artery catheterization and angiography in Tehran Heart Institute (Shariati Hospital). The principle goal was to

compare the angiographic findings between SA and UA patients. The objectives of the study were to detect the "angina-producing" vessels to determine the morphologic types of the lesions in each group, to determine the number of the diseased and/or totally occluded vessels and the "dominant" vessel, to compare the left ventricular ejection fraction (LVEF) and left ventricular end diastolic pressure

Coronary Angiography in Angina Pectoris

(LVEDP) between the two groups, and to determine the relationship between coronary stenosis and the risk factors for coronary artery disease (CAD).

MATERIAL AND METHODS

We prospectively reviewed the histories and angiograms of the patients who were referred to the cath-lab for evaluation of their angina pectoris. The histories were obtained before catheterization. To minimize errors, the images of the "angina producing" arteries were reviewed by an experienced cardiologist who was totally unaware of the patients' histories.

The exclusion criteria were concomitant congenital or valvular heart disease, reasons other than angina pectoris for angiography, and the presence of vague symptoms as the sole manifestation of CAD not classifiable as SA or UA.

Patients were categorized as having SA if they manifested one of the following: 1) typical exertional angina (class I or II) relieved by rest or nitroglycerin with stable symptoms, 2) slowly progressive exertional angina (increasing by less than two in the Canadian Heart Classification) with no pain at rest, or severe SA (class III) or angina at rest (class IV) of less than two months' duration, 3) crescendo angina defined as an abrupt increase in pain (more than two in the Canadian Heart Classification) within the two months prior to catheterization or in a patient with previous SA, 4) recent (less than 4 weeks) well-documented subendocardial or transmural infarction, and 5) recurrent anginal pain at rest in a hospital setting with no enzymatic evidence or angiography. 205 patients entered the study and were categorized into SA (141 patients) and UA (64 patients), irrespective of coronary artery anatomy.

The femoral artery was the route of entry in all catheterizations and standard catheters and techniques were used. LVEDP was measured before dye injection (after wave "a") and was followed by left ventriculography in right and left anterior oblique projections. Each coronary artery was selectively viewed in at least two projections.

Coronary lesions were morphologically classified by an experienced cardiologist into the following categories³ (Fig 1):

I. Concentric stenosis: symmetric narrowing of the artery. The borders of the lesion were smooth and only slightly irregular.

II. Eccentric stenosis: asymmetric narrowing of the artery. Two subgroups were defined; type II (A) eccentric lesion: any asymmetric stenosis with smooth borders and a broad neck, and type II (B) eccentric lesion: an asymmetric stenosis, usually in the form of a convex intraluminal obstruction with a narrow base or neck due to one or more over-hanging edges or borders that were very irregular or scalloped.

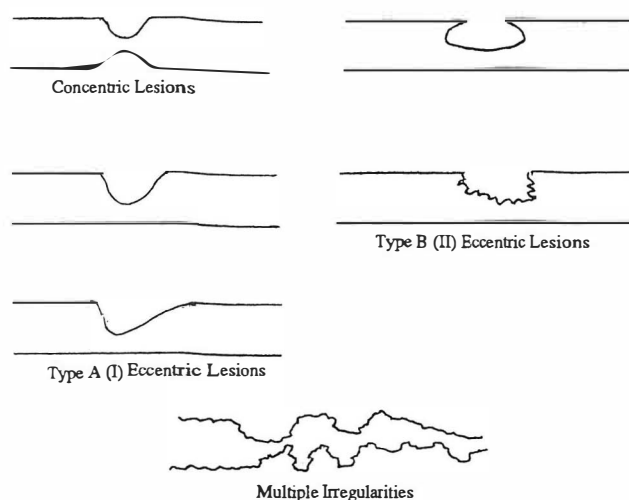


Fig. 1. Schematic drawing of the different configurations of coronary stenotic lesions.

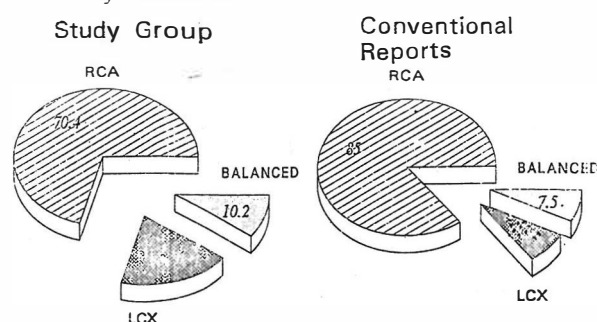


Fig. 2. Vessel dominance in the study group in THI and conventional reports.

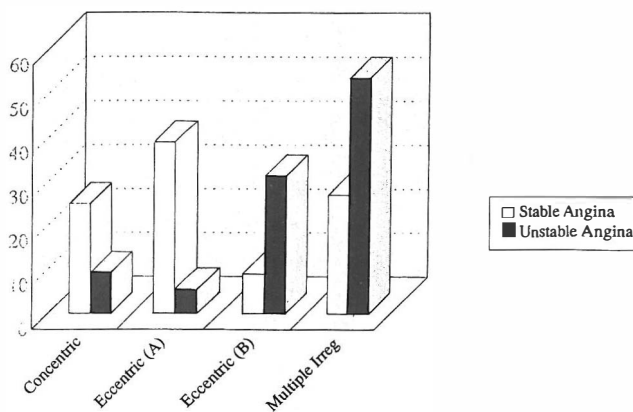


Fig. 3. Correlation between angina type and stenosis morphology.

III. Multiple irregularities: three or more closely-spaced obstructive lesions in a coronary artery. This group also included arteries with severe diffuse irregularities or arteries in which the segment between two severe obstructive lesions also exhibited significant diffuse luminal irregularities (Fig. 1).

In all cases, an attempt was made to localize the artery responsible for the anginal syndrome, and characterize its morphology. This was done as follows:

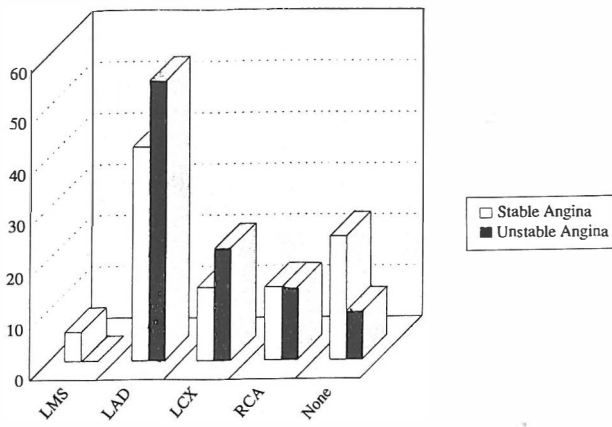


Fig. 4. Correlation between angina type and culprit artery.

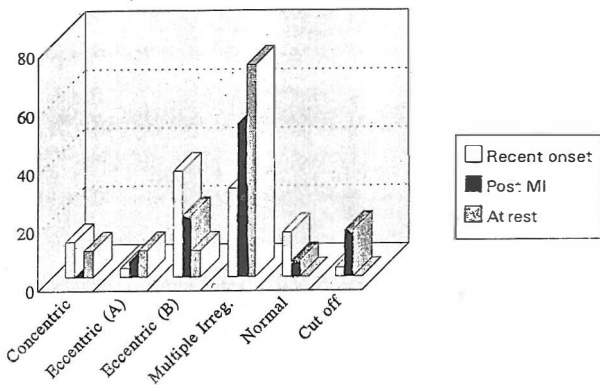


Fig. 5. Correlation between unstable angina type and type of lesion.

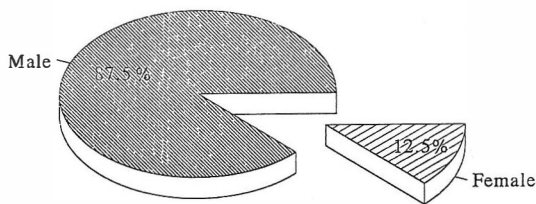


Fig. 6. Sex distribution of patients with LMS lesions.

1. In patients with one-vessel disease, this vessel was identified as the "angina-producing" artery (A.P.A).
2. An "angina-producing" artery (APA) was identified in patients with multivessel disease by one of the following criteria:
 - a) In case of any focal ECG abnormalities, the supplying artery to the area was considered as the APA.
 - b) If criterion (a) failed to determine APA, the APA was identified in ventriculography as the artery supplying a hypo-, dys-, or akinetic region.
 - c) In case all the above criteria failed, the most severely obstructed artery was arbitrarily considered as the APA.
3. The totally cut-off vessel was considered as APA only

if, first, it showed retrograde filling, and second, if the other two vessels had not met the above-mentioned criteria for APA.

Hypertension was defined as BP>140/90 in two successive measurements four weeks apart. Hyperlipidemia was defined as triglyceride or cholesterol levels greater than 200 mg/dL in at least one measurement.

The patient was considered as a "smoker" if he had been smoking during the three-year period prior to angiography, and a "non-smoker" if he had quit smoking at least 3 years before angiography. Likewise, patients were considered as having diabetes mellitus if they met one of the following criteria: a) an elevated fasting blood sugar on more than one occasion (venous plasma glucose >140 mg/dL), and b) a fasting plasma glucose of less than 140mg/dL with a sustained high plasma glucose concentration during the oral glucose tolerance test (OGTT) on more than one occasion.

In each patient the "dominant vessel" was considered to be the one giving off the posterior descending artery (PDA) and posterior left ventricular (PLV) branches. If the RCA had given rise to the PDA but the left circumflex artery had given off the PLV branches, balanced dominance was considered to be present.

RESULTS

230 patients underwent coronary angiography, and 25 of them were excluded from the study because of either the presence of vague symptoms or failure to demonstrate the APA. Of the 205 patients entering the study, 141 had SA and 64 had UA. Male to female ratio was similar in both groups. The mean age of the patients in both groups was 55. LVEF and LVEDP for both groups were also similar (LVEF=40±11, LVEDP=12±7 mmHg). The average number of diseased vessels was 2.07±1.17 for the SA group and 3.03±1.00 for the UA group. The average number of totally cut-off vessels in both groups was 1.2±0.5. 10.4% of patients were RCA-dominant, 18.9% were LCA-dominant and 10.2% had balanced dominance (Fig. 2). Risk factors were not significantly different between the two groups.

Excluding the cases with normal or totally cut-off coronary arteries, the patients were classified based on the morphology of the obstructive lesions in the APA. As shown in Fig. 1, in the SA group, 25% of patients had concentric lesions, 39% had eccentric type IIA, 9% had eccentric type IIB and 27% had multiple-irregularity lesions. These percentages were 9.3%, 5.6%, 31.5% and 53.5%, respectively, for the UA group (Fig. 3). In the SA group 64% of the lesions were concentric or of the IIA type. A normal angiogram was present in 24% of SA patients and 9.4% of UA patients (19.5% total).

The distribution of APA in the SA group was as follows: left main stem (LMS): 5.7%; left anterior descending (LAD):

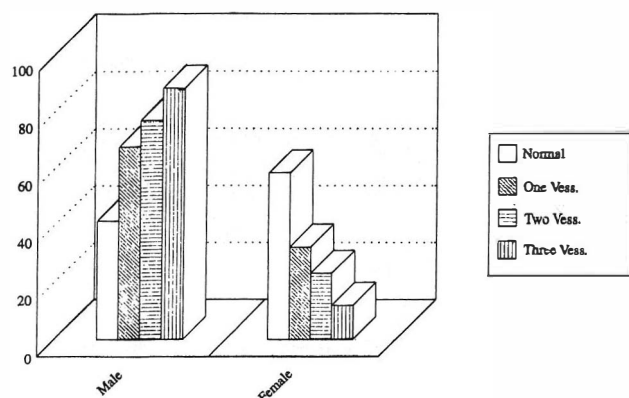


Fig. 7. Correlation between number of diseased vessels and sex.

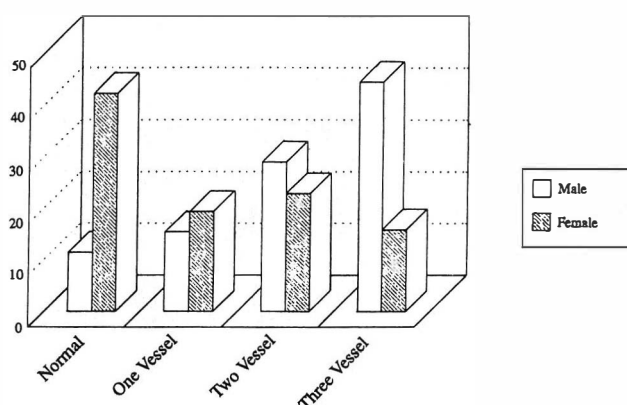


Fig. 8. Correlation between sex and number of diseased vessels.

41.8%; left circumflex (LCX): 14.2%; right coronary (RCA): 14.2%; none: 24.1% In the UA group, these rates were 0.54% 21.9%, 14.1% and 9.4%, respectively (Fig. 4).

In the UA group, 33 patients had angina of recent onset, 19 patients had post-MI angina and 12 patients had angina at rest. In the post-MI group, the number of patients having concentric lesions, class IIA lesions, or normal angiography was 0, 1, and 1, respectively (total 5.3%). In this group 52.6% of the patients had multiple-irregularity lesions. No normal angiogram was seen in the angina-at-rest group (Fig. 5). Of the patients with normal angiography, 83% were non-smokers and 95% were non-diabetic.

Of the 8 patients with LMS lesions, 7 patients (87.5%) were male and one patient (12.5%) was female (Fig. 6).

The occurrence rates of normal angiograms, one-vessel disease (1VD), two-vessel disease (2VD) and three-vessel disease (3VD) among male patients were 11.4%, 15.4%, 28.9% and 44.3%, respectively. Among females, the rates were 42.1%, 19.3%, 22.8%, and 15.8%, respectively. 88% of patients with 3VD were male and 12% were female. 76.8% of the patients with 2VD were male and 23.2% were female (Figs. 7,8). In the 1VD group 67.6% were male and

32.4% were female, and among those with normal angiograms 41.5% were male and 58.5% were female.

As mentioned earlier, no significant quantitative difference was seen between the SA and UA groups (i.e., the number of diseased vessels, the number of totally cut-off vessels, LVEF, and LVEDP), whereas the qualitative results were significantly different.

In the SA group, 36% of lesions were of the eccentric or multiple-irregularity type. This was 85% in the UA group. In both groups the most commonly seen diseased vessel was the LAD, but normal angiographies were more frequently seen in the SA rather than the UA group (24.1% vs 9.4%). Age and sex distribution as well as the distribution of CAD risk factors were not significantly different between the SA and UA groups.

DISCUSSION

Analysis of anatomical findings in SA and UA patients led us to the conclusion that these two groups were similar in regard to the distribution of coronary lesions and quantitative variables (e.g. the number of diseased vessels). Qualitative differences in the morphology of coronary stenoses, however, were significant between the two groups. In the UA patients, 85% of the APA's were of the IIB type (eccentric type B), while this was only 36% in the SA patients.

The significance of these different morphologies is unknown. According to Levin and Fallon,⁴ stenoses with irregular borders often represent plaque rupture or partially occlusive thrombi. Therefore, it is not unreasonable to postulate that a type II eccentric lesion or a multiple-irregularity lesion might represent a ruptured atherosclerotic plaque. Rupture of a plaque could then account for the acute progression of CAD in these patients.⁵ It is also possible that partially occlusive intraluminal thrombi could explain the angiographic appearance of most type B eccentric or multiple-irregularity lesions.

In our study, the occurrence rates of concentric, type IIA, type IIB and multiple-irregularity lesions in SA patients were 25%, 39%, 9%, and 27%, respectively (48%, 32%, 16%, and 4%, respectively, in Ambrose et al's study).³

Obviously, multiple-irregularity lesions occurred more commonly in our study as compared with other studies. This may be due to various factors (such as nutritional status, physical activity, and psychological stress) that may possibly affect Iranian people, and may in turn account for the relatively low occurrence rates of concentric lesions in our cases (as compared with those in Ambrose et al's study). This difference necessitates different therapeutic approaches in Iranian patients, especially in regard to the PTCA results. "Dominancy" rates were also different in our study as compared with those given in the literature, which may be

due to anatomical variations in Iranian patients.

The severity of symptoms in UA is halfway between SA and myocardial infarction. The risk of a subsequent coronary artery event is higher in UA than in SA, though the highest risk appears to be during the immediate period after a change in symptoms.⁶ Detection of these at-risk patients and application of appropriate therapeutic measures is of utmost importance.

Type B eccentric, or multiple-irregularity lesions are common angiographic findings in the majority of patients with UA. It is suspected that these lesions are caused by ruptured plaques or partially occlusive thrombi or both, which acutely compromise the coronary circulation and play an important role as the source of UA.

It may be prudent, however, to administer anticoagulants to all patients with UA, using either antiplatelet or heparin-like agents, because most of these patients will have type B eccentric or multiple-irregularity lesions.⁶

REFERENCES

1. Rutherford JD, Braunwald E: Chronic ischemic heart disease. In: Braunwald E, (ed.), *Heart Disease*. 4th ed., Philadelphia: W.B. Saunders, pp. 1292-1364, 1992.
2. Braunwald E: Unstable angina, a classification. *Circulation* 80: 410, 1989.
3. Ambrose JA, Winters SI, Stern A, et al: Angiographic morphology and the pathogenesis of unstable angina. *J Am Coll Cardiol* 5: 609, 1985.
4. Levin DC, Fallon JT: Significance of angiographic morphology of localized coronary stenosis: histopathological correlations. *Circulation* 66: 316, 1982.
5. Falk E: Morphologic features of unstable atheroembolic plaques. *Am J Cardiol* 63: 114E, 1989.
6. Davies MH: Thrombosis and acute coronary artery lesion. *N Engl J Med* 310: 1137, 1984.

