

MENKES' SYNDROME: REPORT OF A CASE

SEYYED MOHAMMAD RAFIEI, M.D.,
AND SIROOS ZODJAJI, M.D.*

*From the Departments of Pediatrics and *Radiology, Shiraz University of Medical Sciences, Shiraz,
Islamic Republic of Iran.*

ABSTRACT

An 8 month old boy is presented with clinical and laboratory features of Menkes' kinky hair syndrome. A brief discussion ensues.

Keywords: Menkes' syndrome, copper (Cu)

MJIRI, Vol. 11, No. 3, 245-248, 1997.

INTRODUCTION

Menkes' kinky hair disease, also known as trichopoliodystrophy, X-linked copper deficiency, and steely hair disease (with similar hair changes, seen in copper-deficient sheep), was first described in 1962 by Menkes and associates.^{1,2} Due to lack of a certain cellular carrier protein(s), caused by a mutation at a specific gene locus on chromosome X—presently narrowed to X.q.13.3(4)—copper is not delivered to various copper containing enzymes, subserving various systemic and neurological functions, resulting in a progressively fatal neurodegenerative disease. Major manifestations of this disease include abnormal hair, abnormal facies, progressive cerebral degeneration, bone changes, arterial rupture and thrombosis, and hypothermia^{2,3} (Table I). Occipital horn syndrome (also known as X-linked cutis laxa, and X-linked Ehlers-Danlos type IX), is a closely related disease presenting with inguinal hernias, chronic diarrhea, bladder and ureteric diverticula, and skin and joint laxity. Ossified and palpable occipital horns with milder changes in serum copper and ceruloplasmin distinguish this disease from the classical Menkes' disease.² Milder forms of Menkes' disease, presenting later in life, have also been described.²

We report an 8 month old boy fulfilling most of the above clinical stigmata for Menkes' disease.

Case report

An 8 month old boy from Yaşooj was referred to the Pediatric Neurology Ward with refractory upper extremity, eye, and body jerks noted since 5 months of age. He was born by normal vaginal delivery after a full term pregnancy at the hospital. Pregnancy was only complicated by vaginal

spotting in the first trimester. He cried somewhat later than normal at birth, and a brief resuscitation was needed. Shortly after birth his serum bilirubin rose up to 11.38 mg/dL with a direct level of 1.64 mg/dL, for which no therapy

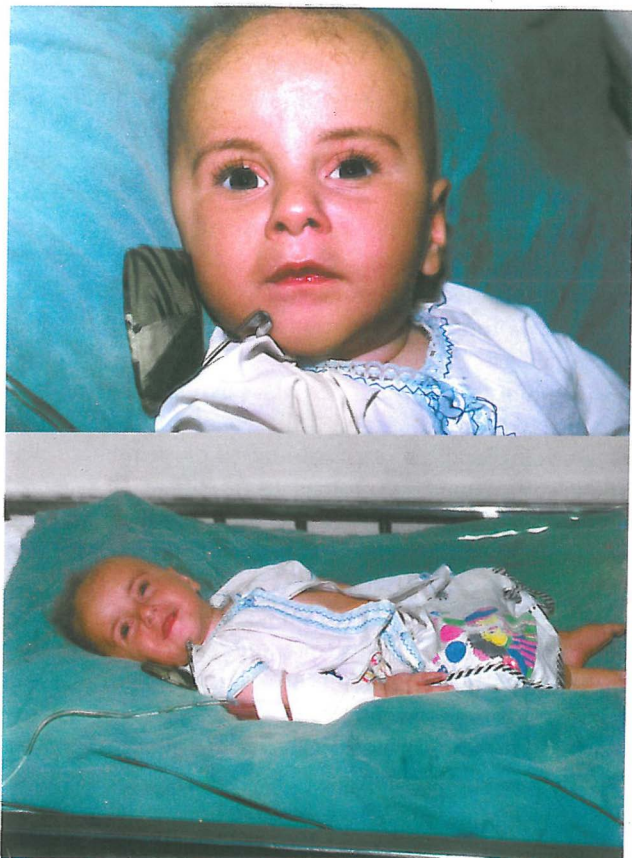


Fig. 1. The patient demonstrating hair and facial features of the disease.

Menkes' Syndrome

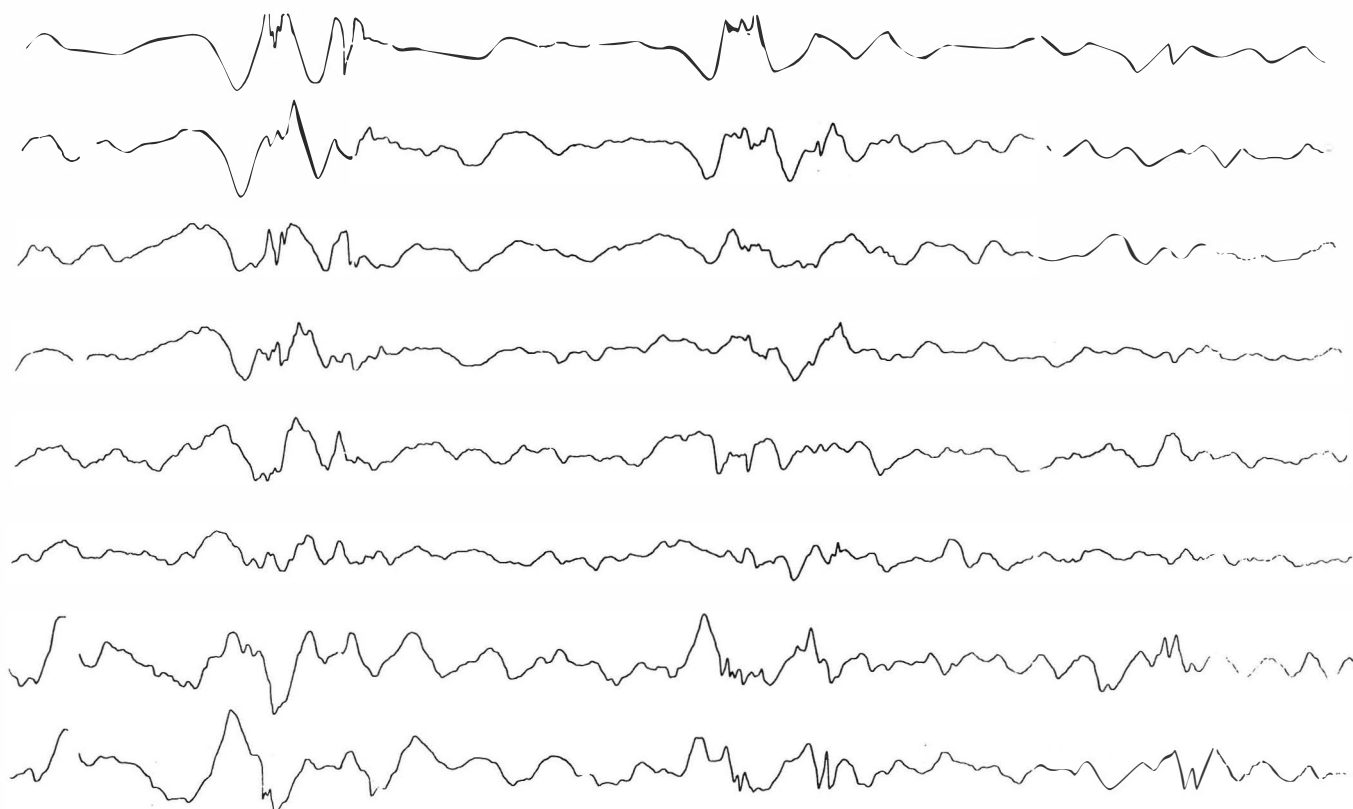


Fig. 2. The patient's EEG.

was offered. Postnatally, he was hospitalized for what was presumed as "sepsis" and was treated accordingly and discharged. Since 5 months of age he started to have episodes of brief (several seconds up to 1 min.) increase in body tone with flexion of the head and body, upward eye deviation, drooling, and lip cyanosis. Upon referral to a pediatrician in Yasooj he received subsequent courses of phenobarbital and phenytoin with no effect. He was noted to be hypotonic and inattentive to his parents and surroundings.

Nonconsanguineous parents gave a history of 2 miscarriages at the second trimester of each of the two pregnancies, and no other sibling or close relative was known to have the same problem as the patient. He received his vaccinations as routine. Before 8 months of age he could not hold his neck or roll over, and did not pay any attention to his parents or any other visual or auditory stimuli.

On physical exam he was found to be hypotonic with a certain facies (Fig. 1.). Head circumference= 41 cm (<2 SD for age); chest circumference= 41 cm; length= 64 cm (about 5% for age); weight= 7 kg (about 5% for age); body temperature ranged from 36°C in the mornings to 37.5°C in the afternoons. Anterior fontanelle= 1.5×1 cm, not bulged; posterior fontanelle, closed. Positive findings were global hypotonia with preserved deep tendon reflexes, a bony prominence at the right parietal area of the head, total inattention to visual or auditory stimuli, crying only for

hunger, kinked, blond hair, bilaterally positive Babinski sign, and no organomegaly. Paraclinical work-up revealed the following abnormalities:

1. EEG: slow background, periods of relatively higher voltage sharp waves followed by slowing (pseudoperiodic pattern?) (Fig. 2).
 2. Brain CT: bilateral temporo-occipital, and to a lesser degree, frontal cortical and white matter atrophy (Fig. 3).
 3. Skull series: increase in right parietal bone outer table thickness—possible previous subperiosteal hematoma (Fig. 4).
 4. Serum ceruloplasmin level: 0.052 g/dL (normal: 0.233-0.402 g/L).
 5. Serum copper (Cu) level: 12.4 µg/dL (normal: 70-150 µg/dL).
 6. Pili torti: the patient's hair was fragile, several shafts always found shed on his bed mattress on daily hospital rounds, and under low power light microscopy was twisted at several millimeter intervals. Due to excess shedding of hair the patient had a sparse hair population on his head.
- The patient did not show hyperelasticity, joint hypermobility, easy bruisability, or paper-thin scars on his skin.
7. Long bone X-ray (Fig. 5): curving and decreased density of the shaft.
 8. A near 10 cm diverticulum at the postero-superior aspect of the bladder. Other biochemical tests were

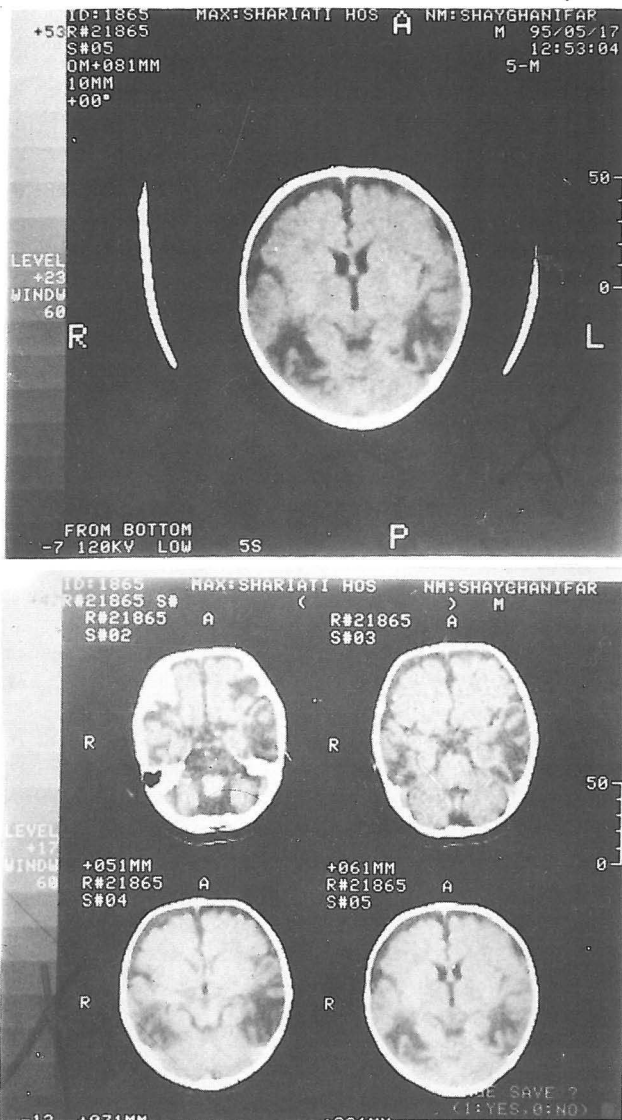


Fig. 3. Brain CT.

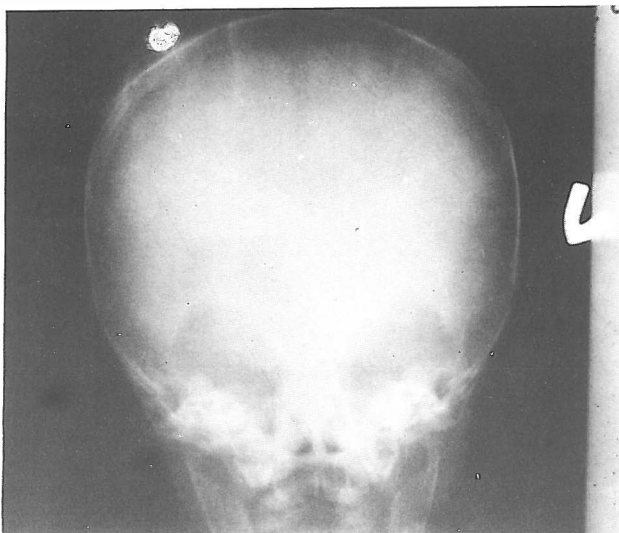


Fig. 4. Skull X-ray, AP view.

Table I. Clinical and paraclinical features of Menkes' disease^{1,2,4,8}

- Hx of premature delivery, neonatal hypothermia and hyperbilirubinemia frequently elicited
- Hypothermia, poor feeding, poor weight gain, seizures, hypotonia, progressive deterioration of all neurologic functions
- Cherubic facies, depressed nasal bridge, pale optic discs, retinal degeneration, emphysema, iris cysts, gastric hemorrhage, subdural hematoma, colorless, friable, twisted hair (pili torti)
- Trichorrhexis nodosa (fracture of hair shaft at regular intervals)
- Very low serum copper and ceruloplasmin levels
- Decreased liver and brain Cu/increased intestinal mucosal copper
- Reduced activity of cytochrome oxidase, superoxide dismutase, tyrosinase, dopamine beta-hydroxylase, lysyl oxidase
- Poor Cu absorption/I.V. and subcutaneous Cu → serum Cu and ceruloplasmin increase
- Urinary tract dilation/bladder diverticula → rupture or U.T.I.
- X-ray: progressive osteoporosis, flared anterior ribs, periosteal reaction, increased density of provisional zone of calcification, small mandible, scalloping of posterior surface of the vertebral bodies; differential Dx. of bone changes, child abuse and scurvy
- Brain CT: macroscopic changes of brain degeneration
- Angiography: elongated, tortuous arteries in the cerebral and systemic vascular system with variable narrowing and dilatation and increased branching points
- Death: usually between 3 months-3 years (most often at 12 months).

unremarkable. More elaborate biochemical tests⁷ were not feasible. Angiography was not performed.

In his 2 hospital admissions and outpatient follow-up,

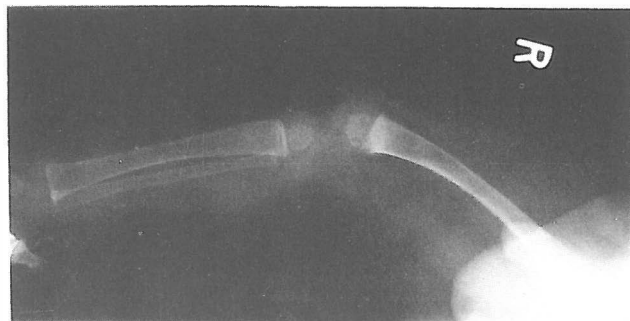

Fig. 5. Long bone X-ray.

the patient had not responded to subsequent trials of phenobarbital, phenytoin, prednisolone, clonazepam, vitamin B₆, vigabatrin, and carbamazepine, almost all the anti-convulsants available in our region. No parenteral copper was available in Iran for a trial of therapy and his seizures have remained intractable, although his general condition is fairly stable, except for some irritability and excessive crying.

DISCUSSION

This infant represents a typical case of Menkes' kinky hair disease. He manifested hyperbilirubinemia shortly postnatally, a sepsis-like episode at early infancy, and neural, urinary, hair, bone, and biochemical changes peculiar to this disease. His seizures have resisted any available anti-convulsant therapy. Various parenteral copper compounds have been tried in animal models⁶ and affected humans^{2,5} with resultant enzymatic and some clinical recovery. Thus far efforts to find a parenteral form of copper have failed, as have all drug trials to bring the patient's seizures under control. Our case demonstrates the importance of looking for a systemic disease whenever an infant or child presents primarily with neurological signs and symptoms.

REFERENCES

1. Menkes JH, et al: A sex-linked recessive disorder with growth retardation, peculiar hair, and focal cerebral and cerebellar degeneration. *Pediatrics* 29: 764, 1962.
2. Danks DM: Disorders of Copper Transport. In: Scriver CR, et al. (eds.). *The Metabolic Basis of Inherited Disease*. 7th edition, New York: McGraw-Hill (International Edition), pp. 2211-2231, 1995.
3. Kaler SG, et al: Gastrointestinal hemorrhage associated with gastric polyps in Menkes' disease. *Journal of Pediatrics* 122 (1): 93-5, 1993.
4. Horn N, Tonnesen T, Tumer Z: Menkes' disease: an X-linked recessive disturbance of copper metabolism. *Brain Pathology* 2(4): 351-62, 1992.
5. Sarkar B, Lingertat-Walsh K, Klarke JT: Copper-histidine therapy for Menkes' disease. *Journal of Pediatrics* 123 (5): 828-30, 1993.
6. Kreuder J, et al: Clinical and biochemical consequences of copper-histidine therapy in Menkes' disease. *European Journal of Pediatrics* 152 (10): 828-32, 1993.
7. Kaler SG, et al: Plasma and cerebrospinal fluid neurochemical pattern in Menkes' disease. *Annals of Neurology* 33 (2): 171-5, 1993.
8. Menkes JH: Metabolic Diseases of the Nervous System. In: Menkes JH, (ed.), *Textbook of Child Neurology*. Fourth Edition, Philadelphia: Lea & Febiger, pp. 121-122, 1991.
9. Herman TE, McAlister WH: Inherited diseases of bone density in children. *Radiologic Clinics of North America* 29 (1): 152-153, 1991.