

THYROGLOSSAL DUCT CYST PRESENTING AS ENDOLARYNGEAL MASS

N. MOKHTARI, M.D.,
A. TABATABAI,* M.D. AND R. ABDI,** M.D.

*From the Department of Otolaryngology, Head and Neck Surgery, Mashhad University of Medical Sciences, Mashhad, the * Department of Pathology, Ghaem Hospital, Mashhad, and the **Department of Radiology, Mazandaran University of Medical Sciences, Sari, Islamic Republic of Iran.*

ABSTRACT

Thyroglossal duct cyst is a well-known congenital entity, and its embryonic development and clinical presentation are well understood. Very little can be added to the classic material found in the world literature. Rare cases of unusual clinical presentation have also been reported. Our case of endolaryngeal thyroglossal duct cyst is reported because of its unique endolaryngeal presentation, having no characteristic external cystic mass. This case is reported along with its CT and FVL studies and pathological slides.

MJIRI, Vol. 11, No. 3, 251-254, 1997.

Case report

The patient is a 41 year old male who presented to us with a 6-8 month history of shortness of breath and a change in his voice. His shortness of breath had caused him to reduce his activities. His voice change was noticed by his relatives and friends. His physical exam was impressive

because of an endolaryngeal mass seen at indirect laryngoscopy. This was an ovoid mass covered by normal mucosa located on the left side of the laryngeal vestibule. It partly encroached on the medial aspect of the left pyriform sinus and onto the midline of the endolaryngeal space, obscuring the rima glottis. A small space remained in the

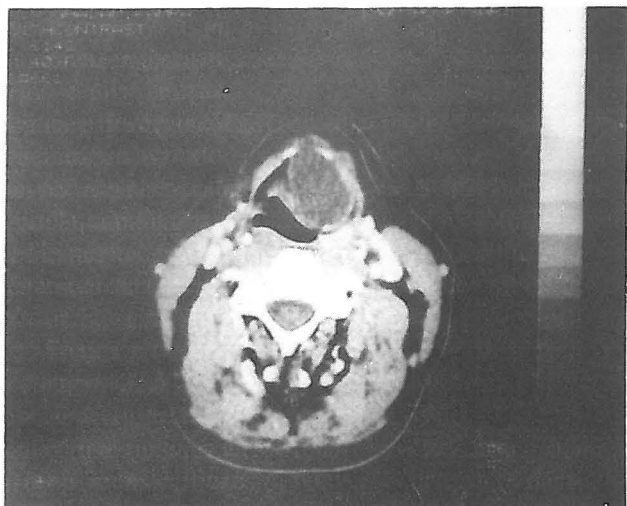


Fig. 1. CT scan of larynx; axial section, showing encroachment of cyst on the airway.

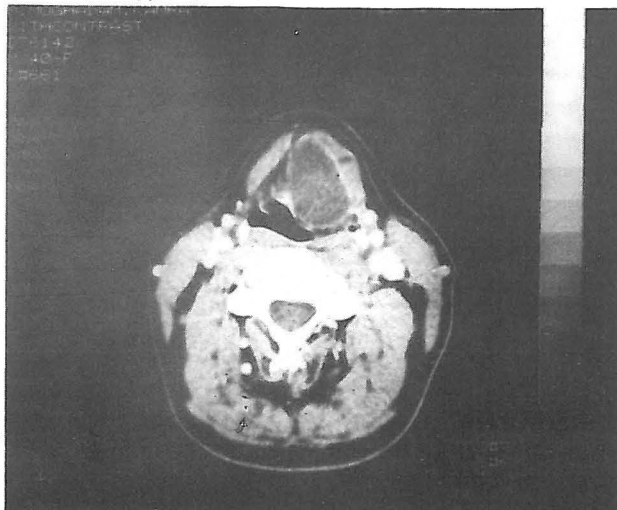

Fig. 2. CT scan of larynx; axial section showing the exact endolaryngeal localization.

Endolaryngeal Thyroglossal Duct Cyst



Fig. 3. CT scan of larynx; reconstruction showing the thinned-down thyroid cartilage.

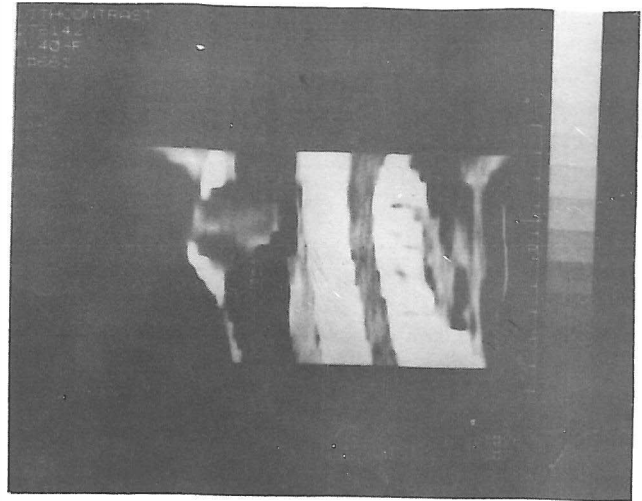


Fig. 4. CT scan of larynx; reconstruction showing the anterior attachment.

larynx for air passage. The thyrohyoid membrane showed minimal fullness only on deep palpation. The thyroid gland was normal. There was no fistula, fistula tract, or cyst in his cervical examination.

CT scan (Figs. 1-4) confirmed an endolaryngeal cystic mass immediately behind the thyrohyoid membrane and thyroid cartilage, the latter being thinned down by the pressure of a nearby, gradually enlarging cyst. The cyst was not enhanced. Densitometry was performed and confirmed the presence of noninflammatory fluid. The amount of laryngeal obstruction, as well as the size of the cyst and its true location, were thoroughly studied by the reconstruction of CT cuts.

Flow volume loop (FVL) and pulmonary function tests confirmed the reduction of inspiratory flow and overall PFT's to be on the lower limit of prediction (Fig. 5).

The patient's surgical treatment included an orderly tracheotomy under local anesthesia, general anesthesia via tracheotomy tube, and total extirpation of the cyst via external approach. The cyst was removed through the thyrohyoid membrane without disturbing normal endolaryngeal mucosa. The pedicle was ligated behind the hyoid bone. The patient had an uneventful recovery. His tracheotomy tube was removed after five days. His postoperative voice and respiration were adequate.

Surgical pathology slides (Fig. 6) reveal the thin-walled cyst. There was respiratory and areas of focal squamous epithelium and multiple areas of normal thyroid tissue within the fibrous wall. The patient's postoperative FVL confirming remarkable improvement is shown in Fig. 7. His final CT scans (after 3 months) are shown in Fig. 8, a-c.

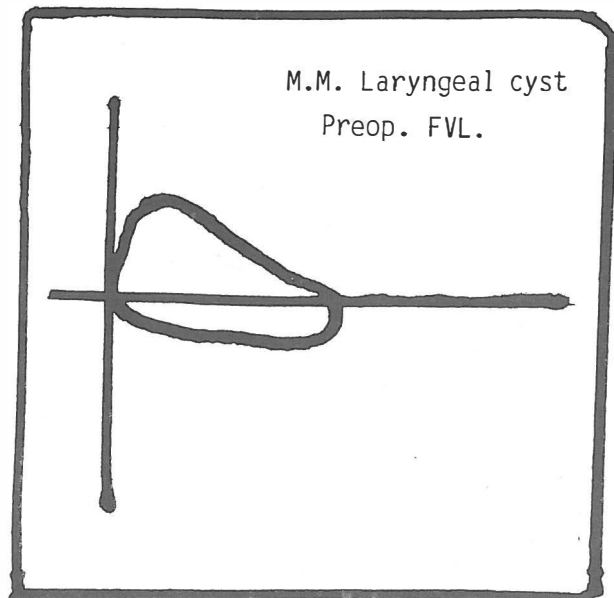


Fig. 5. Preoperative FVL.

DISCUSSION

Thyroglossal duct cysts are the most common congenital cysts of the neck other than odontogenic cysts. These cysts are the result of an embryonic arrest before the eighth gestational week. The cysts may develop at any point from the base of the tongue to the lower neck in or at the anterior midline of the neck.³ This is the exact path of thyroid migration. The endodermal tract of thyroid passage will be surrounded by the mesodermal tissue forming the hyoid bone.² The tract may stop here, pass in front, or, rarely, posterior to it.⁵ Most of the cysts are located inferior to the

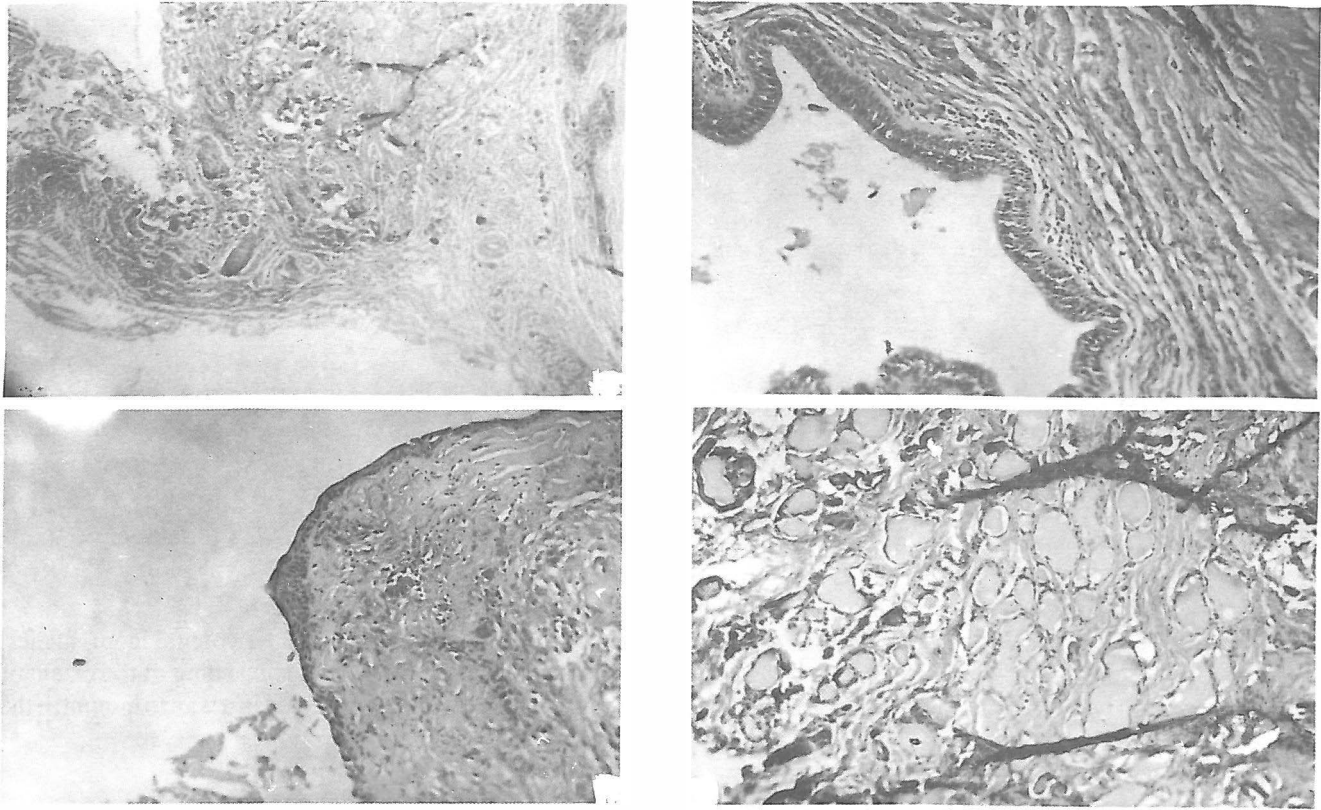


Fig. 6. Pathologic slides. a-cyst wall b- respiratory epithelium
c- area of squamous epithelium d- normal thyroid tissue.

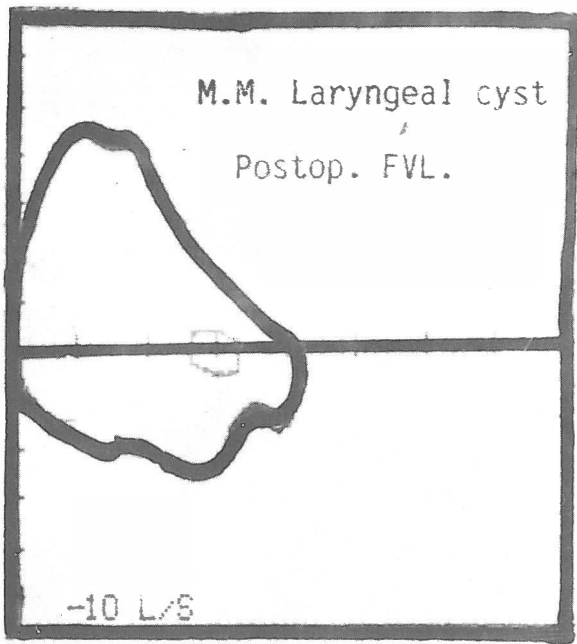


Fig. 7. Postoperative FVL.

hyoid bone. The knowledge of embryology dictates to us why the cysts are usually located extralaryngeally. Its presence at the base of the tongue or within the larynx is

considered to be exceptional.⁴

Endolaryngeal cysts are reported very rarely in the literature.^{4,5} Slotnick and Biller have presented three cases, all three of whom had extralaryngeal cystic masses as well.⁴ Ward and colleagues presented CT findings in five cases of thyroglossal cysts, one of which was totally endolaryngeal.⁵

The diagnosis is further complicated if the mass is totally endolaryngeal, where a differential diagnosis should be made from other endolaryngeal masses and cysts. Computed tomography with its new modalities and techniques simplifies the diagnosis. It will help to point out its actual location, extent, consistency and the impression of the cyst on surrounding structures such as the thyroid cartilage and endolaryngeal air space. Isotope scanning may help to show normal thyroid tissue in its normal location or thyroid tissue in an unusual location.

Our case was located totally within the larynx. CT and FVL studies revealed the amount of compromise to the airway. Surgical intervention prevented unnecessary intralaryngeal incision and late scar formation.

Surgical pathology findings are the ultimate diagnostic tool which has its own merit in confirming the exact nature of the pathology, clears the dilemma of diagnosis, and rules out the presence of malignancy, a very rare coincidence but important mishap.

Endolaryngeal Thyroglossal Duct Cyst

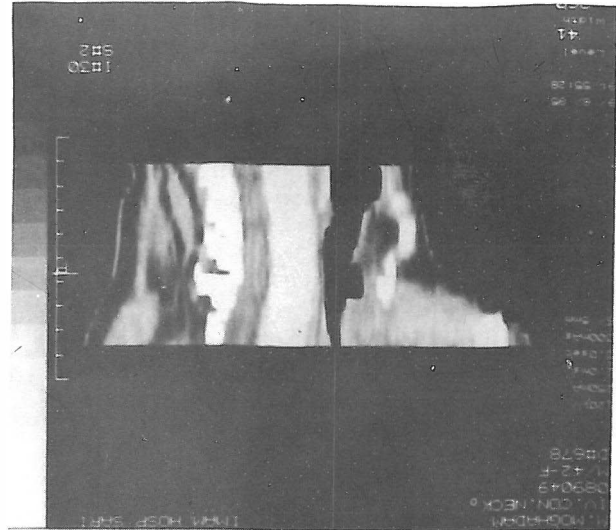
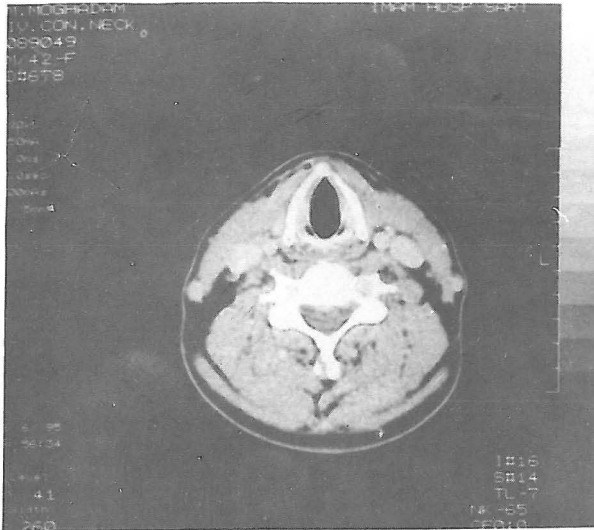
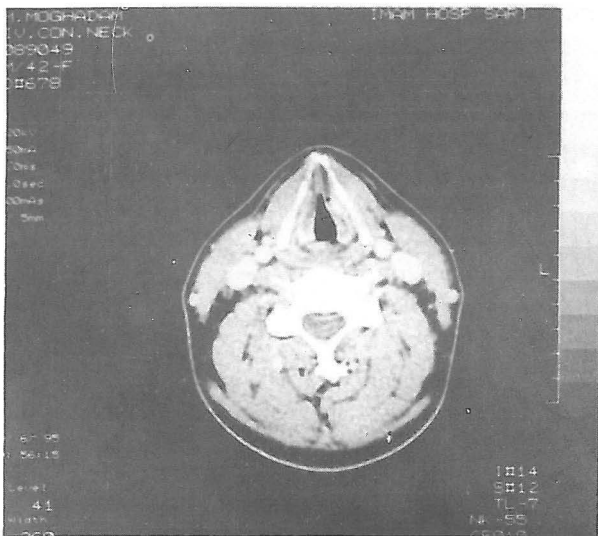


Fig. 8. a-c. Postoperative CT scans.



In conclusion, in exceptionally rare occasions, thyroglossal remnants may arise as endolaryngeal masses. This can produce diagnostic problems as well as airway and other functional difficulties. Marsupialization alone is not the solution. It should be further diagnosed preoperatively

by proper imaging and FVL (flow volume loop) studies. Thorough examination and understanding of the extent of the cyst will help us to approach it in a way to minimize the rate of complications.

REFERENCES

1. Ellis P: Branchial cleft anomalies, thyroglossal cysts and fistula. In: Scott Brown's Textbook of Otolaryngology. Vol. 6, 5th ed, London: Butterworth, p. 297, 1987.
2. Karmody CS: Developmental anomalies of the neck. In: Bluestone CD, (ed.). Pediatric Otolaryngology. 2nd ed, Philadelphia: W.B. Saunders Co, pp. 1303-1315, 1990.
3. Montgomery WW: Surgery of the Upper Respiratory System. Vol. 2, Philadelphia: Lea & Febiger Co, pp. 138-152, 1973.
4. Slotnick D, et al: Thyroglossal duct cysts that mimic laryngeal masses. Laryngoscope 97: 742, 1987.
5. Ward RF, et al: Computed tomography and thyroglossal duct cysts. Otolaryngology, Head & Neck Surgery 96: 93, 1986.