

VULVO-VAGINAL-GINGIVAL SYNDROME (VVG): A CASE REPORT

S.M. SADR ASHKEVARI, M.D., AND M.A.N. MANSOURI GHIASI,
M.D.

*From the Dept. of Dermatology, Razi Hospital, Gilan University of Medical Sciences, Rasht, Islamic
Republic of Iran.*

ABSTRACT

We report a 26 year old woman with erosive vulvo-vaginal mucositis followed by desquamative gingivitis, and typical histopathologic features of lichen planus (vulvo-vaginal-gingival syndrome). This is to our knowledge the first report of this syndrome from Iran and probably the youngest one in the world (with regard to the English literature).

MJIRI, Vol. 11, No. 2, 157-159, 1997.

INTRODUCTION

Desquamative gingivitis is usually a feature of cicatricial pemphigoid or lichen planus,⁹ and on the other hand, lichen planus is the most common cause of erosive or desquamative vulvitis together with desquamative vaginitis.²

Vulvar lichen planus has been reported rarely,¹⁰ and patients with erosive lichen planus of the vulva usually have no cutaneous manifestations.²

In 1989, Pelisse presented 19 cases of erosive vulvitis-vaginitis plus desquamative gingivitis as a rare new form of erosive lichen planus that has been termed vulvo-vaginal-gingival syndrome (VVG).¹⁰

Today it is accepted by many authors that desquamative mucositis of the vulva and vagina is usually associated or will soon be accompanied by desquamative gingivitis, and such a combination usually indicates that the patient's disorder is VVG syndrome and lichen planus.

Case report

A 26 year old woman was admitted to our department on

April 5th, 1995 with a 4-year history of erosive polymucositis (oro-genital lesions), that began with painful, itchy erosions of the vulva together with dyspareunia, followed by oral lesions.

On examination of the genital area, vulvar erosions with extension to the periurethral region and some invasion to the labia major and minor was seen, and some parts of the labia minor had been destroyed and deformed and there was an apparent white reticular margin around the erosions (Fig. 1).

Because of severe pain, vaginal examination was done under general anesthesia and erosions with a white reticular plaque were noted.

On examination of the oral cavity, two erosive erythematous lesions with a typical white reticular margin on the buccal aspects and superficial scaly erosions of the labial aspect of the gingiva without scar or synechiae were seen (Figs. 2,3).

The patient was free of cutaneous, hair and nail manifestations of lichen planus, her routine laboratory examinations (such as blood sugar, hepatic enzymes, ...) were normal, and there was no history of drug use or addiction.

Amongst four biopsy specimens of her mucosal lesions (two vulvar, one from the buccal mucosa and one vaginal), one vulvar lesion was partly compatible with cicatricial

Address:

S.H. Sadr Ashkevari, M.D.
Assistant Professor of Dermatology,
Department of Dermatology, Razi Hospital,
Sardar-e-Jangal Ave, Rasht, Islamic Republic of Iran.

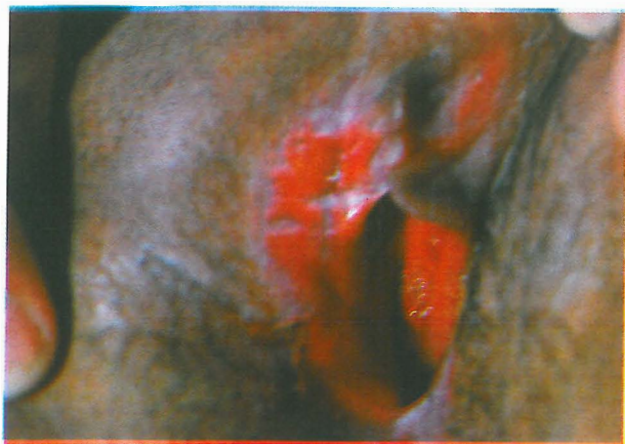

Fig. 1. Vulvo-vaginal erosions of bright red colour with typical white reticular margins.

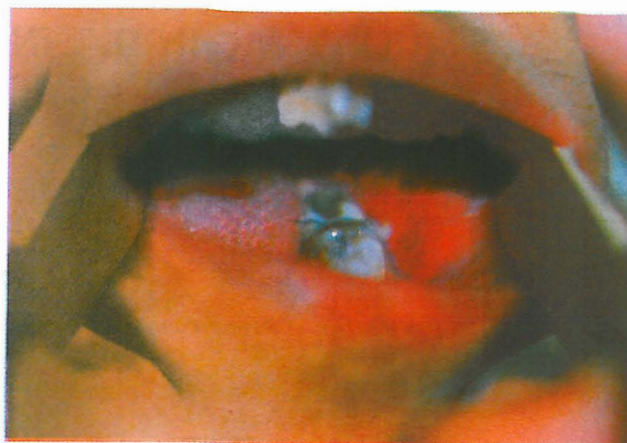

Fig. 3. Bright red buccal mucosal erosions with typical white reticular margins.

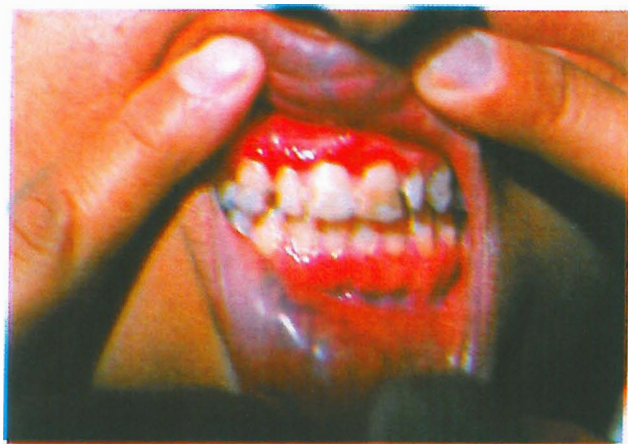

Fig. 2. Bright red erosive gingivitis of upper gums with mild white reticular margins.

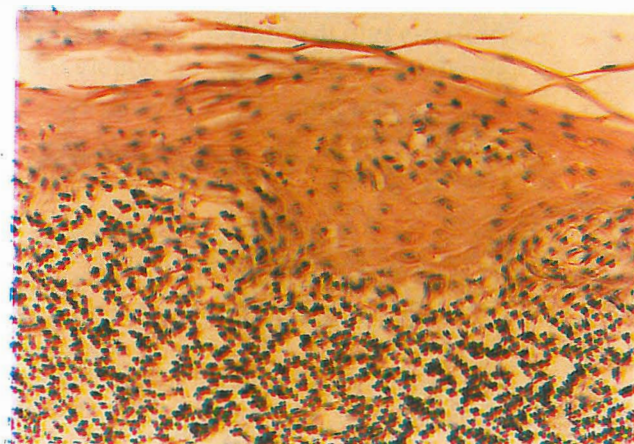


Fig. 4. Biopsy specimen of white edge of vulvar lesion. Typical changes of lichen planus, including liquefaction degeneration of the basal cell layer and band-like mononuclear cell infiltrates are present.

pemphigoid and one vaginal lesion had a nonspecific inflammatory reaction reported, but the second biopsy of the perilesional white border of vulvar erosions and buccal mucosa biopsy showed typical histology of lichen planus (Fig. 4).

With regard to a variety of treatments that have been used for therapy of this syndrome with more or less success,^{1,4-6,11} treatment of our patient was begun with 50 mg per day of dapsone, and this was gradually increased to 150 mg per day. Oral lesions showed some improvement, but because of a decrease in hemoglobin and no response of genital lesions, dapsone was stopped. Treatment continued with prednisolone (30 mg/day) orally and was tapered to 15 mg/day together with topical mid-potency corticosteroids due to a rise of blood sugar. During this period, buccal and gingival lesions improved but genital disease responded partially.

DISCUSSION

Desquamative gingivitis, typically seen in aged women, is usually a manifestation of cicatricial pemphigoid or lichen planus. It is rarely seen in pemphigus, dermatitis herpetiformis, or linear IgA bullous dermatosis.⁹ The most important differential diagnosis is that of allergic (atypic) or plasmocytic gingivostomatitis that occurs following use of gums and cinnamon-containing dentistry materials, and has a nonspecific histology with epithelial atrophy and infiltration of plasma cells in the lamina propria.^{3,7,8}

On the other hand, erosive vulvitis is predominantly due to lichen planus, lichen sclerosus et atrophicus, pemphigus, erythema multiformis, toxic epidermal necrolysis, lupus erythematosus, contact dermatitis, chronic bullous dermatosis of childhood or squamous cell carcinoma in

situ.⁴

Lichen planus is the most common cause of erosive or desquamative vulvitis with desquamative vaginitis.² Although vulvar lichen planus can occur at any age, most patients are over 40 years old.¹⁰ On the basis of Pelisse's criteria, occurrence of erosive or desquamative vulvovaginitis plus desquamative gingivitis is often due to erosive lichen planus,¹⁶ and is a new form of several clinical forms of lichen planus syndromes, with regard to the following criteria:

1) Presence of apparently visible reticular white margins at the border of mucosal lesions,

2) Presence of typical histologic features of lichen planus in biopsy specimens, if done from the afore-mentioned margin.

With regard to other reports of this syndrome and review of the literature, the clinical presentation and course of disease in our case is similar to Pelisse's report, but this case is the first reported case of vulvo-vaginal-gingival syndrome from Iran, and to our knowledge is probably the youngest one in the world.

We agree with Pelisse about the cause of rarity of this syndrome, who believes that if dermatologists and gynecologists who are involved in mucosal disorders examine other mucosal areas more completely, the real frequency of this syndrome will be realized.

ACKNOWLEDGEMENT

We are thankful to M. Nasiri Kashani, M.D.,

Dermatologist, for his interesting referral, and the Obstetrics and Gynecology Department and Med-line of Gilan University of Medical Sciences for their cooperation.

REFERENCES

1. Bollag W, Ott F: Treatment of lichen planus with temarotene. *Lancet* 11: 974, 1989.
2. Edward L: Desquamative vulvitis. *Dermatol Clinics*, Philadelphia: W.B. Saunders Co., 10: 325-36, 1992.
3. Eversol LR, Ringer M: The role of dental restorative metal in the pathogenesis of oral LP. *Surg* 57: 383-7, 1984.
4. Falk DK, Latour DL, King LE, Jr: Dapsone in the treatment of erosive LP. *J Am Acad Dermatol* 12: 567-70, 1985.
5. Ho VC, Lui H, McLean DI: Cyclosporine in non-psoriatic dermatoses. *J Am Acad Dermatol* 23: 1248-59, 1990.
6. Laurberg G, Geiger JM, Hjorth N, et al: Treatment of LP with acitretin: a double-blind, placebo control study in 65 patients. *J Am Acad Dermatol* 24: 434-437, 1991.
7. Lubow RM, Cooley RL, Hartman KJ, et al: Plasma cell gingivitis: report of a case. *J Periodontol* 55: 234-41, 1984.
8. McLeod FI, Ellis JC: Plasma cell gingivitis related to the use of herbal toothpaste. *Br Dent J* 166: 375-6, 1989.
9. Nisengard RJ, Nieders M: Desquamative lesion of the gingiva. *J Periodontol* 52: 500-510, 1981.
10. Pelisse M: The vulvo-vaginal-gingival syndrome: a new form of erosive LP. *Int J Dermatol* 28: 381, 1989.
11. Scully C: Treatment of oral LP. *Lancet* 336: 913-14, 1990.

