

PRIMARY MALIGNANT PERICARDIAL MESOTHELIOMA

MOHAMMAD REZA MOTAMEDI, M.D.,
AND P. SHISHINEH,* M.D.

*From the Departments of Cardiology and *Pathology, Shahid Modarres Hospital, Shahid Beheshti
University of Medical Sciences, Tehran, Islamic Republic of Iran.*

ABSTRACT

Primary malignant neoplasms of the pericardium are rare and are predominantly mesotheliomas, followed by benign localized fibrous mesothelioma, malignant fibrosarcoma, angiosarcoma and benign and malignant teratomas.¹

This article concerns an atypical presentation of this malignant tumor with symptoms and signs of pericardial effusion. This unusual feature was complete encasement of the heart by this tumor, without pericardial effusion.

Keywords: Pericardium, tumor

MJIRI, Vol. 11, No. 2, 163-167, 1997.

INTRODUCTION

Diagnosis of pericardial tumors is always an important matter and usually faces a great deal of difficulties. The importance of correct diagnosis of these tumors arises from the fact that these tumors frequently present themselves similar to other pericardial diseases such as pericardial effusions, tamponade, etc., and time should not be wasted for quick diagnosis and correct management.

This article presents a very rare case of mesothelioma of the pericardium with some of the above-mentioned features.

CASE REPORT

A 54 year old man was admitted to our hospital with a chief complaint of dyspnea on exertion. The history of his present illness dated back to 4 months ago, when his dyspnea on exertion started and was associated with orthopnea, PND, abdominal swelling and nonproductive cough. His problems were progressive in nature since then and accompanied by a weight loss of 5-6 kg and a decrease in appetite. There was no record regarding any significant illness in the past.

He had been on anti-tuberculous treatment with two drugs (INH, 300 mg and rifampicin, 600 mg daily) up to one month before his admission to our ward.

His physical examination revealed a middle aged man who was pale with a blood pressure of 100/70 and a regular pulse. Important findings included the absence of any lymphatic nodes on his neck or axillary area, and the presence

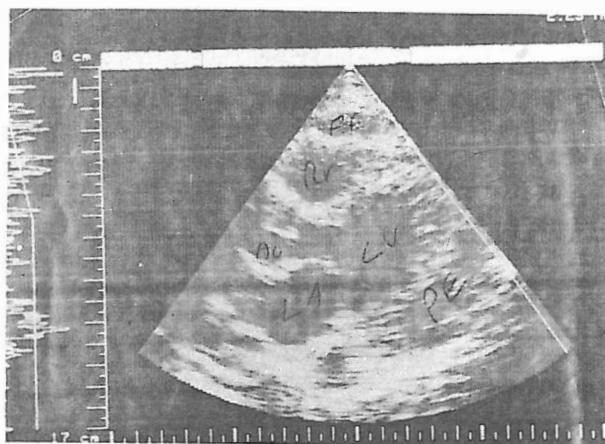


Fig. 1. Two-dimensional echocardiography of the patient demonstrating massive pericardial effusion.

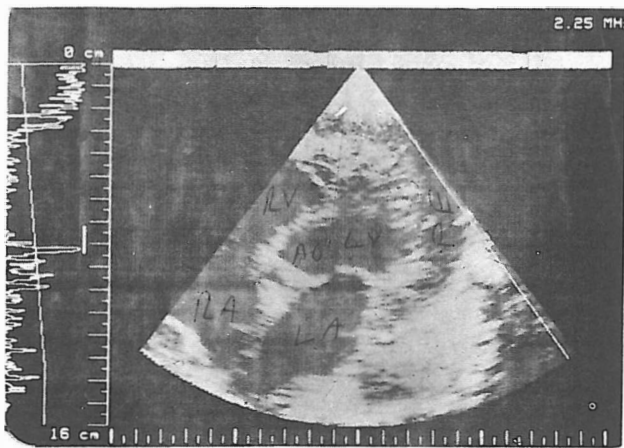


Fig. 2. Another two-dimensional echocardiographic study revealing pericardial effusion.

of very distended jugular veins but no paradoxical pulse. Chest examination revealed the PMI to be at the 6th intercostal space.

Auscultation of the heart revealed a regular rhythm with normal first and second heart sounds, the presence of a pericardial knock, and a grade 2/6 early systolic murmur at the high LSB. Lung examination disclosed normal vesicular breathing sounds.

His abdomen was clearly distended. 4-5cm below the right costal margin, and was tender and painful. The spleen was not palpable, and a clearly visible ascites with shifting dullness was present. There was mild pedal edema, and all peripheral pulses were patent.

On laboratory examination, the ECG showed a sinus rhythm with inverted T waves in leads II, III, aV_F, V₅-V₆. The chest x-ray revealed global cardiomegaly with normal pulmonary vascular markings.

The patient had previously undergone echocardiographic studies for 4 times prior to his admission, all of which were compatible with massive pericardial effusion, but surprisingly with no tamponade present. He had an ESR of 36-68, a PPD of 15 mm, and normal CBC, FBS, BUN, creatinine, Na⁺, K⁺ and platelet counts. enzyme levels were normal, with the exception of an LDH of 789.

Since he had an abnormal ECG and massive pericardial effusion with one possible etiology being tuberculosis, he underwent cardiac catheterization and coronary arteriography which by hemodynamic data raised the possibility of constrictive pericarditis.

Left ventriculography revealed a hypokinetic anterior wall with an EF of 45%. Selective coronary arteriography demonstrated relatively normal coronary arteries.

The patient underwent a few unsuccessful trials of pericardiocentesis, and since his clinical status was progressively deteriorating, he became a candidate for palliative

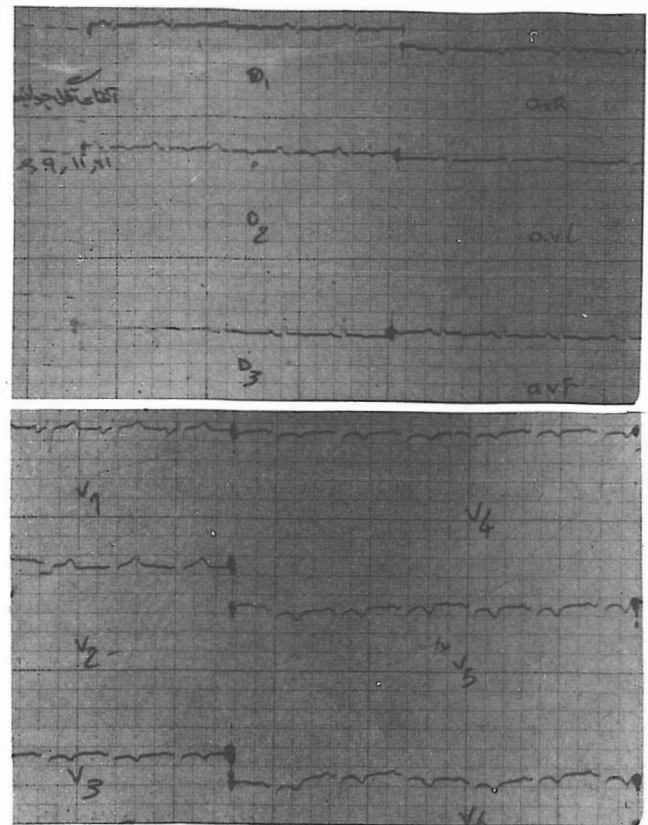


Fig. 3. Electrocardiography of the patient showing significant anterolateral wall ischemia.

surgery to release the heart from the heavy pericardial effusion. The surgeons were quite surprised to encounter massive and extensive tumoral growth, and no pericardial effusion at all. examination.

Macroscopic examination

The heart weighed 2000 gr and measured 20 × 18.5 × 11 cm. On the upper side of the specimen a few black lymph nodes were seen. On the outer side, the heart was firm and nodular.

thick nodular tumoral tissue, the boundary of which had not invaded the heart wall. A few yellowish sites were noticed, and the thickness of the tumor was 2.7 cm. The tumor surrounded the right atrium.

The thickness of the right ventricle which was also surrounded by tumoral tissue and showed more trabeculation than normal was 0.5 cm.

The left atrium was free of tumoral tissue. The thickness of the left ventricular wall was 1.7 cm and was infiltrated in part by tumoral tissue.

The tricuspid valve had a soft consistency measuring 3 cm in diameter and 6.3 cm in circumference. The pulmonary valve measured 3 cm in diameter and 6.5 cm in circumference. The mitral valve measured 2.5 cm in diameter and 6

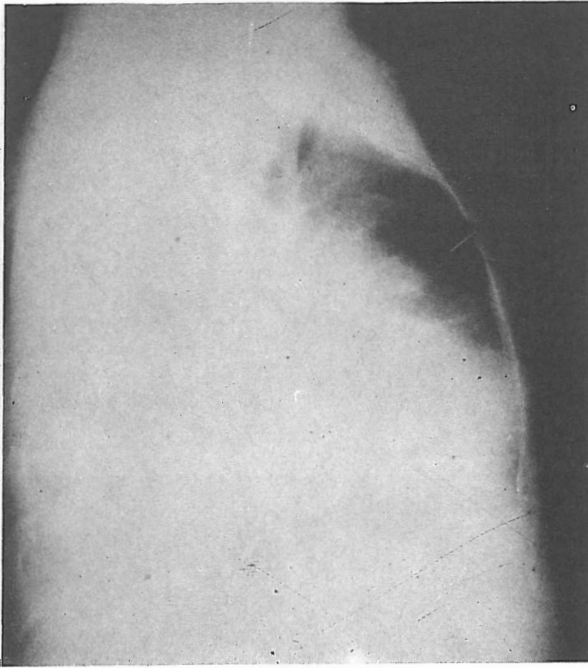


Fig. 4. Chest x-ray of the patient demonstrating global cardiomegaly, most likely due to massive pericardial effusion.

cm in circumference and contained a few prominent whitish spots on the atrial side. The aortic valve measured 2.5 cm in diameter and 3.5 cm in circumference.

Microscopic examination

Tumoral tissue was composed of cuboidal pleomorphic




Fig. 5. M-mode echocardiography of the patient showing evidence of moderate pericardial effusion.

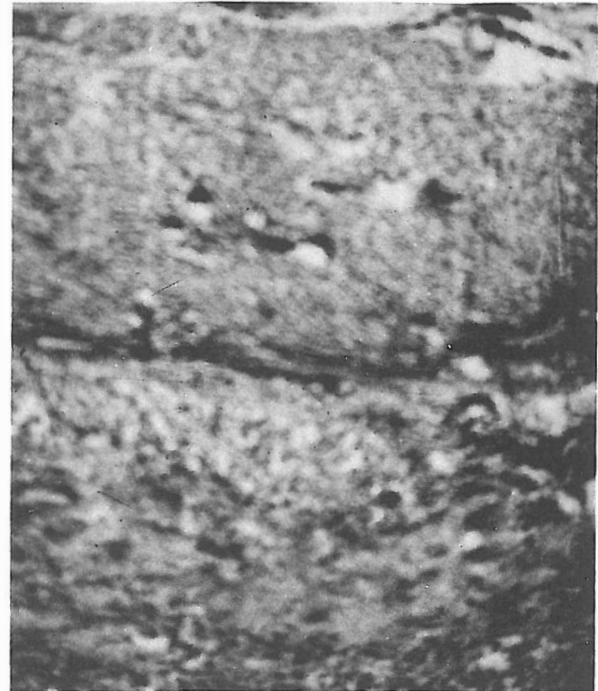

Fig. 6. Mesothelioma infiltrating the myocardium.

hyperchromatic cells with papillary projections in connective tissue stroma. In some areas, the tumoral cells were spindle-shaped and chronic inflammatory cell infiltration with necrosis was seen. Diagnosis was epithelial mesothelioma.

A few days later the patient developed severe congestive heart failure and shock, and expired in spite of all medical efforts.

DISCUSSION

Primary tumors of the pericardium are extremely rare. One of the largest necropsy series of recent years gives an

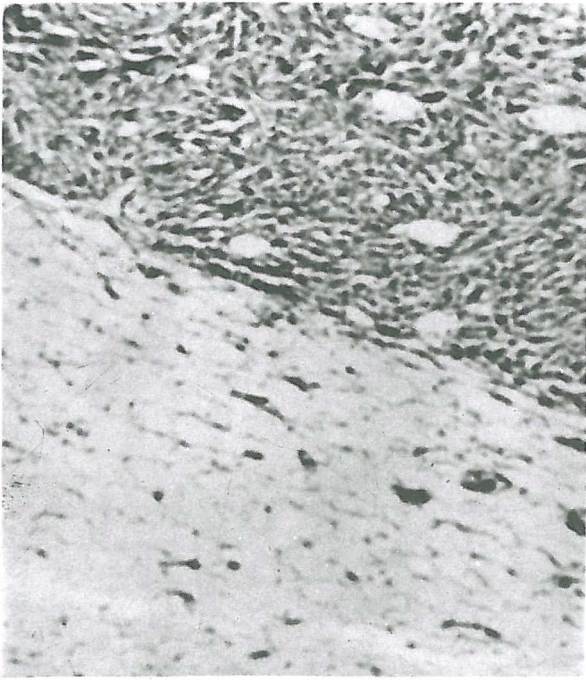


Fig. 7. Mesothelioma of the pericardium with invasion of pericardial fat.

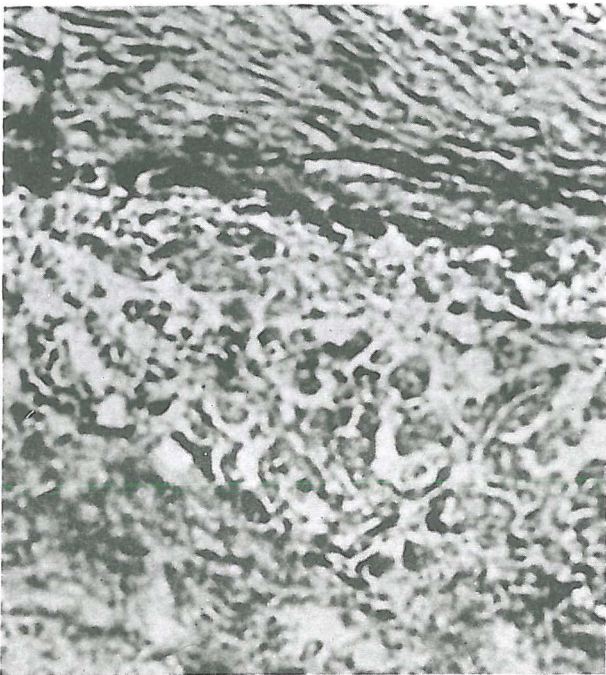


Fig. 8. Mesothelioma of the pericardium showing a mixed papillary and fibroblastic pattern.

incidence of 0.0022 in 500,000 cases. Mesothelioma is probably the most common type, followed by sarcoma, teratoma, fibroma, lipoma and angioma.²

Complete encasement of the heart by tumor is an un-

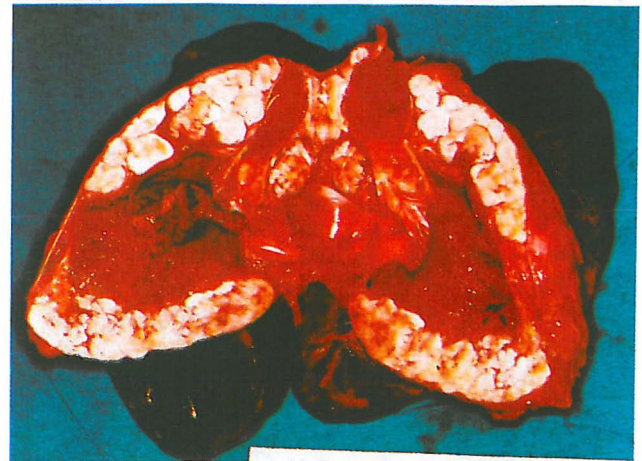
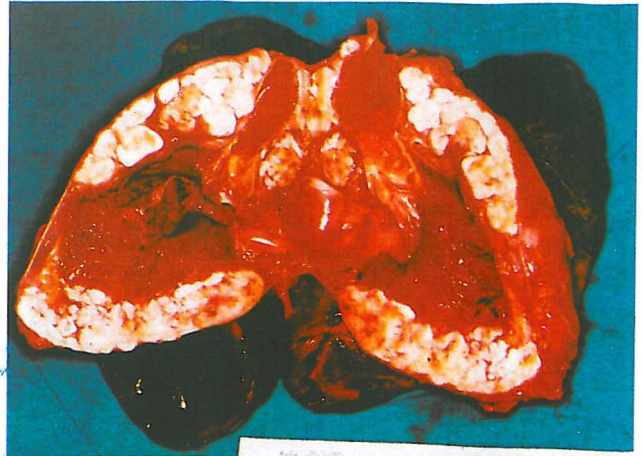
Fig. 9. Cross-section of the heart showing tumor deposits in the membranes surrounding the heart (whitish area). One involved lymph node is present in the upper part. Both lungs are intact.

usual feature and has been rarely reported. In our case, the left atrium was the only site which was not surrounded by tumoral tissue. Also, pericardial tumors are often adherent to or may invade the myocardium.³ Our case showed the tumoral cells to be invading the left ventricular myocardium.

The tumor can also invade the conductive tissue, the coronary arteries, or compress the great vessels. Local spread is common but extrathoracic metastasis is extremely rare.³

The clinical presentation is either as constrictive pericarditis or as effusion with or without tamponade.⁵

In another classification, a primary pericardial mesothelioma can present as five different syndromes:⁴

1- Pericardial effusion, especially hemorrhagic, without signs of inflammatory disease.

2- Modified cardiac silhouette with bizarre irregular borders.

3- Heart failure without obvious etiology, especially with venous hypertension and manifestations such as

hepatomegaly, ascites and edema, as seen in our case.

4- Narrowed pulse pressure and paradoxical pulse characteristic of cardiac compression.

5- Superior vena caval obstruction.

Antemortem diagnosis of this disease is extremely difficult. In a review of 31 cases by Andersen and Hansen only 13 cases were diagnosed before death.⁴ In general, echocardiography cannot differentiate between a tumoral mass and pericardial fluid, as was the situation in our case. In one case reviewed by Schlant et al, computed tomography showed thickening of the pericardium which, in retrospect, was thought to be the tumor tissue.⁴

Cytologic examination of pericardial fluid, if possible to obtain, is relatively nondiagnostic because of great difficulties in differentiating malignant mesothelial cells from reactive cells.⁵

Andersen and Hansen reported that the cytologic diagnosis could be made in only 3 of 11 patients from pericardial fluid. Thomas and Phythyon found that a rapid reaccumulation of bloody pericardial fluid following pericardiocentesis, in the absence of tuberculosis, is highly suggestive of malignancy.⁵

When pericardiocentesis fails to submit fluid, computed tomography of the pericardial space may be used to demonstrate the presence of a cellular mass.⁴

Treatment is usually unsuccessful due to late detection, and Norman has reported a 60% death rate within six

months.⁶ Complete surgical resection is impossible, and surgery is confined to those with obstructive complications in order to relieve the compression.⁶

If pericardial effusion is present, local instillation of cytotoxic and sclerosing agents can be helpful, though the effect of systemic chemotherapy is not encouraging. Radiotherapy may help to reduce tumor size.⁶

REFERENCES

1. Lorell BH, Braunwald E: Pericardial Disease. In: Braunwald E (ed.), *Heart Disease, A Textbook of Cardiovascular Medicine*. Philadelphia: W.B. Saunders Co., p. 1497, 1992.
2. Roberts WC: A survey of cardiac tumors. *New Engl J Med* 304(17): 1981.
3. Coben TL: Neoplastic pericarditis. *Cardiovasc Clin* 7: 257-69, 1987.
4. Yilling FP, Schlant RC, Hertzler GL, Krzyaniak R: Pericardial mesothelioma. *Chest* 81: 250-60, 1982.
5. Kirwan M, Blakes Neligen M, et al: Cardiac constriction due to malignant disease of the pericardium. *Ir J Med Sci* 152: 454-5, 1983.
6. Syman AI, MacAlpin RN: Primary pericardial mesothelioma: report of two cases and review of the literature. *Am Heart J* 81: 160-9, 1971.

The contents appearing in
this publication are indexed by



For further information, please contact:

Dr. Munawar A. Anees, Editor-in-Chief, *Periodica Islamica*

31 Jalan Riong, Kuala Lumpur-59100, Malaysia

Tel (+60-3)282-5286 • Fax (+60-3)282-8489

eMail: America Online: *dranees* • CompuServe: *dranees*

Delphi: *drmanees* • InterNet: *dranees@klcyber.pc.my*

URL: <http://www.ummah.org.uk/dranees/periodica/>
