

Surgical treatment results of acute acromioclavicular injuries

Mahmoud Jabalameli, MD.¹, Mohammad Rahbar, MD.², Mehdi Ramezan Shirazi, MD.³

Shafa Yahyaian Hospital, Iran University of Medical Sciences, Tehran, Iran

Abstract

Background: Different methods of surgical treatment for acromioclavicular(AC) joint injury were considered in the literature. The purpose of the study was to compare intra-articular AC repair technique with the extra-articular coracoclavicular repair technique for the patients with Rockwood type III and V AC joint injury when indicated.

Methods: Nineteen consecutive patients with Rockwood type III and V AC joint injury were treated with intra-articular (Group I - 12 cases) and extra-articular (Group II - 7 cases) repair technique between 1380 - 1386, and the results reviewed. When the diagnosis was established, the mean age of the patients was 32.5 years (Range, 18 - 60); group I and II 31.8 years (Range, 18 - 60) and 34 years (Range, 22 - 58) respectively. The mean duration of postoperative follow - up was 24 months. The Constant shoulder scoring system was applied to obtain clinical results.

Results: Only in group I, the post-surgical complication was associated with fiber allergy, wound infection and pin site infection in two patients respectively. No pain was detected in fourteen cases. Four patients in group I had occasional mild pain during sport activity, while one case in this group reported severe pain during resting which prevented the patient from activity. Also, there was an ossification in thirteen patients particularly in group I. Clinical results showed the mean constant shoulder score was 93.4 in group I and 97.1 in group II.

Conclusion: At the time of the follow - up, there was a clear difference between both groups regarding to postoperative pain and discomfort. Therefore, it seemed that potential cause of pain was due to postoperative complications. An interesting postoperative complication without interfere in the functional outcome was coracoclavicular space ossification in most cases. This was probably because of soft tissue injury during the operation. It seemed that surgical treatment of Rockwood type III and V AC joint injuries when indicated had acceptable clinical results particularly if the extra-articular AC repair technique (screw fixation) was chosen. The new arthroscopic surgical technique with endobutton may decrease the rate of complications such as fracture site ossification and morbidity although more study in this field is required.

Keywords: acromioclavicular, joint, intra-articular repair, extra-articular repair

Introduction

The best classification for these injuries was based on the extent of soft tissue damage by the given force [1]. The classification system of Allman and Tossy revised by Rockwood defines best the extent of the injury to acromio-

clavicular(AC) joint and helps the surgeon to manage such injuries [2].

However, the management of acute AC joint dislocation remains controversial. In acute setting, type IV, V, VI injuries nearly always require operative treatment [3,4,5] while treatment of type III injuries remains controversial.

1. Associate Professor of Orthopedic Surgery, Iran University of Medical Sciences, Tehran, Iran.

2. Assistant Professor of Orthopedic Surgery, Iran University of Medical Sciences, Tehran, Iran.

3. **Corresponding author;** Resident of Orthopedic Surgery, Shafa Yahyaian Hospital, Baharestan Sq., Tehran, Iran. Tel: +9821 22851923, E-mail: Mehdi.shirazi@yahoo.co.uk

Pain	Points	a
None	15	
Mild	10	
Moderate	5	
Severe	0	

Activity Level	Points	b
Full work	4	
Full recreation/ sport	4	
Unaffected sleep	2	

Positioning	Points	c
Up to waist	2	
Up to Xiphoid	4	
Up to neck	6	
Up to top of head	8	
Above head	10	

Elevation (Degrees)	Points	d
0 – 30	0	
31 – 60	2	
61 – 90	4	
91 – 120	6	
121 – 150	8	
151 – 180	10	

Hand behind head with elbow held forward	2	e
Hand behind head with elbow held back	2	
Hand on top of head with elbow held forward	2	
Hand on top of head with elbow held back	2	
Full elevation from on top of head	2	

Dorsum of hand to lateral thigh	0	f
Dorsum of hand to buttock	2	
Dorsum of hand to lumbosacral junction	4	
Dorsum of hand to waist (L3)	6	
Dorsum of hand to 12 th dorsal vertebrae	8	
Dorsum of hand to interscapular region	10	

Table 1. Constant Shoulder Scoring System. a,b,c: Activities of Daily Living; d: Points for forward and lateral elevation; e: External Rotation Scoring; f: Internal Rotation Scoring

No perfect study exists which demonstrates clear superiority of operative and nonoperative treatment. Rockwood considers some indications for the treatment of acute type III injuries including heavy manual laborer, patients with concomitant brachial plexus injury, overhand athletes with involving the dominant arm [1].

Various methods of surgical treatment for the injury were considered in the literature including intra-articular AC repairs, extra-articular coracoclavicular repairs, combined AC & coracoclavicular repairs and dynamic muscle transfers using the tip of the coracoids process [1,6,7].

Since no defined criteria existed in the literature for the method of operative treatment, this study was aimed to evaluate the results of operative treatment of acromioclavicular joint injury using two different methods, intra-articular AC repairs with pins and extra-articular coracoclavicular repair with screws.

Methods

We reviewed the outcome of operative re-

sults of AC joint injuries without fractures in 19 consecutive patients at Shafa Yahyaian hospital between 1380 - 1386. The mean age of patients was 32.5 years (range, 18 - 60 years) when the surgery was performed. Eighteen patients were male and one was female. The mean duration of follow - up was 24 months (range, 5 to 70 months) (Table 2).

We have relied on the classification system recommended by Rockwood's group which was the most widely accepted classification system, based on the original work of Tossy et al in 1963 [8]. In accordance with the mentioned classification, four developed type III injury and the remaining cases type V injury.

Postoperatively, all patients were visited regularly and anteroposterior and lateral plain x - rays were taken to check the range of motion and complications. At all follow - ups, patients were examined by the senior author. The goal of every follow - up for each patient was, as follow;

1. Assessment of probable complications: infection, device loosening/ breakage and device

Cases	Age	Sex	Type of injury	Treatment option*	Patient's occupation
1	29	M	V	1	Employee
2	35	F	V	1	Housewife
3	25	M	V	1	Employee
4	28	M	V	1	Worker
5	38	M	V	1	Worker
6	18	M	V	1	Student
7	20	M	V	1	Employee
8	25	M	III	2	Worker
9	47	M	V	2	GP
10	23	M	III	2	Employee
11	27	M	V	2	Driver
12	58	M	III	2	Carpenter
13	36	M	V	2	Worker
14	29	M	V	1	Student
15	50	M	V	1	Driver
16	60	M	V	1	Accountant
17	20	M	V	1	Employee
18	22	M	III	2	Student
19	30	M	V	1	Butcher

*Treatment options: 1. Pin fixation +/- coracoacromial ligament repair, 2. Screw fixation

Table 2. Demographic data of the cases and the surgical technique applied

allergy

2. Determination of pain severity subjectively: Grade I: no pain/occasional mild pain during sport activity, Grade II: moderate pain during normal activity and Grade III: severe pain during rest which prevents the patient from any activity.

3. Determination of constant scoring system (Table 1)

4. Assessment of the first and latest x - ray for comparison

Treatment Protocol

In group I, Intra-articular AC fixation was applied. Two k-wires were inserted from the lateral edge of the acromion through the joint and into the clavicle. If any part of acromioclavicular ligament could be identified as good quality, a suture was passed between the torn ends of coracoclavicular ligaments.

In group II, extra-articular coracoclavicular fixation was applied. Under the fluoroscopic guidance, a screw was inserted to fix the clavicle to the base of the coracoid.

Results

Twelve patients were treated with the first surgical method whereas seven managed with the other technique.

Active and passive ranges of motion at the glenohumeral and scapulothoracic joints in the operated side were compared with the other side and no significant difference was detected (Table 3) and no palpable crepitus could be noted. At last follow - up, twelve patients were satisfied with cosmetic appearance and function of the shoulder while seven cases were not. On specific questioning, only one patient in group I had severe pain during rest which prevented the patient from any activity whereas fourteen cases experienced no pain (Table 3). Four patients in the first group had mild occasional pain during sport activity.

In order to report the outcome of shoulder conditions, constant shoulder score system was applied (Table 1). In accordance with the scoring system, the mean score was 93.4 +/- 8.3 in group I and 97.1 +/- 2.7 in group II (Table 3). It

Cases	Constant Score	Grading of Pain	Patient's Satisfaction*	Range of Motion	Fracture Site Ossification
1	83	I	2	Full	Yes
2	76	III	2	Full	No
3	84	I	2	Full	No
4	90	I	2	Full	No
5	100	No Pain	1	Full	Yes
6	100	No Pain	1	Full	No
7	100	No Pain	1	Full	Yes
8	95	No Pain	1	Full	No
9	100	No Pain	1	Full	Yes
10	94	No Pain	1	Full	Yes
11	100	No Pain	1	Full	Yes
12	100	No Pain	1	Full	Yes
13	95	No Pain	1	Full	Yes
14	98	No Pain	2	Full	Yes
15	100	No Pain	1	Full	Yes
16	99	No Pain	1	Full	Yes
17	92	I	1	Full	Yes
18	96	No Pain	1	Full	Yes
19	99	No Pain	1	Full	No

*Patient's satisfaction: 1. Satisfied, 2. Not Satisfied

Table 3. The postoperative functional outcome and fracture site ossification.

should be noted that there was no significant relationship between the surgical method and the shoulder scoring (P value = 0.536).

Radiographically, three patients had an increase in the coracoclavicular space in comparison to the normal shoulder while no coracoclavicular space increase was noted in sixteen cases postoperatively. Of three cases with coracoclavicular space increase, two occurred in group I and one in the other group (Table 2 & 4). Also, there was an ossification in thirteen pa-

tients with seven patients in group I and six in group II (Table 3). Statistically, no significant relationship between the ossification site and the surgical technique (screw vs. pin fixation) was revealed (P value = 0.238).

Five patients in group I had postoperative complications: pin breakage in one, fiber allergy in two, wound infection in one, and pin site infection in one patient (Table 4). Pin breakage was one of the important complications seen in group I. This was the reason that many surgeons

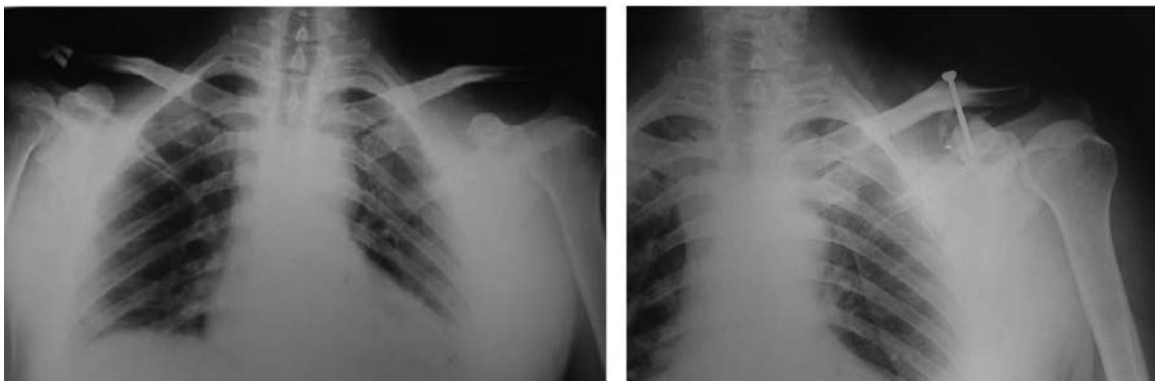


Fig. 1. Case 9. A 47 year old male patient with left AC joint injury treated with screw fixation. Coracoclavicular space ossification postoperatively is noted.

Cases	Infection/Allergy reaction	Device loosening/breakage	Postop Radiology*
1	Fiber Allergy	None	2
2	Wound Infection	None	2
3	None	None	1
4	None	None	1
5	Pin Site Infection	None	1
6	Fiber Allergy	None	1
7	None	Pin Breakage	1
8	None	None	1
9	None	None	1
10	None	None	1
11	None	None	1
12	None	None	2
13	None	None	1
14	None	None	1
15	None	None	1
16	None	None	1
17	None	None	1
18	None	None	1
19	None	None	1

*Postoperative radiology: 1. No displacement, 2. Displacement either partial or complete

Table 4. Postoperative complications

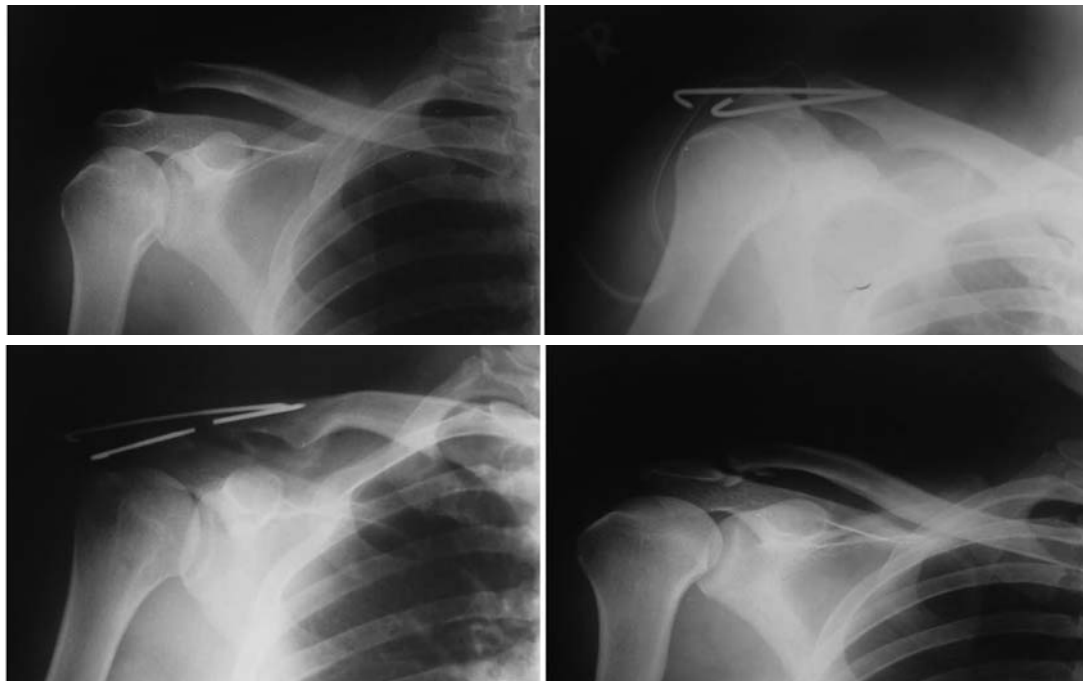


Fig. 2. Case 7. A 20 year old male patient with right AC joint injury. Group 1 fixation was applied. a: Preoperative plain X-ray; b: Postoperative x-ray; c: Pin breakage postoperatively; d: Postop x-ray after pin removal.

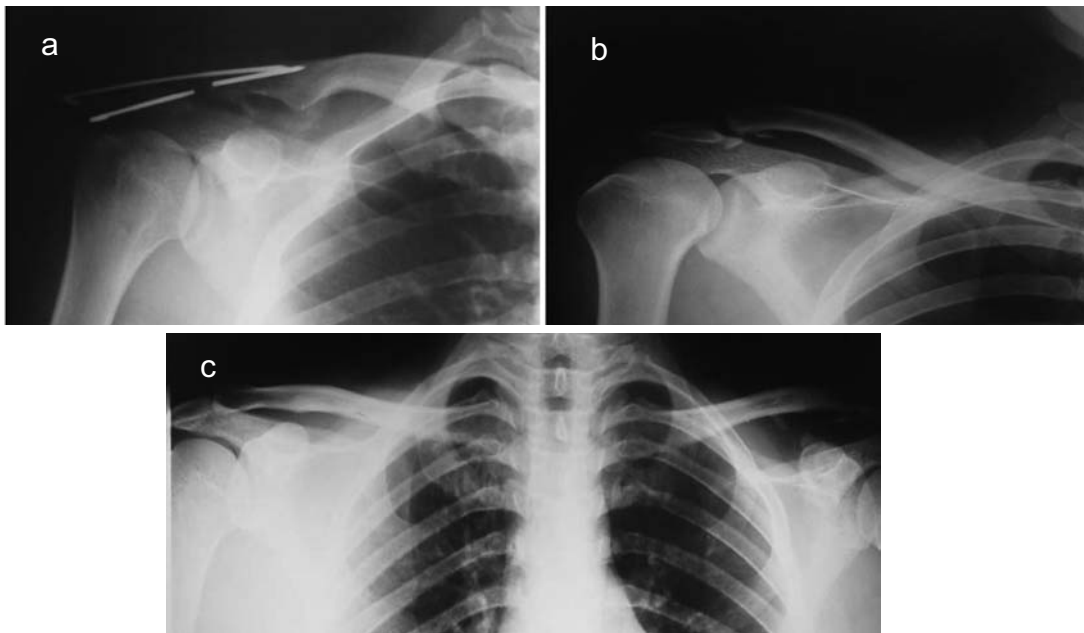


Fig. 3. Case 1. A 29 year old male patient with left AC joint injury treated with pin fixation. a: Preoperative x-ray; b: Postoperative x-ray; c: Postoperative x-ray after pin removal. An increase in the coracoclavicular space in comparison to the normal shoulder was detected.

avoided applying this method. Statistically, there was not significant relationship between the surgical method applied and the rate of complications.

Discussion

At the time of the follow - up, there was a clear difference between both groups regarding to postoperative pain and discomfort. Two of five patients with postoperative pain had fiber allergy and wound infection. Therefore, it seemed that postoperative complications had potentiality in causing pain.

Concerning postoperative radiologic findings, there were three cases with an increase of coracoclavicular space comparing to the uninvolved side. One of them was asymptomatic clinically; second one had grade I pain and the last complained of grade III pain. Therefore, it should be concluded that postoperative radiologic displacement influences the clinical result.

Comparison of surgical results of mentioned techniques, revealed that those treated with in-

tra-articular AC repair (pin fixation) had more complication postoperatively although no significant difference was detected statistically.

An interesting postoperative complication without interfere in the functional outcome was coracoclavicular space ossification in seven and five cases in group 1 and 2 respectively. Its reason was probably soft tissue injury during the operation. Concerning the incidence of the complication, there was no significant difference between group I & II.

With regard to the constant shoulder score of two groups, it seemed that surgical treatment of Rockwood type III and V when AC joint injuries indicated had acceptable clinical results particularly if the extra-articular AC repair technique (screw fixation) was chosen. Perhaps, new arthroscopic surgical technique with endobutton decreases the rate of complications such as fracture site ossification and also morbidity although more study is required in this field.

References

1. Bucholz RW, Court-Brown C. Rockwood & Wilkins' Fractures in Adults, 6th edition. Lippincott, 2006; pp.1331 - 1361.
2. Bradley JP, Elkousy H: Decision making: Operative versus nonoperative treatment of acromioclavicular joint injuries. Clin Sports Med. 2003; 22(2): 277 - 90.
3. Sondergard-Peterson P, Mikkelsen P. Posterior Acromioclavicular Dislocation. J Bone Joint Surg [Br]: 1982; 64:52 - 53.
4. McPhee IB. Inferior dislocation of the outer end of the clavicle. J Trauma: 1980; 20: 709 - 710.
5. Gerber C, Rockwood CA. Subcoracoid dislocation of the lateral end of the clavicle; a report of three cases. J Bone Joint Surg [Am]: 1987; 69: 924 - 927.
6. Rockwood CA. Injuries to the acromioclavicular joint. In: Rockwood CA, Green DP. Fractures in Adults, vol 1, 2nd ed. Philadelphia: JB Lippincott, 1984: 860.
7. Skjeldal S, Lundblad R. Coracoid process transfer for acromioclavicular dislocation. Acta Orthop Scand 1988; 59: 180 - 182.
8. Tossy JD, Mead NC, Sigmund HM. Acromioclavicular separations: Useful and practical classification for treatment. Clin Orthop 1963; 28: 111 - 119.