

ADJUSTABLE SUTURE IN STRABISMUS SURGERY

H. RAZMJOO, M.D.

*From the Department of Ophthalmology, School of Medicine, Isfahan University of Medical Sciences,
Isfahan, Islamic Republic of Iran.*

ABSTRACT

Adjustable suture in strabismus surgery is a way to get accurate alignment of the eyes after operation. This technique is used in cooperative patients, being either adults or children.

We report the result of this technique in 120 patients, 70 with esotropia and 50 exotropia. The amount of deviation was between 20 and 60 prism diopters. The patients were mostly adults and teenagers, and the youngest patient was 10 years old. Post-adjustment deviation was less than 15 prism diopters in almost all cases. After 2 to 3 years of follow-up, no patient needed reoperation.

MJIRI, Vol. 11, No. 1, 7-10, 1997.

INTRODUCTION

Various types of operations are used to correct deviation in patients with strabismus. These operations vary in the type of anesthesia, the muscles which are operated on and so on. Adjustable suture technique is a method of operation in which muscle reattachment to the globe is completed when the patient is awake so that the amount of deviation can be checked at the same time that the site of the muscle's new insertion is adjusted. It helps to achieve an acceptable result which is desirable for both surgeon and patient. Even though it is a little inconvenient for the patient, it gives him or her more confidence.¹

Many believe that satisfactory alignment during the early post-operative period provides the best chance of a successful long-term result.² It should be mentioned that the amount of recession and resection which are written in reference texts don't lead to an accurate result due to variations in the anatomical conditions of the eye; for instance, if the eye is myopic, for each 3 diopters of axial myopia the antero-posterior diameter of the eye increases one millimeter, thus affecting the circumference of the eye and eventually the amount of recession which is necessary. Aside from this, in myopia the muscles are stretched and need more recession.³

This technique can also be used to get certain amounts of under- or over-correction in order to get late accurate

results.³ It is also used when partial forces need to be balanced. This is one of the most difficult problems in strabismus alignment, for example muscle transposition procedures for paresis, recessing both agonist and antagonist muscles for balancing anomalous innervation (Duane syndrome). Occasionally, adjustable suture is done to give binocular vision back to the patient with acquired deviation. If the patient has a 6th nerve palsy with partial recovery, an accurate operation must be performed and under no circumstances can excellent results be obtained unless the adjustable suture technique is used. With this technique we can also perform more than usual resection or recession without getting significant limitation of movements.³

It is also useful in cases of thyroid myopathy in which the patient has diplopia and we need accurate alignment. In such cases the globe is proptotic, the eye muscles relationship is changed and the muscles are fibrotic and contracted, making results less predictable.^{3,4}

In cases of reoperation, results are less accurate because the previous operation has changed the length of the muscles and their relationship to each other.³ In complicated cases of strabismus, such as those in which we do operations on the oblique in addition to the horizontal muscles, because of the effect of the oblique muscles on the horizontal movements of the eye, we may need to use the adjustable suture technique to get the most accurate result. Also, in cases of

Adjustable Suture in Strabismus Surgery

incomitancy, we can make a balance between alignment in the primary position and rotational positions with this technique.

PATIENTS AND METHODS

We carried out the operation on 120 patients (50 male, 70 female) between 1991 and 1994. Most of the patients were adults and teenagers with a mean age of 30 years. The youngest patient was 10 years old. 12 cases were reoperations. The patients were operated for cosmetic reasons. The degree of deviation was measured by prism cover testing before the operation. All patients had general anesthesia and other body systems were evaluated before the operation. The patients who underwent reoperation had no history of oculocardiac reflex in previous operations.

Visual acuity was checked and the operation was performed on the eye with worse acuity. In patients who had over-correction in the previous operation with full recession and resection and also in those who hadn't undergone full operation, we performed the second procedure on the previously operated eye. In patients with full recession and resection and under-correction, we had to operate on the other eye.

An accurate cycloplegic refraction was done before the operation and glasses were prescribed if necessary.

Surgical technique

In contrast to ordinary strabismus surgery, there is no need to recheck the measurements in the operating theatre just before the operation, because there are some slight miscalculations that we can compensate for during the adjustment.

After general anesthesia the globe was fixed with 6/0 silk suture. A buttonhole was made near the limbus in the conjunctiva and it was extended parallel to the limbus.

with two radial incisions, a fornix base flap of conjunctiva was made.

To isolate the muscle, the eye was maintained in the primary position as muscle hooks were passed until the entire muscle was engaged. First, a muscle hook was used to pass along the sclera under the insertion of the rectus muscle; with that in place, a second muscle hook was passed to ensure that the entire tendon has been engaged. It is easier to adjust a recessed muscle than a resected muscle, because the muscle is slack in recession and causes less discomfort for the patient, and also there is less muscular resistance; therefore adjustable sutures were applied for recessed muscles only.

No resection was done in patients with up to 25 prism diopters deviation. The least amount of resection was 5 and the maximum 10 millimeters for over 60 prism diopters of deviation.

To perform resection, after isolation of the muscle as

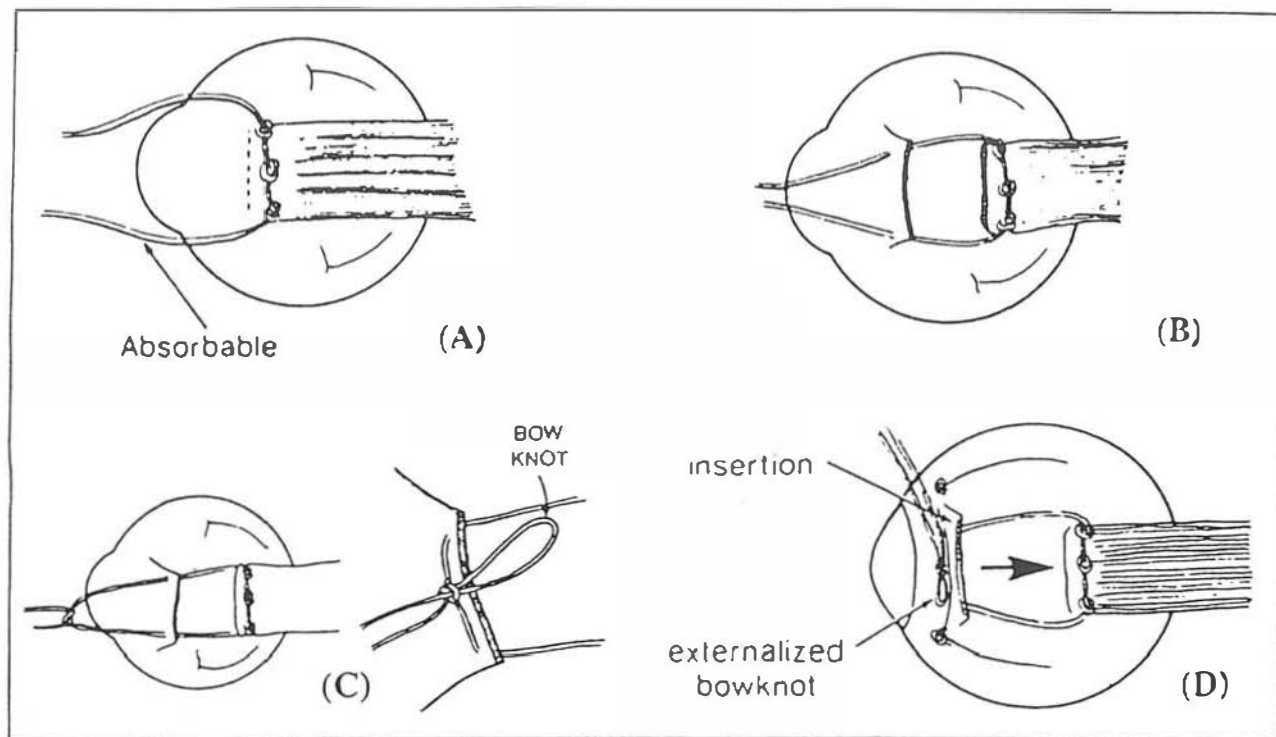


Fig. 1. The steps of the adjustable suture. Three knots have been inserted into the muscle close to its insertion (A). The muscle is disinserted and the suture passed through the muscle stump (B). The suture is tied as a bowknot (C). The conjunctiva is replaced and the knot is exposed with a rather long arm for the next morning adjustment (D).

much as possible, a caliper was used to determine the point of suture insertion into the muscle. A suture was placed at that point and 6/0 vicryl sutures were inserted in front of it. The muscle was disinserted and reattached to the previous insertion of the muscle, then the excess muscle was cut. The conjunctiva was closed by 6/0 vicryl sutures. For recession, a double armed 6/0 vicryl suture was passed through the muscle in front of the muscle hook three times and tied each time that it was passed through the muscle; then the muscle was disinserted and the two ends of the vicryl suture were passed through the muscle insertion (Figs. 1 and 2), and while the muscle was held in a position with further than necessary recession, the two ends of suture were tied in a bowknot (Fig. 3). The conjunctival flap was sutured with 6/0 vicryl sutures (Fig 4).

Some surgeons place a suture at the muscle insertion or bare sclera and make it as a loop to be used as a handle to rotate the eye the next morning during suture adjustment.⁷ We injected Healon underneath the muscle to prevent it from reattachment from the globe in 10 cases, in order to delay adherence of the cut edge of muscle to sclera.⁸

The postoperative adjustment was performed the morning after the operation. The patient should be fully alert and attentive because the alerting mechanism plays a role in oculorotary muscle active innervational force, and the patient's cooperation is required in order to perform the cover test.

Several applications of anesthetic drops are performed to give complete anesthesia to the area. An alternate cover test is done and, while regarding the present deviation, the recessed muscle is released or tightened as necessary. Surgeons who use the loose loop technique, use it for manipulation of the globe and, while trying to release the muscle, they hold the loop and ask the patient to look to the opposite side.

Finally, the eye is patched and the patient is discharged. Home care consists of topical antibiotics, corticosteroids and coverage with an eye pad.

RESULTS

All patients had horizontal deviation. Seventy had esotropia and 50 had exotropia. All had constant, comitant, monocular deviation and no patient had eccentric fixation. Because operation was performed on the recessed muscle, 70% of patients had overcorrection after the operation. During the alternative cover test after adjustment the next morning after the operation, deviation was less than 15 prism diopters in almost all cases, and it was toward esotropia (undercorrection in esotropia and overcorrection in exotropia) due to an absence of fusion—are prone to exodeviation. 90% remained unchanged while 10% who were deeply amblyopic shifted to exotropia.

The follow-up period was between 2 to 3 years and during this time no patient needed reoperation. 3 patients had local infections which resolved with topical antibiotics.

DISCUSSION

Ophthalmic surgeons continue to search for diagnostic techniques and surgical approaches that will optimize the effect of strabismus therapy. The technique of the adjustable suture performed soon after the operation was developed first by O'Connor in 1931 in order to optimize the ocular position.

This technique is mostly done for adults and teenagers, although some surgeons perform it in infants with the use of nitrous oxide to sedate the patient temporarily. The adjustable suture technique is usually done for vertical muscles but can also be performed for oblique muscles as well.⁵ This technique can be done with both local and general anesthesia. With local anesthesia, adjustment is done at the time of operation. It is inconvenient for the patient but carries a lower risk of infection. With general anesthesia, final suture adjustment is done a few hours to 24 hours after the operation. It is best to be done a few hours after operation because there is less risk of reattachment of the muscle to the globe. Some surgeons inject Healon underneath the muscle end to prevent it from reattachment to the globe. Some surgeons use the technique for both recessed and resected muscles, but we can perform resection with regard to the amount of deviation and perform adjustment on the recessed muscle only, which makes the technique easier with the same efficacy.² Anticipated patient noncompliance precludes the use of adjustable sutures. This includes the pediatric age group and certain adults, for instance patients who show poor cooperation during intraocular pressure measurement or performance of the forced duction test are generally poor candidates for postoperative suture adjustment.

The use of adjustable suture in patients who show a sensitive oculocardiac reflex during surgery is not recommended. Bradycardia or arrhythmia is difficult to manage in an ophthalmologic office during suture adjustment the morning after surgery.

Some disadvantages of the adjustable suture technique. First of all, although it is accurate, this method is associated with a lot of discomfort for the patient. Secondly it may cause an oculocardiac reflex, causing the patient to faint. Because the final part of the operation is done in the ward and outside the operating theatre, there is a higher risk of infection.

Since the muscle end is not secured to the sclera directly and it hooks like a hang-back suture, the new attachment of the muscle may not be firm enough by the time the absorbable sutures have disintegrated and the muscle may slip back (causing some surgeons to use nonabsorbable sutures). This

Adjustable Suture in Strabismus Surgery

complication happens more often when topical corticosteroids are prescribed.⁷

The problem of long is another problem involving different relevant sensorimotor relationships or long may be present in any type of surgical procedure.

In 1979 Jampolsky mentioned that various factors of the muscle such as force range (stiffness characteristic), force change with muscle length, and effective force locale (lever arm) affect the final result of the operation and as long as they cannot be estimated the final results are unpredictable and using the adjustable suture is necessary. He predicted at that time that someday in the future we would be able to estimate these parameters and there would be no more need to adjust the suture, but at this time we don't have that ability yet and the adjustable suture is therefore necessary.³

In 1977 Rosenbaum performed the operation on 55 patients with horizontal and 11 patients with vertical deviations. The average change during the follow-up period was 2.4 prism diopters for esotropia and 3.4 prism diopters for exotropia. Only one of 27 patients with XT had more than 10 prism diopters deviation and no patient with ET had more than 8 prism diopters deviation. The average change for vertical deviation during follow-up was 3.4 prism diopters.⁹

In 1979 Carlson and Jampolsky used adjustable suture in transposition operation,¹⁰ one was done in a 6th nerve palsy and the other in a patient with Duane syndrome. Half of the superior rectus and inferior rectus were transposed to the insertion adjusted and the opposing horizontal vector forces were adjusted by the surgeon to achieve a balanced primary position alignment. In 1981 Metz performed the adjustable suture technique on patients with superior oblique palsy and excyclotorsion.³ He carried out the operation which was a Harade-Ito procedure on 4 patients, with adjustment of the suture the day after the operation. In a follow-up of 2 to 20 months, all the patients remained free of torsional symptoms and no vertical deviation occurred.

What we have done on 120 patients at Feiz hospital gives further evidence that this technique is effective in the stability of postoperative alignment.

In general, when the selected goal will be harder to achieve because of unusual mechanical or innervational factors, an adjustable suture technique allows an extension of the surgical procedure to compensate for miscalculations.

With the adjustable suture technique we can correct or compensate for an undesirable ocular position by adjusting extraocular muscle insertion within the first 24 hours after operation to get the most desirable position of the eyes. Nowadays it is used for all cases of adult strabismus, as Jampolsky mentioned in 1979.

The use of adjustable suture remains a highly personal issue among strabismus surgeons. It should be mentioned that the use of the adjustable suture does not make up for deficiencies in diagnosis, surgical plan or surgical technique.

REFERENCES

1. Reinecke RD: Muscle surgery. In: Tasman W, (ed.). Duane's Clinical Ophthalmology. Philadelphia: Lippincott Publications, Vol. 5, pp. 15-17, 1990.
2. Metz HS: Adjustable suture strabismus surgery. In: Waltman SR, (ed.). Surgery of the Eye. 1st ed. New York: Churchill Livingstone, pp. 209-219, 1990.
3. Jampolsky A: Current techniques of adjustable strabismus surgery. Am J Ophthalmology 88: 406, 1979.
4. Char DH: Therapy of thyroid myopathy. In: Char DH, (ed.). Thyroid Eye Disease. 2nd ed, New York: Churchill Livingstone, pp. 209-219, 1990.
5. Metz HS, Lerner H: The adjustable Harade-Ito procedure. Arch Ophthalmol 99: 624, 1981.
6. Thorson JC, Jampolsky A, Scott AB: Topical anesthesia for strabismus surgery. Trans Am Acad Ophthalmol Otolaryngol 70: 986, 1966.
7. Reinecke RD: Extraocular muscles. In: Spaeth GL, (ed.). Ophthalmic Surgery. 2nd ed, Philadelphia: W.B. Saunders Company, pp. 669-671, 1990.
8. Metz HS: Adjustable suture techniques. In: Strabismus Surgery. Rochester, American Academy of Ophthalmology, Vol. 4, Module 1, p. 8, 1986.
9. Rosenbaum A, Metz HS, Carlson M, Jampolsky A: Adjustable rectus muscle resection surgery: a follow up study. Arch Ophthalmol 95: 817, 1977.