

Case Reports

HUGE ANEURYSM OF THE DUCTUS ARTERIOSUS IN CHILDHOOD: CASE REPORT AND LITERATURE REVIEW

MOHAMMAD HASAN KALANTAR MOTAMEDI, M.D.,
KAMAL RAISSI, M.D., AND S.M. MERAJI, M.D.*

*From the Departments of Cardiovascular Surgery and *Pediatric Cardiology, Shahid Rajai Heart
Hospital, Iran University of Medical Sciences, Tehran, Islamic Republic of Iran.*

ABSTRACT

Patent ductus arteriosus (PDA) is an open communication between the upper descending thoracic aorta and the proximal left pulmonary artery, which results from persistence of the fetal ductus arteriosus. It may be isolated or occur with other congenital cardiac anomalies.

Aneurysms of the ductus arteriosus are rare lesions which may occur as a spontaneous, infantile form or occur in later childhood or adult life. About 60 cases of ductus aneurysm have been reported in infants less than two months old, and only about 40 cases have been reported so far in adults in the world literature. In this report, a case of huge aneurysm of the ductus arteriosus in a five year old child associated with ventricular septal defect and pulmonary stenosis is presented, the first case of this kind in the literature. Successful surgical correction was performed.
MJIRI, Vol. 11, No. 1, 49-52, 1997.

Case report

A five year old boy presented with a history of easy fatigability on exertion, tachypnea, and excessive sweating which had been present since birth and was initially mild but had progressed gradually in severity. He also complained of occasional chest pain but did not have orthopnea. He had suffered from recurrent upper respiratory infections. He was the family's third child, and his siblings were normal.

On physical examination, he was an underdeveloped child. Blood pressure was 120/70 mmHg, heart rate was 100/min, and body weight was 13 kg. He had no chest deformity. A right ventricular heave and an associated thrill were present all across the precordium. On auscultation, a grade III/VI ejection-type systolic murmur was audible at the left and right sternal border. There were diminished

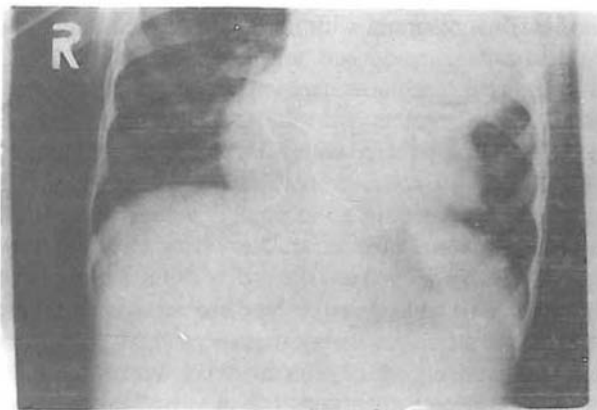

Fig. 1. Chest roentgenogram depicting a huge mass occupying the entire left upper hemithorax.

Aneurysm of PDA

Table I. Results of catheterization study.

Chamber	Pressure	O ₂ saturation	ABG
right atrium	4/7/10	49%	pH 7.33
right ventricle	140/0-12	57%	PO ₂ 50
left ventricle	120/0-5	85%	PCO ₂ 40
aorta	120/70	85%	HCO ₃ 20

breath sounds at the left upper hemithorax. He had no cyanosis or clubbing.

Hemoglobin was 12.5 g/dL and hematocrit 38%. A chest roentgenogram revealed a huge, well-circumscribed mass occupying the entire left upper lung field (Fig. 1). An electrocardiogram showed normal sinus rhythm, right axis deviation and biventricular hypertrophy. Echocardiogram disclosed a small ventricular septal defect and pulmonic stenosis with a systolic gradient of 104 mmHg between the right ventricle and the pulmonary artery. Short-axis view revealed a huge left upper chest mass and echo-Doppler demonstrated communication with the aorta (Fig. 2).

The child underwent cardiac catheterization. Right ventricular pressure was suprasystemic at 140/12 mmHg, left ventricular pressure was 120/0-5 mmHg and there was O₂ step-up at the RV level. The pulmonary artery could not be negotiated (Table I). There was a large, hypertrophied right ventricle, valvar and supra-valvar pulmonary stenosis, post-stenotic dilatation of the left pulmonary artery, a small subarterial ventricular septal defect, left aortic arch, and with injection of dye in the descending thoracic aorta on catheter pull-back, opacification of a huge mass—aneurysm of the ductus arteriosus (Figs. 3-5). The patient was scheduled for surgery.

Due to massive size of the aneurysm and associated cardiac anomalies, we obviously chose to approach the lesion via a median sternotomy incision. At operation, a huge, pulsatile mass, 15 cm in diameter, was found compressing the mediastinum and upper lobe of the left lung. After initiation of cardiopulmonary bypass and moderate hypothermia with cold cardioplegic arrest, the right ventricle was opened and prominent muscle bands were resected. The pulmonary valve was severely stenotic and a commissurotomy was done. The ventricular septal defect was then repaired with a dacron patch and the right ventricular wall was repaired with a pericardial patch. Profound hypothermia to 18°C was then instituted and during a brief period of total circulatory arrest, the aneurysmal sac was widely opened and the orifice of the aorta sutured from within with pledgeted prolene mattress sutures. There was no clot inside the aneurysmal sac, and the pulmonary end was not open, which probably led to formation of the aneurysm. Excess aneurysm wall was excised as far as adhesion of adjacent structures would allow, and rewarming and weaning from bypass was done as routine. After closure,

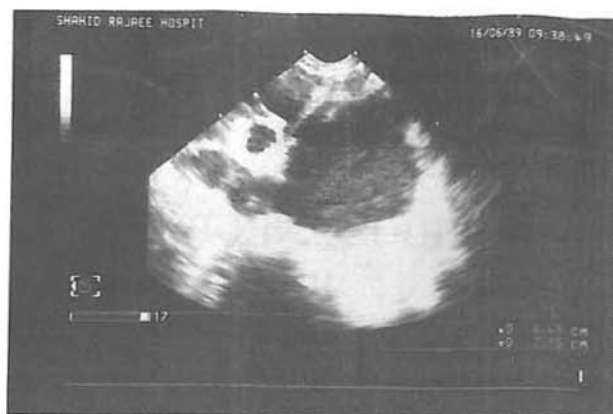

Fig. 2. Echocardiogram (short-axis view) depicting aneurysmal mass adjacent to the descending thoracic aorta and left atrium.

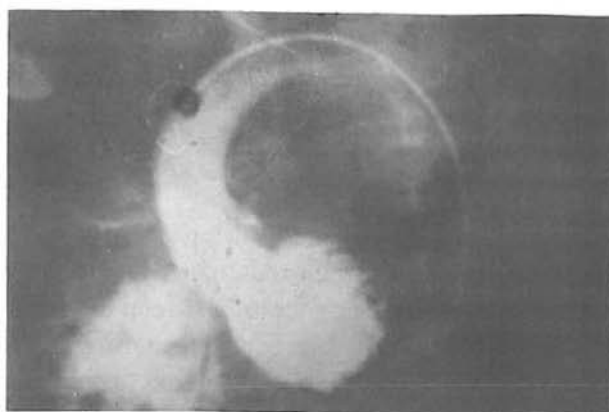


Fig. 3. Angiogram taken during cardiac catheterization (left ventricular injection) revealing dye entering right ventricle (ventricular septal defect).

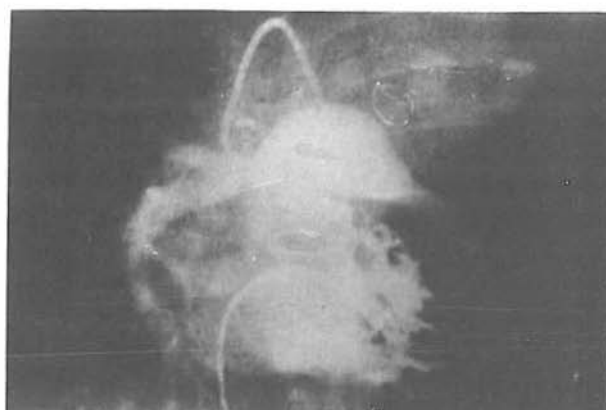

Fig. 4. Right ventricular injection demonstrating valvar and supra-valvar pulmonary stenosis and post-stenotic dilation of left pulmonary artery.

the child was taken to the pediatric surgical intensive care unit. Pathology report of the aneurysm wall was "aneurysm of ductus arteriosus showing cystic mucoid degeneration similar to that of Marfan syndrome".

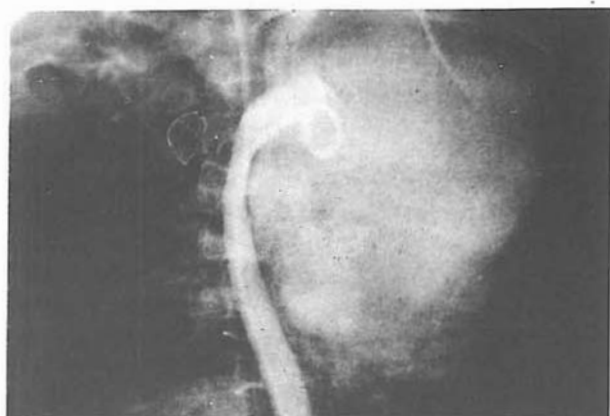

Fig. 5. Injection of dye in descending thoracic aorta revealing opacification of huge aneurysmal mass (RAO view).

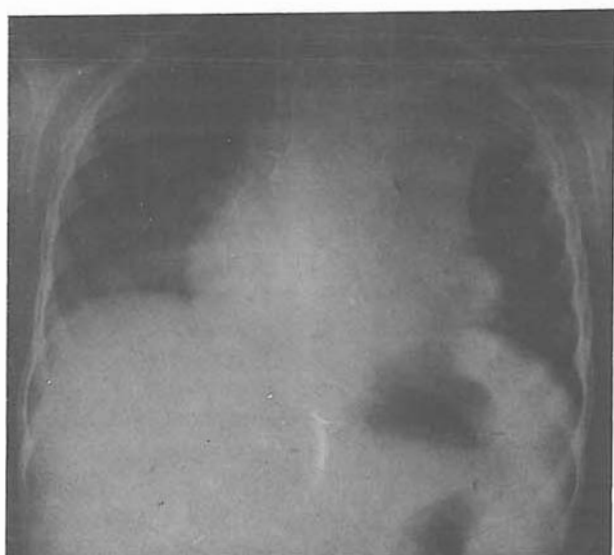


Fig. 6. Postoperative chest roentgenogram taken seven weeks after surgery revealing good lung expansion and complete resolution of mass.

Postoperative course was complicated by severe and refractory left upper lobe atelectasis which despite aggressive pulmonary toilet and bronchoscopy, resulted in a lobar pneumonia. Intravenous antibiotics and pulmonary physiotherapy finally led to clinical and radiological resolution after two weeks, and the child was discharged in good health. Chest roentgenogram taken seven weeks postoperatively revealed resolution of atelectasis and complete resolution of the mass (Fig. 6).

DISCUSSION

Postnatal closure of the ductus arteriosus occurs in two stages. The first stage, due to contraction of the smooth

muscle in the media of the ductal wall, is complete within 10-15 hours after birth in full-term infants. The second stage of closure is the result of diffuse fibrous proliferation of the intima, leading to permanent sealing of the lumen and formation of the fibrous ligamentum arteriosum within two to three weeks.¹ Thus the ductus arteriosus is completely closed in 88% of people by eight weeks of age.²

Ductal aneurysm was first described by Martin in 1827.³ Closure of the pulmonary orifice with delayed closure of the aortic orifice of the ductus exposing ductal tissue to systemic pressure was proposed by Taussig in 1947 as the most likely etiology of aneurysm formation.⁴ Indeed, closure of the ductus usually begins at the pulmonary end, and may remain incomplete at the aortic end, leaving a small diverticulum adjacent to the aorta. This infantile-type ductus aneurysm which is present at birth or develops very shortly thereafter,⁵ usually contains thrombus and occasionally is a site for infection and embolism. It presents mostly in neonates with a history of respiratory difficulty and is seen as a shadow of variable size on the posteroanterior chest roentgenogram, or may be discovered only incidentally at autopsy after death from other causes.⁶ This type of ductus aneurysm almost always regresses spontaneously within weeks or months, and very rarely requires surgical intervention due to progressive enlargement or hoarseness from recurrent laryngeal nerve involvement. In a review by Lund, et al.⁷ 64 cases of this type of aneurysm were found in the literature.

The second type of ductus aneurysm occurs in childhood or adult life and is very rare. It is thought to be unrelated to the infantile form.¹ The ductus may be patent at both ends, but the pulmonary artery end is usually closed,⁸ as in our patient. These have a greater tendency for progressive enlargement and rupture.⁹ Infection and thromboembolism are also frequent complications. Lund, et al. reported the complication rate in infants less than two months old to be 31%, in children between two months and five years old, 66%, and in adults 47%.⁷ Thus, these aneurysms should be repaired once they are diagnosed.¹⁰ Our case was particularly unusual in that it was very large and associated with VSD/PS.

REFERENCES

1. Kirklin JW, Barratt-Boyes BG: Patent ductus arteriosus. In: Cardiac Surgery. 2nd edition, Volume I, New York: Churchill-Livingstone, pp. 842-4, 1993.
2. Christie A: Normal closing time of the foramen ovale and ductus arteriosus. *Am J Dis Child* 40: 323, 1930.
3. Falcone MW, Perloff JK, Roberts WC: Aneurysm of the non-patent ductus arteriosus. *Am J Cardiol* 29: 422, 1972.
4. Kirks DR, McCook TA, Serwer GA, Oldham HN: Aneurysm of the ductus arteriosus in the neonate. *AJR* 134: 573, 1980.
5. Heikkinen ES, Simila J, Laitinen J, Lanni T: Infantile

Aneurysm of PDA

- aneurysm of the ductus arteriosus. *Acta Paediatr Scand* 63: 241, 1974.
6. Das JB, Chesterman JT: Aneurysms of the patent ductus arteriosus. *Thorax* 11: 295, 1956.
 7. Lund JT, Jensen MB, Hjelms E: Aneurysm of the ductus arteriosus. A review of the literature and the surgical implications. *Eur J Cardiothorac Surg* 5(11): 566-70, 1991.
 8. Gittenberger-DeGroot AC: Persistent ductus arteriosus: most probably a primary congenital malformation. *Br Heart J* 39: 610, 1977.
 9. Cruickshank B, Marquis RM: Spontaneous aneurysms of the ductus arteriosus. *Am J Med* 24: 140, 1958.
 10. Gaynor JW, Sabiston DC Jr: Patent ductus arteriosus, coarctation of the aorta, aortopulmonary window, and anomalies of the aortic arch. In: Sabiston DC Jr, Spencer FC, (eds). *Surgery of the Chest*. 5th edition, Volume II, Philadelphia: W.B. Saunders Co., p. 1131, 1990.