

SPLENIC HAMARTOMA: A CASE REPORT

ABDOLRASOOL TALEI, M.D.

*From the Department of Surgery, Shiraz Medical School, Shiraz University of Medical Sciences, Shiraz,
Islamic Republic of Iran.*

ABSTRACT

A rare case of splenic hamartoma in a 31 year old female is reported. She was admitted with splenomegaly, fever and chronic history of epistaxis. Routine hematological survey revealed pancytopenia and mild hypercellular marrow. Abdominal sonography showed a space-occupying lesion in the spleen which was suspected as malignant tumor. Splenectomy was performed and histologic findings were diagnosed as hamartoma. The epistaxis and pancytopenia disappeared two months after splenectomy, and at present the patient is doing well.

Keywords: Spleen, Hamartoma, Clinicopathologic

MJIRI, Vol. 11, No. 1, 57-59, 1997.

INTRODUCTION

Splenic hamartoma is a rare benign tumorous lesion. It is wrongly described under various names such as splenoadenoma, splenoma, splenic lymphoma, hyperplastic nodule, lymphangioma, hemangioma, congenital anomaly and post-traumatic scar.^{2,3,14} However, all of them are distinct entities and have no relation with splenic hamartoma.²² These tumors are usually incidental findings and are rarely of clinical importance. They are rarely associated with abnormalities such as malignancy,^{1,5,7,19,20} tuberous sclerosis, hematological problems, amyloidosis, glomerulonephritis and renal cell carcinoma. This paper describes the clinical and pathological findings of one case of splenic hamartoma associated with hematological abnormalities of anemia and pancytopenia.

CASE REPORT

A 31 year old female was admitted to Faghihi Hospital, Shiraz, with a chief complaint of fever, chills and intractable epistaxis for the past five months. The physical examination revealed petechial hemorrhages and mild splenomegaly. There was no evidence of hepatomegaly or lymphadenopathy. There was no previous history of trauma or sickle cell disease. Complete blood count revealed ane-

mia (Hb: 9 g/dL), leukopenia (WBC: 4100/mm³) with relative lymphocytosis and thrombocytopenia with rare giant platelets (50,000/mm³). Bone marrow study revealed mild hypercellular marrow with erythroid hyperplasia. Iron stores were moderately increased. The abdominal sonography revealed hypoechoic mass in the spleen. Additional studies such as CT scan and F.N.A. study were not performed. At this time the clinical diagnosis was lymphoma. Splenectomy was performed for the confirmation of clinical diagnosis. Partial splenectomy or preservation of spleen was not possible technically. The spleen was enlarged and distorted in shape, 11.5×7×10 cm and weighed about 360 gms. No accessory spleen or hilar lymph nodes were seen. Cut section showed one large soft dark brown round non-capsulated mass, 5×6×5 cm, in the hilum of the spleen. Cut surface showed a raised mass from the normal spleen parenchyma (Fig. 1). The microscopic examination revealed a well-defined mass which was separated from the normal spleen and compressing the splenic parenchyma. The mass was made-up of slit-like spaces lined by endothelial cells, which were arranged in lobules (Fig. 2). The non-tumorous part of the spleen showed hemosiderosis and extramedullary hematopoiesis. Presently the patient is doing well. The hematological abnormalities like anemia and pancytopenia have been corrected.

Splenic Hamartoma

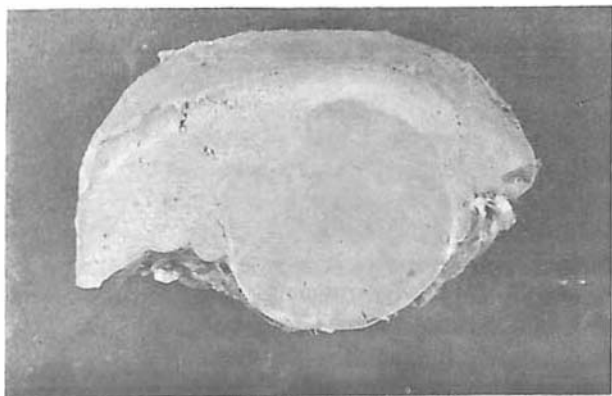


Fig. 1. Gross view of spleen shows well-defined non-capsulated mass at hilum.

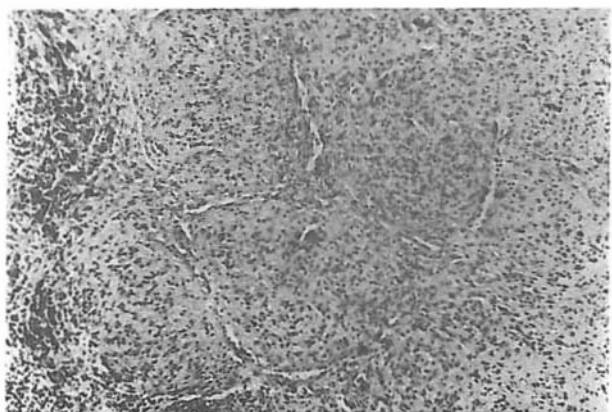


Fig. 2. Microscopic picture shows slit-like spaces arranged in lobules (Hematoxylin-eosin: 220x).

DISCUSSION

Splenic hamartoma was first described by Rokitsansky.¹⁵ So far only a few cases have been reported in the literature.^{6,10,18} They occur both in females and males in equal frequency and are found in children as well as adults. Most of them are found incidentally during autopsy or in the splenectomy specimens of Hodgkin's lymphoma. Clinical diagnosis of hamartoma without histological study is very difficult. However recently, paraclinical studies like F.N.A, CT scan, MRI, radioisotopes and radionuclide imaging have been described for the diagnosis of hamartoma.^{4,9,11,12,13,21} F.N.A. study revealed difficulties in the diagnosis of splenic hamartoma on cytology smears. CT scan and MRI studies were considered to be useful in differentiating splenic hamartoma from malignant lesions of the spleen by prolonged enhancement on post-contrast CT scan and MRI.

The pathogenesis of splenic hamartoma is still a matter

of confusion. A variety of concepts were described, like benign neoplasm, hyperplastic nodule, traumatic hamartomatous and congenital malformation. The immune and histochemical studies⁶ showed that the hamartomas were formed because of the proliferation of the sinus endothelium.

Hematological abnormalities have rarely been described.^{1,16,17,19} The exact mechanism for such complications is not clearly known. This might be due to hypersplenism caused by diseased spleen, not necessarily related to hamartoma. These lesions might be "innocent bystanders" in the diseased spleen. The histologic picture of splenic hamartoma can be mistaken with sclerosing hemangioma. However, the lobulated appearance and the absence of preexisting vessel walls are in favor of hamartoma.

The main purpose of describing this case is that the splenic hamartoma should be considered in differential diagnosis of splenomegaly.

ACKNOWLEDGEMENT

I am thankful to Dr. Kumar for providing the microphotographs.

REFERENCES

1. Beham AL, Hermann W, Wennigerhoix F, Schmid C: Hamartoma of the spleen with hematological symptoms. *Virchows Archive A: pathological anatomy and histopathology*: 414: 535-539, 1989.
2. Benjamin BI, Nohler DN, Sandusky WT: Hemangioma of the spleen. *Archives of Internal Medicine*: 115: 280-284, 1965.
3. Barge TH: Splenoma. *Acta Pathologic Microbiology Scandinavia* 63: 333-339, 1965.
4. Caslowitz PL, Labs JD, Fishman EK, Siegelman SS: Non-traumatic focal lesions of the spleen: assessment of imaging and clinical evaluation. *Computerized Medical Imaging and Graphics* 14: 13-141, 1990.
5. Dardew JW, Teeslink R, Parrish RA: Hamartoma of the spleen, a manifestation of tuberous sclerosis. *American Surgeon* 41: 564-566, 1975.
6. Falk S, Stutte HJ: Hamartomas of the spleen: A study of 20 biopsy cases. *Histopathology* 14: 603-612, 1989.
7. Ferguson ER, Sardi A, Beckman EN: Spontaneous rupture of splenic hamartoma. *Journal of the State Medical Society* 145: 48-52; 1993.
8. Iozzo RV, Hass JE, Chard RL: Symptomatic splenic hamartoma: A report of two cases and review of the literature. *Pediatrics* 66: 261-265, 1985.
9. Kumar PV: Splenic hamartoma: a diagnostic problem on fine needle aspiration cytology. *Acta Cytologica* 39: 391-395, 1995.

A. Talei, M.D.

10. Morgenstern L, Rosenberg J, Geller SA: Tumors of spleen. *World Journal of Surgery* 9: 468-476, 1985.
11. Norowitz DG, Morehouse HT: Isodense splenic mass: Hamartoma, a case report. *Computerized Medical Imaging and Graphics* 13: 347-350, 1990.
12. Ohtomo K, Fukuda H, Mori K, Minami M, Itai Y, Indue Y: CT and MR appearances of splenic hamartoma. *Journal of Computer Assisted Tomography* 16: 425-428, 1992.
13. Okada J, Yoshikawa K, Uno KL, Arimizu N, Gotou H, Ogata S, Kashiwagi Y, Hasegawa Y, Tamaru J, Mikata A: Increased activity on radiocolloid scintigraphy in splenic hamartoma. *Clinics in Nuclear Medicine* 15: 112-115, 1990.
14. Raper AB: Fibrotic nodules of the spleen. *Journal of Pathology and Bacteriology* 78: 1-16, 1959.
15. Rokintansky K: *Über splenome. Lehrbuch der Pathologie und Anatomie* Bd 3, 1861.
16. Ross CF, Schiller KFR: Hamartoma of the spleen associated with thrombocytopenia. *Journal of Pathology* 105, 62-64, 1971.
17. Schrijver inhibition of the bone marrow. *Acta Medical Scandinavia* 143: 235-237, 1975.
18. Silverman ML, Livolsi VA: Splenic hamartoma. *American Journal of Clinical Pathology* 70: 224-229, 1978.
19. Singh K, Subbramaia HA, Choudhary SR, Bhasin DK, Wig JD, Radotra B, Nagi B: Splenic hamartoma with portal hypertension: A case report. *Tropical Gastroenterology* 13: 155-159, 1992.
20. Videbaek A: Hypersplenism associated with hamartomas of the spleen. *Acta Medical Scandinavia* 141: 275-288, 1953.
21. Zissin R, Lishner M, Rathaus V: Case report unusual presentation of splenic hamartoma: Computed tomography and ultrasonic findings. *Clinical Radiology* 45: 410-411, 1992.
22. Zukerberg LR, Kaynor BL, Silverman ML, Harris NL: Splenic hamartoma and capillary hemangioma are distinct entities: Immunohistochemical analysis of CD 8 expression by endothelial cells. *Human Pathology* 22: 1258-1261, 1991.

