

## POTT'S Disease: a review of 58 cases

Mohammadreza Ehsaei, MD.<sup>1</sup>, Fariborz Samini, MD.<sup>2</sup>, Gholamreza Bahadorkhan, MD.<sup>3</sup>

*Department of Neurosurger, Ghaem Medical Center, Mashhad, Iran.*

### Abstract

**Backgrounds:** Pott's disease is a rare form of extrapulmonary tuberculosis, and presents with several clinical patterns. Delay in diagnosis and management may cause serious complications. We conducted a retrospective study between 1991-2006 to evaluate clinical presentation, radiologic and laboratory findings, and therapeutic approaches to spinal tuberculosis.

**Methods:** We reviewed clinical presentation, radiological and laboratory findings of 58 patients with spinal tuberculosis retrospectively. The diagnosis of tuberculous spondylitis was based on characteristic histology or microbiologic evidence of the disease. The results of study were recorded, and statistically analyzed by SPSS 11.5.

**Results:** The most frequent symptom was back pain (84%), with thoracic region being the most affected site (46%). Paravertebral abscess noted in 67% of cases and the average time for diagnosis was 16 months.

**Conclusions:** The 42 cases of this study underwent surgery and all were treated with drug therapy for 12 months. There was no worsening of the neurologic status in any patient. All patients with tuberculous spondylitis began to improve 3 months after chemotherapy and healed within 12 months in nonsurgical and surgical groups.

**Keywords:** Antituberculous regimen, pott's disease, spine, spondylitis.

### Introduction

The spinal tuberculosis was first described in 1782 by Sir Percival Pott [1]. It accounts for 50% of cases of skeletal TB [2] which contributes 3%-5% of all cases of TB and 15% of cases of extrapulmonary TB [3]. The incidence of neurologic involvement represents 10% to 47% of those with spinal tuberculosis [4] and there is a higher incidence of neurological involvement in the noncontiguous group [5]. Since the anterior column of the spine is primarily affected, a kyphotic deformity is often

caused [6,7]. TB spinal epidural abscess is a rare complication of Pott's disease [8]. Developments in antituberculous agents are the most important step in the management of tuberculosis, and most of the patients with spinal tuberculosis can be successfully treated with effective mediations [9]. However, there may be treatment failure because of unresponsiveness of non-compliance with antituberculous chemotherapy. Surgical intervention is sometimes indicated for the patients with severe pain from an expanding abscess, neurologic deterioration from spinal cord compression, sequestered bone and

1. Associate Professor of Neurosurgery.

2. **Corresponding author**, Associate Professor of Neurosurgery, Department of Neurosurgery, Ghaem Medical Center, P.O. Box 155 91735, Mashhad, Iran. Tel: +98 915 111 134. Fax: +98 511 8012613. E-Mail: Saminif@Mums.ac.ir

3. Associate Professor of Neurosurgery.

Age decade	Treatment modality	Kyphotic Angle Correction						Total
		30 degree	20 degree	15 degree	10 degree	5 degree	0 degree	
10-20	M	0	0	0	0	1	2	5
	S	0	0	0	1	1	0	
21-30	M	0	0	1	1	0	3	14
	S	0	4	2	1	2	1	
31-40	M	0	0	0	0	0	1	9
	S	0	3	0	2	3	0	
41-50	M	0	0	0	0	1	2	8
	S	1	1	0	1	1	1	
51-60	M	0	0	0	1	0	1	13
	S	2	3	2	2	2	0	
61-70	M	0	0	0	0	0	2	7
	S	0	1	2	1	1	0	
71-80	M	0	0	0	0	0	0	2
	S	0	2	0	0	0	0	
Total		3	14	6	10	12	13	58

M: Medical Treatment, S: Surgical Treatment

Table 1. Degree of kyphotic angle correction in all ages

disc, progressive kyphotic deformity and instability. The goals of surgery are eradication of the infection and to prevent or to treat neurologic deficits and spinal deformity [10].

Early diagnosis and treatment is mandatory to avoid complications [11]. Despite advances in diagnostic procedures, there may be delay in accurate diagnosis ranging from months to years especially in developing countries like our study. It is therefore important to maintain a high degree of clinical suspicion for Pott's disease. In this retrospectively study we decided to review a 56 case series of patients with pott's disease. This study was accomplished to specify the rate of improvement of clinical and radiological findings after treatment and to assign the percent of patients who need surgical treatment because of neurologic findings or instability. We also specified the degree of kyphotic angle correction in the two groups of patients (Patients treated with medical or surgical therapy).

## Methods

All patients with spinal tuberculosis admitted in neurosurgery department, between January 1991 and December 2006 were included in this study. 58 consecutive patients were selected by convenient sampling method and their medical records as well as their radiographs were reviewed and the demographic data recorded. This study was conducted retrospectively and patients followed for 12-18 months. The diagnosis was made according to presentations compatible with characteristic histology or microbiologic evidence of tuberculous spondylitis. The inclusion factors were spinal involvement with para clinical evidence of chronic infection and exclusion factors included patient who had previous malignant diseases and patients with signs and symptoms of acute infections.

All patients received 4 drug regimen for initial therapy in the first 3 months, including rifampin (10 mg/kg/d orally, max 600 mg), iso-

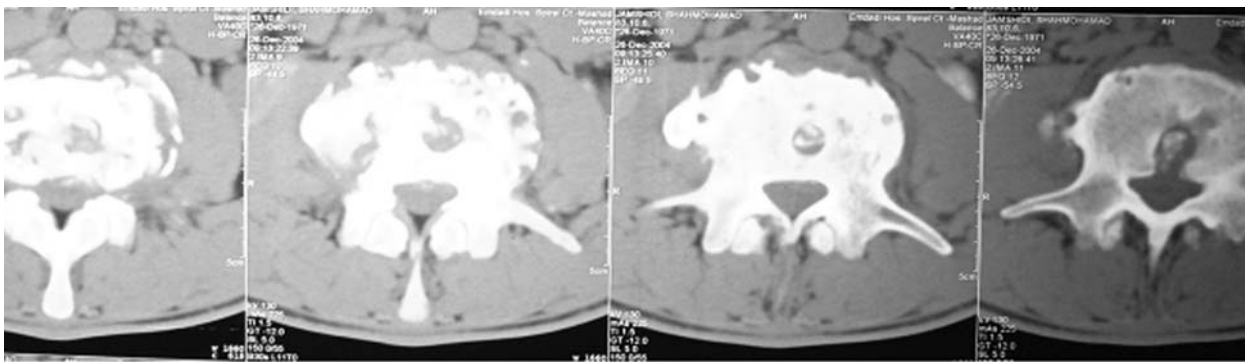


Fig. 1. A 40 years old patient with L2 destructive lesion presented with low back pain.

niazid (5 mg/kg/d orally, max 300 mg), pirazinamide (20-25 mg/kg/d orally and streptomycin (15 mg/kg/d IM route, max 1g) or ethambutol (15-20 mg/kg/d, max 1600 mg orally). This regimen was continued by INH and RIF for at least 9-12 months until ESR and CRP become normal and radiologic and clinical stabilization achieved. Follow up was done monthly up to 3 months and every 3 months up to 12 months. Follow up program consisted of clinical examination, biochemical tests, ESR CRP and CT or MRI as indicated. The mean  $\pm$  SD values or frequencies (percentage) of the characteristics were expressed, and Spss P. 11.5 used for statistical analysis.

### Results

According to reports of health and medical education ministry the incidence of tuberculosis are different in various areas of Iran. Among the 58 patients studied the most common symp-

tom was back pain 49 (84.5%), fever detected in 16(27.6%), malaise in 10(17.2%) and weight loss in 21(36.2%) of cases. In neurologic examination 37(63.8%) had paraparesis, quadripareisis was seen in 8(13.8%) cases. 26(44.8%) had sensory loss, 17(29.3%) of patients complained of sphincter problem, and nonspecific sensory loss was detected in 17(29.3%) cases. There were 28 (48.3%) male and 30 (51.7%) female who ranged in age from 5-80 years ( $41.4 \pm 12.5$ ) at the time of admission.

Surgery included anterior decompression and fusion in 24 cases (41.3%), posterolateral decompression and fusion in 7 cases (12.17%), posterior decompression with instrumentation and abscess drainage in 6 cases (10.3%), and spinal cord with root decompression in 5 cases (8.6%).

Dorsal spine was the most common site of involvement 27(46%) followed by lumbar 9(33%), thoracolumbar 6(10%), cervical

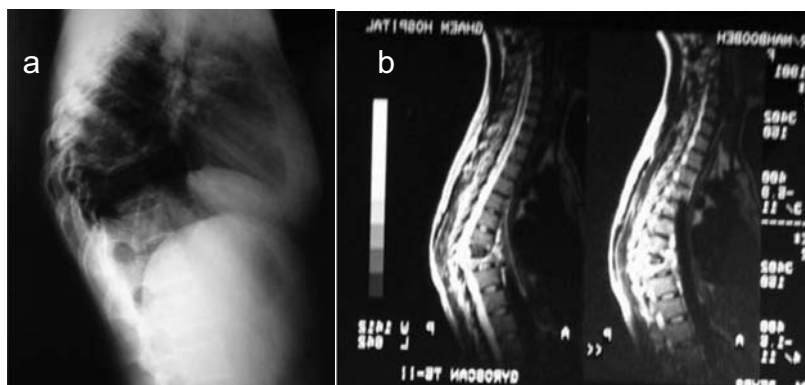


Fig. 2 . (a,b): A 45 years old woman with T9 pathologic fracture presented with spastic paraparesia .

4(7%), cerviothoracic 1(2%) and craniocervical 1(2%) (Fig 1 and 2). We found the kyphotic angle correction without considering the treatment methods according to pre and post treatment kyphosis (6 months after treatment), which mostly improved with surgery.

13 (22.4%) patients had severe spinal deformity and cord compression were detected in 33 (56.9%) cases on MRI. There was paravertebral abscess in 39 (67.2%). 31 (53.4%) had spondylodiscitis, and multisegmental involvement was noted in 20 (34.4%). 16 patients were treated only medically and the remaining 42 (72.4%) required operation. In follow up program all patients responded favorably to chemotherapy with little complication. In all cases, the tuberculous lesions began to improve in 3 months and healed within 12 months among-surgical and non-surgical groups. Patients with paraparesia and quadriparesia recoverd but 10(19%) had some degree of paraparesia; and kyphotic deformity remained in 12(20.6%). The drug side effect was detected in 4(6.9%).

### Discussion

Approximately 25-30% of patients with tu-

berculosis have extrapulmonary involvement with the skeletal system as the most common site and spinal column as the most affected organ in this system [12]. The tuberculous spondylitis is the most serious form of osteoarticular TB [13].

The HIV pandemy has coincided with a sharp rise in the incidence of TB [14], However in our study, TB epidemiology was unrelated to AIDS.

The mean age of spinal tuberculous infection is reported to be 40 to 45 years [14], similar to results of this study. A high degree of clinical suspicion of tuberculous spondylitis lead to early diagnosis and treatment but there may be a diagnostic delay that may last for many years [15] however in our study the mean diagnostic delay lasted 16 months. In the Faraji et all's patients the mean age was 42.5 years and 75% patients presented with paraparesis[16].

Patients with tuberculous spondylitis usually do not have the constitutional symptoms associated with pulmonary TB. In Polly's study , 18% of patients had fever , 53% back pain and 37% neurological involvement [5] . In our study malaise was detected only in 6(10%), and

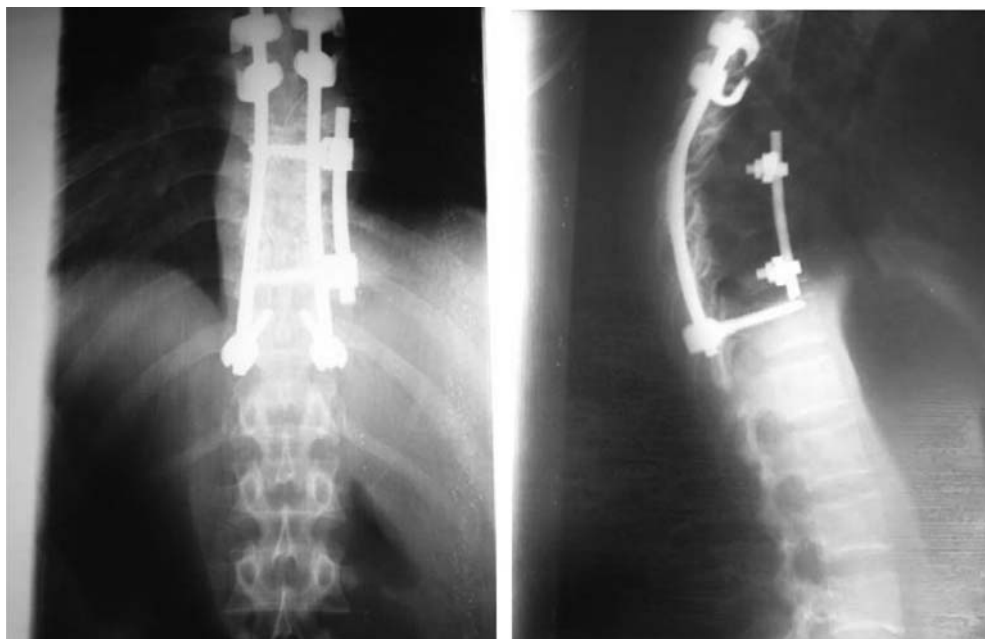


Fig. 3. (a), (b): A 45 years old woman with Pott's disease operated circumferentially for T9 pathologic fracture.

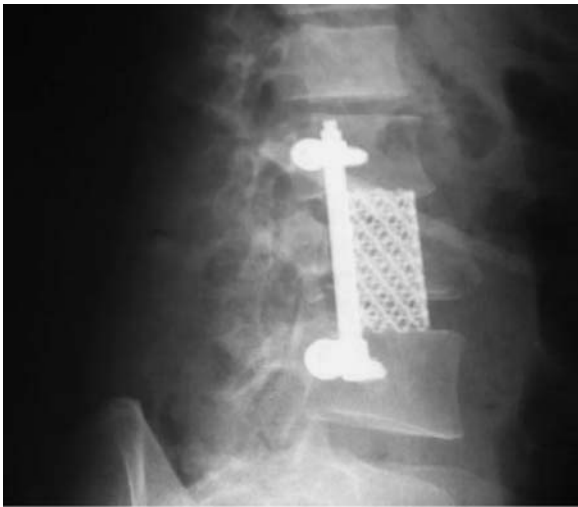

Fig. 4. A 38 years old man with pott's disease is undergone L3 corpectomy and fusion with mesh cage and anterior rod.

fever in 9(15.5%) of cases. However, back pain and localized spine tenderness, are important findings which lead to better diagnosis [17]. Back pain with initially normal roentgenograms is the earliest and most common symptom and patients have usually had back pain for weeks before presentation [13]. In our cases, back pain was presented in 49(84%). The frequency of neurologic involvement has been found in 10% to 76% of patients (18,19) . We had 36(63%)

paraparesis and 7(13%) quadriparesis in this study .

The tuberculous spondylitis most often affects the lower thoracic and upper lumbar region of the spine which comprises 60% to 90% of cases in Nasbaum,s study [20] . In our series upper and middle thoracic involved in 37% , thoracolumbar 26%, lumbar 19%, lower cervical 10% , lumbosacral 5% and upper cervical 3% of cases. In tabatabai study there were 6 complications in a series of 125 cases which operated anteriorly, and no increased kyphotic deformity occurred [21].

Although surgical treatment of spinal tuberculosis remain controversial, it has been shown that radical debridement surgery produces best results, when compared with other treatment modalities[5,7] . Based on the results from a series of studies [17,18] especially the excellent results from Mc Flain and Hong Kong group, the British medical council recommended that spinal tuberculosis was best treated with appropriate antituberculous chemotherapy and radical debridement surgery if adequate surgical anesthetic and nursing expertise and supportive facilities were available. The surgical treatment provides much earlier healing, quicker pain re-

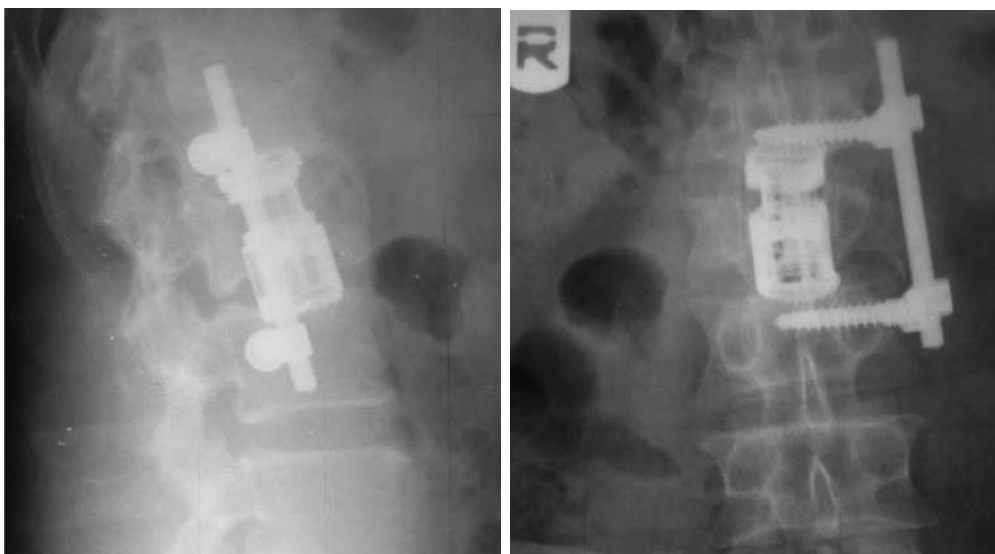


Fig. 5. (a, b): A 35 years old patient with pott's disease operated retroperitoneally for L2 corpectomy and fusion with corpectomy expandable cage and anterior rod.

lief, earlier abscess and sinus tract resolution, better chance of neurologic recovery, as well as lesser degree of spinal deformity than medical treatment.

In cases of spinal cord and root compression, spinal instability, failure of medical treatment or large soft tissue masses, we considered operative treatment. In cases of anterior bony destruction and compression (n=24), we performed anterior decompression and fusion. We also used the postero-lateral decompression and fusion technique in 7 cases, posterior decompression and instrumentation in 6 cases and spinal cord and root decompression in 5 patients (Figs. 3-5).

The rational modality of treatment is combination of both medical and surgical treatment [19,20], and the decision making should be individualized for each case, depending on the stage of the disease. Successful management is based on an early and complete diagnosis accompanied by modern imaging methods in addition to the patient's medical history, epidemiologic investigation, clinical and neurologic examination, laboratory tests and biopsy of the affected vertebrae. The treatment of TB is curative, if diagnosed early and if the organism remains sensitive to first-line anti tuberculous drugs [22].

Lotfinia found that anterior approach is more effective than posterior approach for correction of kyphosis.[23].

### Conclusion

Several approaches are used in the management of the patients with Pott's disease. These ranges from conservative regimens as bed rest and drug therapy HRZE, for about 12 months, and surgical procedures. In our study, medical therapy used in 16 patients but 42 cases had surgical therapy. There was no worsening of the neurologic status in any patient but 42 cases needed surgery because of neurological findings. In all patients, nonsurgical and surgical groups, tuberculous lesion began to improve 3

months after chemotherapy and healed completely within 12 months. The correction rate of kyphotic angle was more in group treated with surgical modality. This rate was also increased more in group with instrumentation than the other group without any instrument in their surgery.

### Acknowledgment

We would like to express our appreciation to the Vice-chancellor for research of Mashhad University of Medical Science for supporting this study.

### References

1. Gors ej, Pais MJ, Kusske JA, cesario TC, tuberculous spondylitis, A report of six cases and review of the literature, *Medicine ( Baltimore)*, 1983 ; 62: 178-93.
2. Davies PD, Humphries MJ, Byfield SP Nunn AJ, Derbyshire, HJ, citron KM, foxw. Bone and joint tuberculosis. A survey of notification in England and Wales, *J Bone joint surg Br*, 1984; 66:326-30.
3. Alvarez s, McCabe WR, Extrapulmonary tuberculosis revisited: A review of experience of Boston city and other hospitals, *Medicine (Baltimore)*, 1984; 63: 25-55 .
4. Hodgson AR, Skinsnes Ok, Leong JCr, the pathogenesis of pott's paraplegia, *J Bone Joint surg Am*, 1967; 49:1147-56 .
5. Polly P, Dunn R. Noncontiguous spinal tuberculosis: Incidence and management. *Eur.Spine J* .2009; Apr.9.
6. Tuli SM. Severe kyphotic deformity in tuberculosis of the spine. *Int Orthop* 1995; 19:327-31.
7. Yusof MI , Hassan E , Rahmat N , Yunus R. Spinal tuberculosis: The association between pedicle involvement and anterior column damage and kyphotic deformity. *Spine* 2009; Apr.1:34(7): 713-7.
8. Alg Vs, Demetriades AK, Naik S, Gunasekera L. Isolated subacute tuberculosis spinal epidural abscess of cervical spine: A brief report of a special case. *Acta Neurochi(Wien)*. 2009; Mar 20.
9. Medical research council working party on tuberculosis of the spine. Controlled trial of short-course regimens of chemotherapy in the ambulatory treatment of spinal tuberculosis, result at three years of a study in Korea, *J Bone Joint surg*, 1993; 75: 240-8 .
10. Hodgson AR stokes FE. Anterior spinal fusion the treatment of tuberculosis of the spine: the operative findings and results of treatment in the first one hundred cas-

es, *J bone Jiont surg Am*, 1960; 294-310 .

11. Davidson PT, Horowitz I. Skeletal tuberculosis: a review with patient peresentions and discussion. *Am J Medicine*, 1970; 48:77-84.

12. Aminzade ,Akhyani H. Clinical manifestations of extrapulmonary tuberculosis in Loghman Hakim Hospital . *Tabib-Sargh, Journal of Zahedan university of medical sciences and health services*, 2006; 4(7): 288-283.

13. Ansari S, Ashraf AN, Al Moutaery, Spinal infection: a review *Neurosurg Quarterly* , 2001; 11:112-123 .

14. Nas K.Kemaloglu MS, Cerik R,etal. The results of rehabilitation on motor and functional improvement of the spinal tuberculosis. *Joint Bone spine*, 2004; 71:312-316.

15. Fanning A, tuberculosis: 6: Exterapulmonary disease. *CMAJ*.1999; 160:1597-1603.

16. Faraj M,Haghi Z,Ariamanesh A. Evaluation of neurological deficits and surgical treatment of patients with Pott's disease . *Medical journal of mashhad university of medical sciences*. 2007; 94: 413-420.

17. Wisneski RJ. Infectious disease of the spine, diagnostic and treatment considerations, *Orthop clin North Am*, 1999 ; 22:491-500 .

18. Mc flain RF, Isada C, spinal tuberculosis deserves a place on the radar screen. *Cleveland clin J Med*. 2004; 71:537-548.

19. Alothman A, memish ZA, Wada A, et al. Tuberculosis spondylitis. Analysis of 69 cases from Saudi Arabia. *Spine* 2001; 26: 565-570.

20. Nussbaum ES, eockwold GL, Bergman TA, et al. Spinal tuberculosis: a diagnostic and management challenge. *J Neurosurgery*, 1995; 83:243-247.

21. Tabatabai SM, Mohseni M. Surgical management of spinal tuberculosis using anterior approaches: Areview of 125 cases. *Iranian journal of medical sciences*: 1995; 2 : 13-18.

22. Iseman Md, *A clinician's Guide to tuberculosis*, Philadelphia: Lippincott, Williams and Wilkins; 2000.

23. Lotfinia Iraj ;Hosainpoor Hojat and ect. Compare of surgical approaches in spinal tuberculosis. *Ofoghedanesh* 2005 ; vol 11 .