

## A NEW MODIFIED SURGICAL APPROACH IN LYMPHEDEMA OF THE PENIS AND SCROTUM

H. HODJATI, M.D., AND A.A. KHEZRI, M.D.

*From the Department of Surgery, Faghihi Hospital, Shiraz University of Medical Sciences, Shiraz,  
Islamic Republic of Iran.*

### ABSTRACT

A 14 year old boy suffering from marked penoscrotal lymphedema is reported. Reduction scrotoplasty was done and the neoscrotum was made by combining the anterior suprapubic and posterior scrotal U-shaped flaps. A split-thickness skin graft from the thigh was placed over the denuded penis. No complication was encountered and the cosmetic result was satisfactory.

*MJIRI, Vol. 10, No. 2, 113-115, 1996.*

### INTRODUCTION

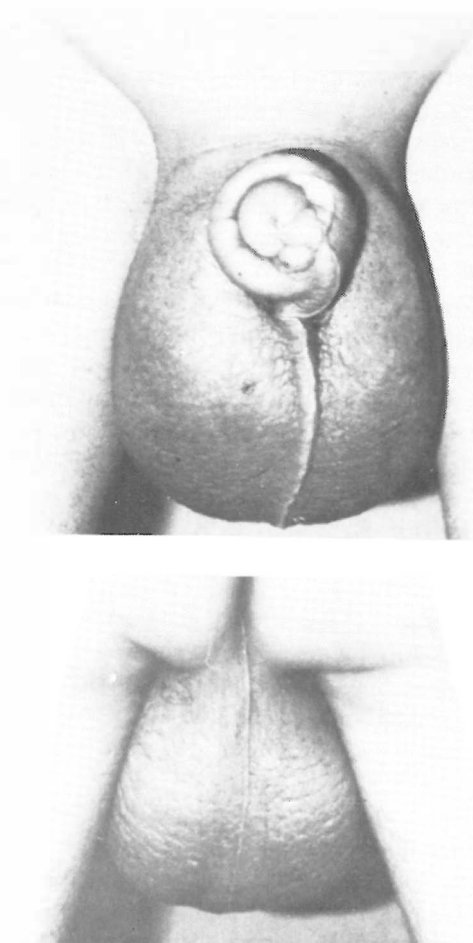
Penoscrotal lymphedema may be idiopathic or secondary to inflammation, surgical incision, neoplasm, radiation, hypoproteinemia and other medical conditions. Lymphedema of the penis and scrotum is uncommon in countries where filariasis is not endemic. In penoscrotal lymphedema blockage of the lymphatics is confined to the penis and scrotum and is not seen in adjacent areas of the abdomen, buttocks or legs. Marked elephantiasis of the scrotum is a characteristic finding in bancroftian filariasis, in which the presence of filarial parasites in the lymphatics elicits an inflammatory response.

Lymphedema of the penis and scrotum has significant functional, cosmetic, psychological and possibly malignant consequences for affected patients. The accepted form of treatment is surgery, since conservative medical treatment is of little value.

We report a case of primary penoscrotal lymphedema with excision of all involved lymphedematous tissue of the penis and scrotum and use of posterior scrotal flaps and superiorly-based flap of the pubic area for testicular coverage and split-thickness skin graft to the penis. The low morbidity and successful outcome observed in this case and those reported by others<sup>4</sup> indicate that the procedure described herein can be suitable for patients with genital lymphedema.

### Case report

A 14 year old boy was admitted with marked scrotal and penile enlargement for 6 months. He complained of penoscrotal swelling accompanied by itching, and walking



Figs. 1,2. The anterior and posterior appearance of a 14 year old boy with scrotal edema.

discomfort. On physical examination he had marked lymphedema of his penis and scrotum, and the glans penis was found to be buried in the lymphedematous penile tissue. The scrotal mass measured 30×32×34 cm (Figs. 1,2).

Necessary relevant laboratory investigations were in the range of normal limits. Abdominal and scrotal sonography was done, and testicles were normal in size and shape. He had no history of travelling to endemic areas for filariasis.

### Technique

A modified Erdem-Yourmuk procedure for reconstruction of the penis and scrotum was applied as follows. With the patient in a modified lithotomy position with the thighs abducted, the abdomen and thighs were prepared completely as potential skin graft donor sites. After placing an indwelling urethral catheter, we excised the lymphedematous mass with a U-shaped incision. Two lateral incisions were carried out through apparently healthy skin on either side of the median raphe encircling the root of the scrotum to meet at the perineum 6 cm in front of the anterior margin of the anus. A curved suprapubic incision was made 2 cm above the penile base. The penile skin was totally excised down to Buck's fascia and the denuded penis was passed through the button hole made on the middle part of the anterior flap prepared from the skin of the suprapubic region (Fig. 3). The neo-scrotum was made by anterior and posterior flaps and the penis was covered by split-thickness skin graft from the thigh. A vacuum drain was put in pouches prepared for the testicles. The specimen consisted of a mass of edematous tissue measuring 20×30×10 cm which disclosed thickened, rough skin and weighed about 2.40 kg.

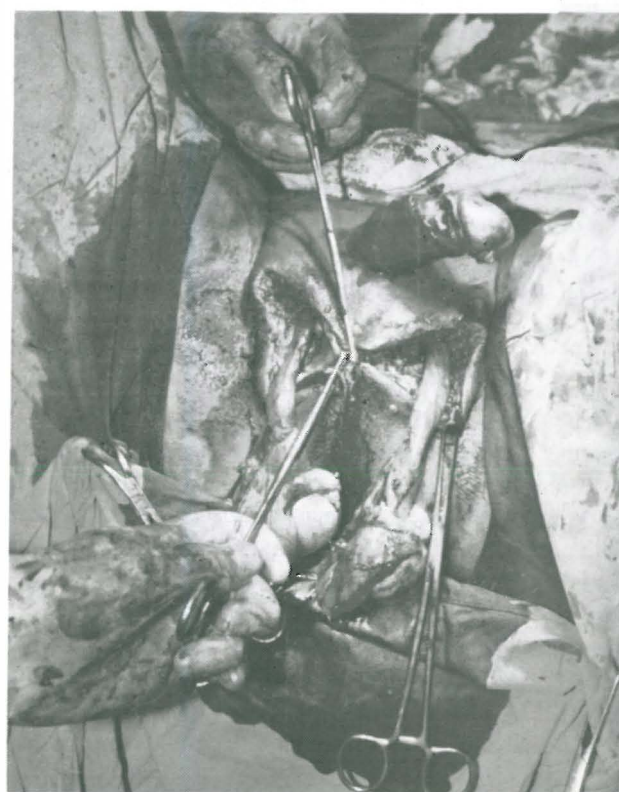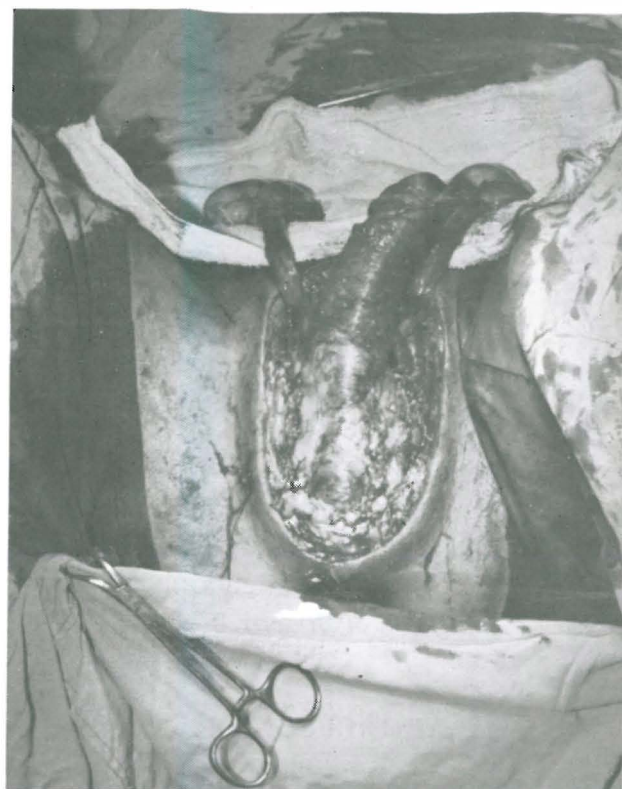Pathology report was scrotal subcutaneous and soft tissue lymphatic dilatation and lymphedema.

The dressing on the grafted area of the penis was removed on the fourth day and the urinary catheter was removed on the seventh postoperative day. The functional and cosmetic results of the operation were successful.

### DISCUSSION

Lymphedema of the external genitalia and extremities has been a subject of great interest since ancient times. An Indian surgeon, Shusruta, was the first to perform excisional surgery in genital lymphedema at around 600 BC.<sup>1</sup> Different surgical techniques have been described with different outcomes.<sup>4-6, 8, 10-12</sup>

Chronic lymphedema of the scrotum and penis is encountered quite frequently in India and in the tropics. Most often, the disease is due to filarial infestation, although a few cases may be due to certain other causes (primary, trauma, irradiation). In filariasis there are major differences in the clinical presentations, most commonly seen in *W. bancrofti* versus Brugian infection. In the bancroftian type,



**Figs. 3,4.** Intra-operative view.

Both testicles and spermatic cords are secured during excision of lymphedematous tissues, and button hole for the penis with posterior U-shaped flaps are shown.

the acute episodes most commonly affect the male genitalia with marked scrotal lymphedema. In Brugian filariasis, lymphedema of the extremities is more common than in the bancroftian type. In Iran, filariasis has not been reported to date and the pathology report of the presented case was not consistent with filarial infestation.

Delpech<sup>3</sup> in 1828 excised subcutaneous tissues of the scrotum and penis and created skin flaps to cover the penis. Early poor results were due to inadequate removal of subcutaneous tissues.

In 1993, Muller and Jordan proposed covering the denuded shaft with a split-thickness skin graft and the testicles by means of a posterior scrotal flap after excision of the lymphedematous tissues.<sup>9</sup> A few authors placed the testicles in subcutaneous pouches created bilaterally at the medial thigh, but these pouches also failed to preserve thermoregulation.<sup>2,8</sup>

Jones and Khan found that pedicle flaps from the thigh for neoscrotum reconstruction led to disturbed spermatogenesis due to higher temperatures, and they advocated using the remaining posterior scrotal tissue for covering the exposed testicles.<sup>6</sup>

Neilubrowicz and associates created lymphatico-venous shunts to return lymph to the venous circulation.<sup>10,13</sup> In patients with secondary lymphedema, they reported considerable improvement. In patients with primary lymphedema however, only 50% showed even modest improvement.<sup>7</sup>

Bringing healthy lymphatics to the diseased area is another surgical approach,<sup>5</sup> but Kinmonth, Danese and others found that omental grafts into the scrotum have been unsuccessful in draining genital lymphedema.<sup>7</sup> We conclude that excisional therapy is the treatment of choice. If enough subcutaneous tissue is removed and because "The best medium for the integrity of spermatogenesis is the normal scrotal location"<sup>4</sup>, we made a neoscrotum by a modified Erdem-Yourmuk approach (anterior flap incision located 2 cm above the base of the penis). By this procedure, the relocation of the penis to its original location helps regain its normal erectile function and does not interfere with testicular function, while providing more suitable skin coverage for reconstruction of the neo-scrotum.

## REFERENCES

1. Bhishagratna KKL: An English translation of Shusruta Samhita, based on the original Sanskrit text. Vol 2, Varanasi, India: Chowkamba Sanskrit Series Office, pp. 439-449, 1963.
2. Bruner JM: Traumatic avulsion of skin of the male external genitalia. *Plast Reconstr Surg* 6: 334, 1950.
3. Delpech JM: *Chirurgie clinique de Montpellier*. Vol. 2, Paris, Montpellier, 1828.
4. Erdem YK, Kutlu SN, Murat EU, et al: A new surgical approach in genital lymphedema. *Plast Reconstr Surg* 86: 1194-1197, 1990.
5. Goldsmith HS, De Los Santos R: Omental transposition in primary lymphedema. *Surg Gynecol Obstet* 125: 607-611, 1967.
6. Jones HW, Khan RA: Surgical treatment of elephantiasis of the male genitalia. *Plast Reconstr Surg* 46: 8, 1979.
7. Kinmonth JB, Taylor GW, Tracy GD, et al: Primary lymphedema: clinical and lymphangiographic studies of a series of 107 patients in which the lower limbs were affected. *Br J Surg* 45: 1-15, 1957.
8. May H: Reconstruction of scrotum and skin of penis. *Plast Reconstr Surg* 6: 134, 1950.
9. Muller GP, Jordan CG: Elephantiasis nostra. *Ann Surg* 97: 226, 1933.
10. Neilubrowicz J, Olszewsky W, Sokolowski J: Surgical lymphovenous shunts. *J Cardiovasc Surg* 30: 10-18, 1962.
11. Midioglu H, Barutcu A, Karademir S, Atabey A: Primary lymphedema precox of the penis and its surgical treatment—a case report. *Turk J Pediatr* 34 (4): 259-63, 1992.
12. Carlino A, Calzavara PG: Persistent lymphedema of the penis and scrotum after recurrent episodes of cellulitis and urethritis caused by *Chlamydia trachomatis*. *G Ital Dermatol Venereol* 124 (6): 303-5, 1989.
13. Huang GK: Microsurgical therapy of lymphedema of the external female genitalia. *Geburtshilfe Frauenheilkd* 49 (10): 876-80, 1989.

