

## Original Articles

# A NEW APPROACH TO VESICoureTERAL REFLUX PERSISTING AFTER POSTERIOR URETHRAL VALVE ABLATION USING GIL-VERNET ANTIREFLUX TECHNIQUE\*

NASSER SIMFOROOSH, M.D.

*From the Department of Urology, Shahid Labbafi Nejad Medical Center, Shahid Beheshti University of Medical Sciences, Tehran, Islamic Republic of Iran.*

### ABSTRACT

Classic antireflux procedures on children with a history of posterior urethral valve does not usually yield good results and often ends up with ureteral obstruction and even permanent urinary diversion.

From 1981 through 1988, 21 boys with history of posterior urethral valve (PUV) underwent evaluation for vesicoureteral (VU) reflux; 17 boys had VU reflux. Following valve ablation, reflux disappeared in nine cases. Eight boys continued to have reflux (average follow up after valve ablation was 17 months). The grade of refluxes was IV or higher in all of the cases. Gil-Vernet antireflux procedure was performed in these boys. VU reflux disappeared in 11 of 12 refluxing ureters in these eight boys postoperatively. An excellent success rate (91.7%) was seen without upper tract deterioration in any of the cases. Average follow up was six months with the longest being 13 months. This is the first report of the application of Gil-Vernet antireflux technique in persistent reflux following valve ablation and seems a breakthrough in management of PUV refluxes, eliminating the need for preliminary diversion as performed in the past.

We recommend this simple, highly effective approach as the procedure of choice in management of VU refluxes following valve ablation in children with PUV.

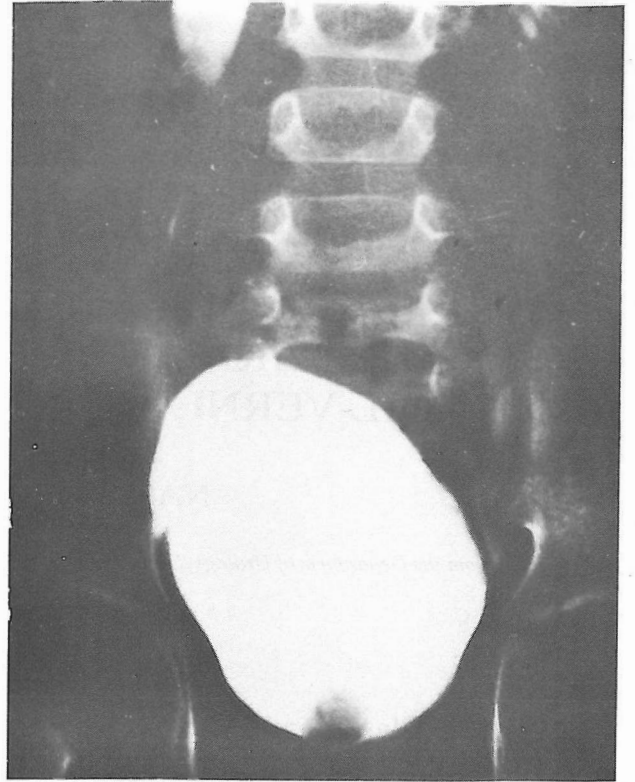
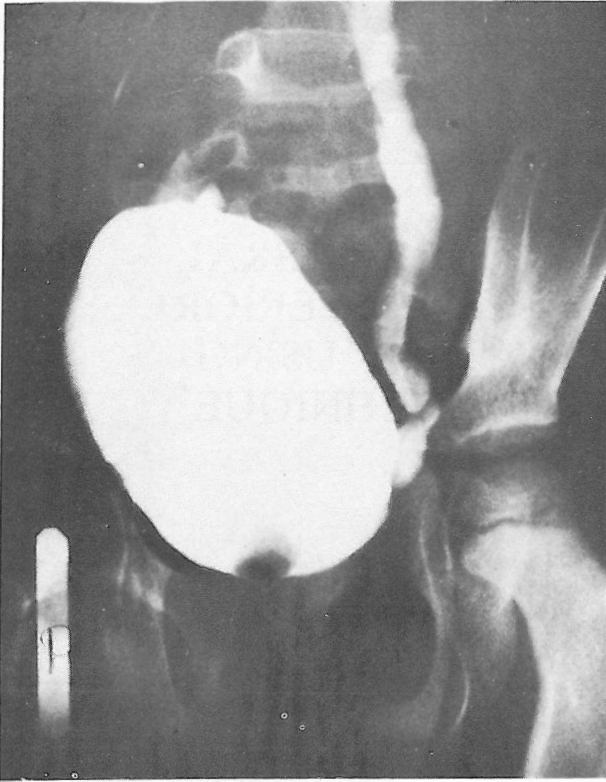
*MJIRI, Vol.2, No.4, 249-254,*

### INTRODUCTION

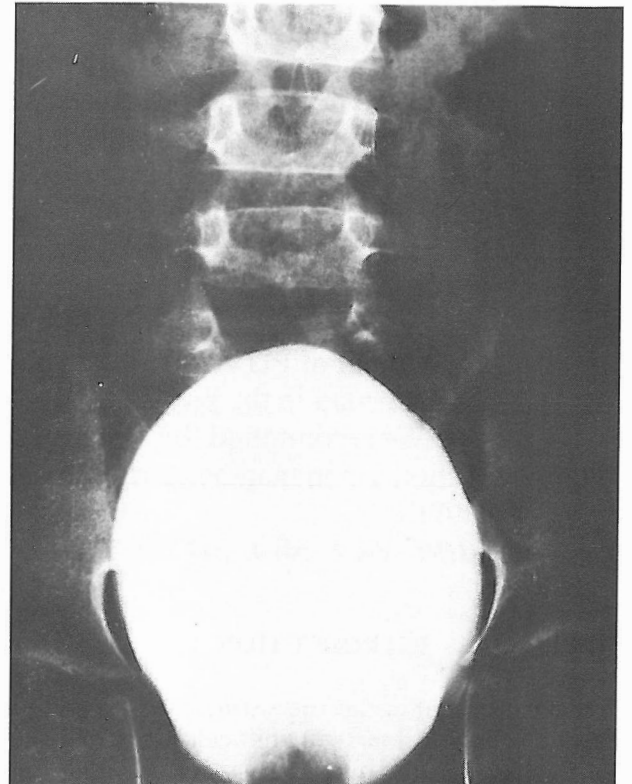
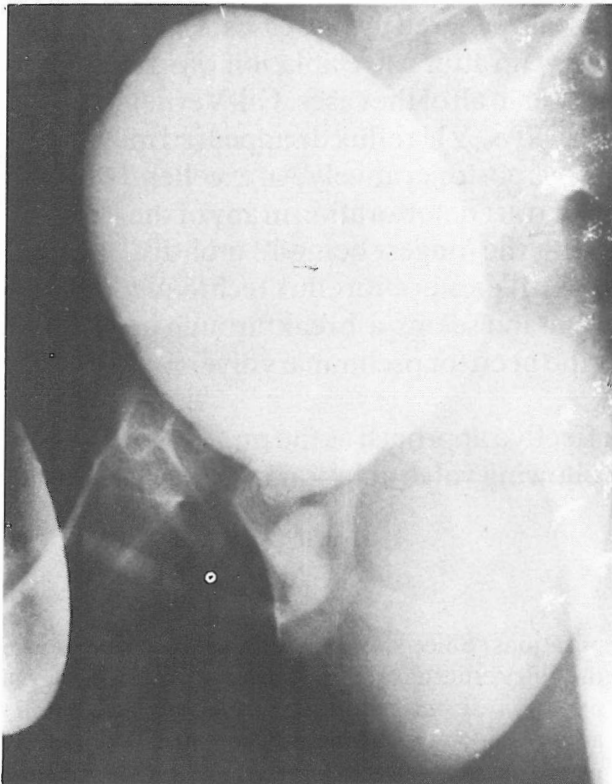
Management of reflux persisting after posterior urethral valve ablation is still a difficult problem.<sup>3</sup> The result of classic ureteroneocystostomy operations in this condition has been associated with serious com-

plications. Since we observed excellent results using the Gil-Vernet antireflux procedure even in high grade primary vesicoureteral (VU) refluxes,<sup>2</sup> we decided to apply this simple technique in those VU refluxes persisting after valve ablation in children with posterior urethral valve (PUV).

\* Presented at the XXI Congress of the International Society of Urology, Buenos Aires, Argentina, Oct. 9-14, 1988.



**Fig 1A.** Voiding cystourethrogram (VCUG) demonstrating grade IV bilateral VU reflux in four-year-old boy following resection of posterior urethral valve.



**Fig 1B, C.** Vesico-ureteral reflux disappeared following simple Gil-Vernet antireflux procedure (one year postoperative VCUG).

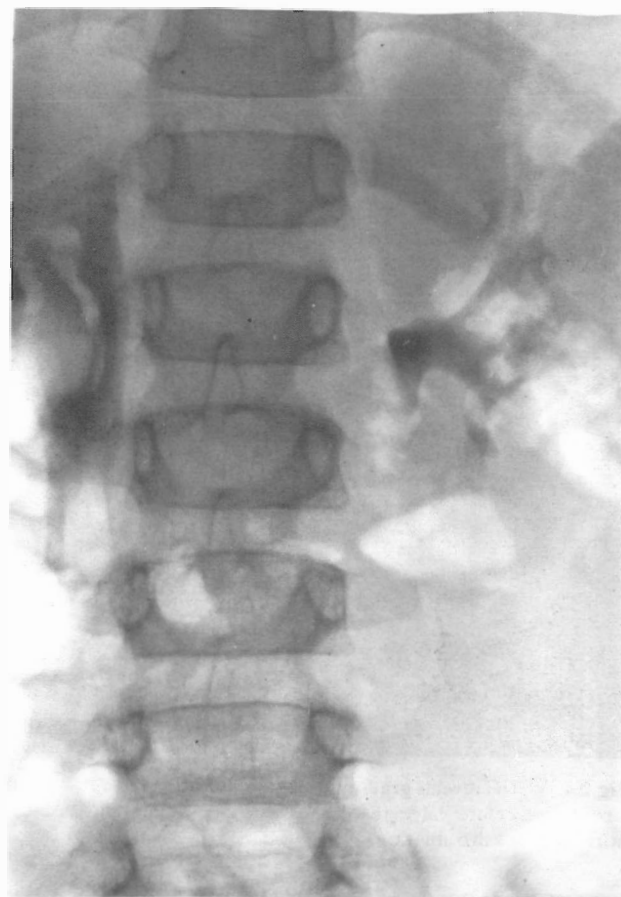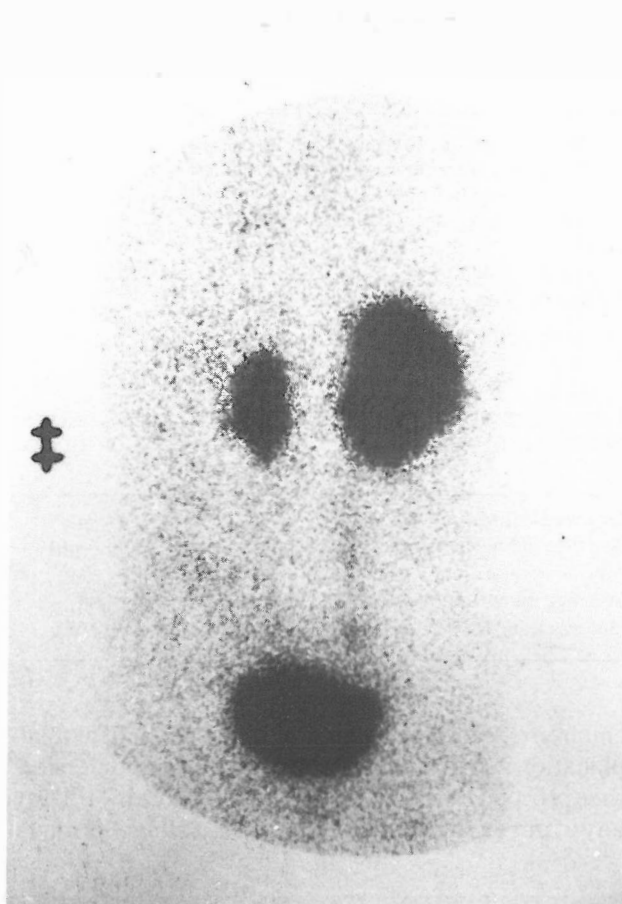


Fig 1D. Isotope renal scanning and IVU reveal improved renal function bilaterally with no obstruction.

**PATIENTS AND METHODS .**

From 1982 through 1988, 21 boys with posterior urethral valve were evaluated for presence or absence of VU reflux. Of these 21 children, 17 had VU reflux. Following transurethral valve resection, VU reflux stopped in nine of the 17 cases. VU reflux continued to be present in 8 cases despite valve ablation and good urine flow for an average follow up of 17 months (longest 3 years, Table I, II).

Gil-Vernet antireflux procedure was performed in eight of these cases with 12 refluxing units. Age of the children was between 1-5 year old. The grade of reflux was IV or higher in all of these cases (Table III). These patients were followed postoperatively by voiding cystourethrogram, renal isotope or IVU or renal ultrasound, BUN and creatinine levels. Average follow up time between valve resection and Gil-Vernet antireflux procedure was 17 months.

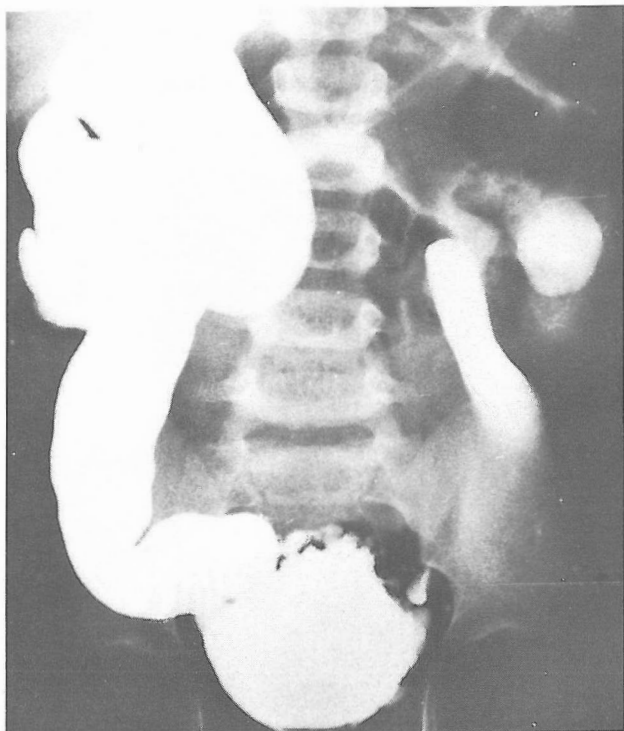
**RESULTS**

Postoperative voiding cystourethrogram revealed the disappearance of reflux in 91.7% of the cases (Fig.1,2,3). BUN and creatinine was normal in all of the

cases and fever stopped in all of the patients with history of recurrent fever. No upper tract deterioration was seen in any of the cases while considerable improvement is noted following valve resection and antireflux procedure in some patients (Fig.1D). One patient continued to have high fever and pyelonephritis following valve ablation which did not respond to antibiotics and even prolonged drainage, so we decided to perform antireflux technique one month after ablation in contrast to our usual long waiting time between valve ablation and Gil-Vernet antireflux procedure. Right after the procedure the patient's intractable fever stopped. Our follow up has been satisfactory (Table II, III) with an average follow up of six months (the longest 13 months). All boys are growing well, free of fever and have normal creatinine levels.

**DISCUSSION**

Ureteroneocystostomy in PUV refluxes with difficult bladders has been fraught with complications.<sup>3</sup> Many have resulted in ureteral obstruction at the bladder hiatus resulting in permanent diversion for some



**Fig 2A.** VCUG reveals grade V reflux 3 years after valve resection. Creatinine before valve resection was 5.5mg/100ml and became normal after valve ablation.

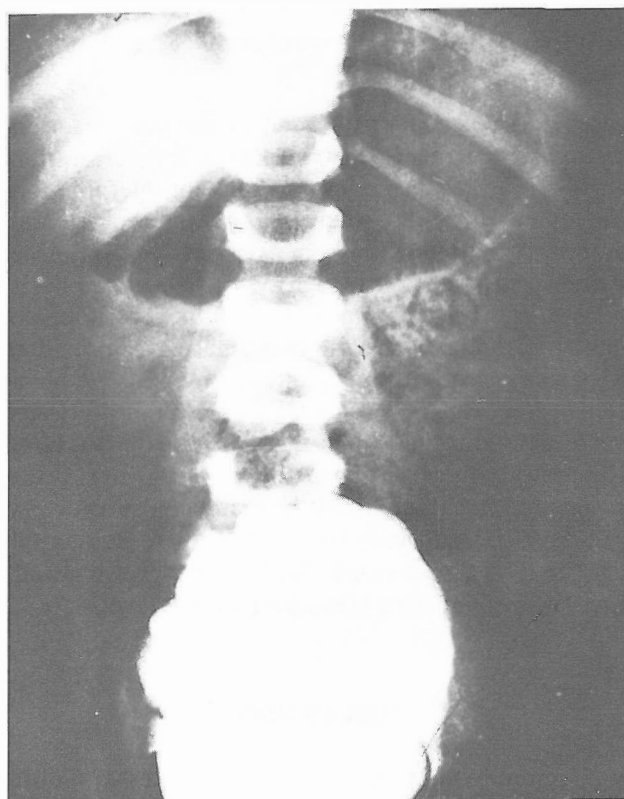
**TABLE I. GIL-VERNET ANTIREFLUX PROCEDURE IN EIGHT BOYS WITH VU REFLUX PERSISTENT FOLLOWING VALVE ABLATION.**

Reflux present before valve ablation	17
Reflux disappeared after valve ablation	9
Reflux continued after valve ablation	8
Gil-Vernet Antireflux procedure	8
Age	1-5 years old
reflux stopped	8
Success Rate	91.7%

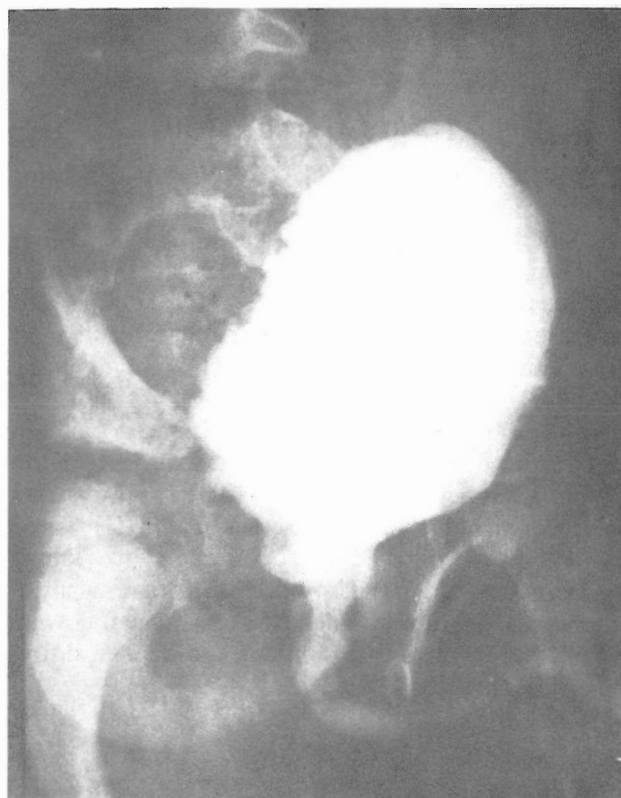**TABLE II. RESULTS OF GIL-VERNET ANTIREFLUX PROCEDURE IN 12 REFLUXING URETERS. (PERSISTENT FOLLOWING VALVE ABLATION).**

Grade of refluxes	IV or >
Average follow up between ablation and antireflux procedure	17 months
Average follow up following Gil-Vernet procedure	6 months
Success Rate	91.7%

children<sup>1</sup>. Some recommended diversion before reimplantation and if reflux did not cease after undiversion, then proceeded with reimplantation.<sup>3</sup> We did not divert any of our eight cases with severe VU reflux (Grade IV



**Fig 2B.** Huge bilateral reflux in Fig 2A stopped with simple Gil-Vernet antireflux technique (2 years follow up film). Creatinine is normal and the child is growing excellently.



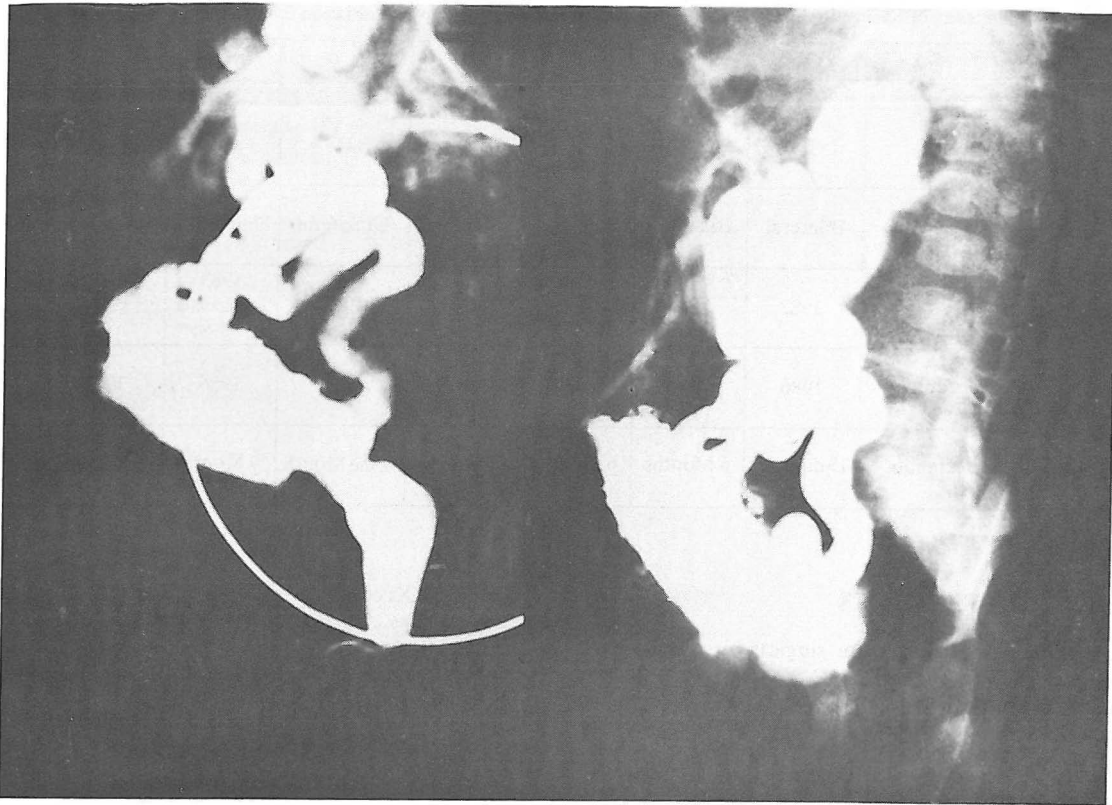

Fig 3A. Grade V vesicoureteral reflux in a 9 months old boy with posterior urethral valve.

or higher) while enjoying nonobstructive successful results following simple Gil-Vernet antireflux procedure. In one case, (Fig. 2A) the patient's creatinine was 5.5 mg/ml before ablation and continued to have massive reflux (grade V) bilaterally 3 years after valve ablation (Fig 2A). Following the antireflux procedure, he has nonrefluxing units and continued having creatinine well below 1 mg/100mL (0.4mg/100ml in the last follow up). Our other cases all had grade IV reflux which also successfully stopped refluxing following our approach, using the Gil-Vernet technique, without need for diversion and undiversion or facing the complications of other anti-reflux techniques.

This is the first report using the Gil-Vernet technique in children with PUV and persistent reflux following valve ablation, with excellent results (with no complications but one recurrence and 91.7% success rate). This is a very simple technique, with much less operative time (about one hour skin to skin), less invasiveness (VU anatomy is not disturbed), short hospitalization (about 4-7 days) and with almost no complication, while being very effective.<sup>1,2</sup>

We recommend Gil-Vernet Antireflux technique as the procedure of choice in management of VU refluxes persisting after valve ablation in children with posterior urethral valve.

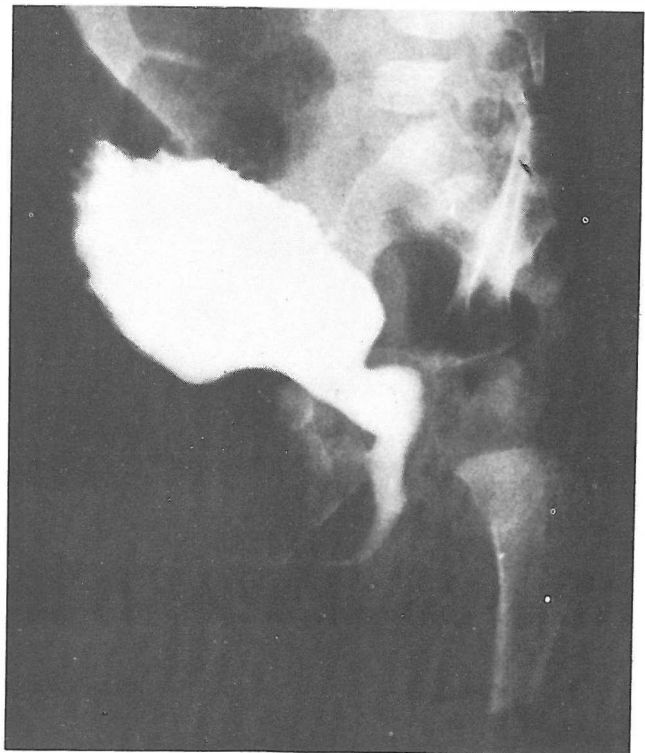


Fig 3B. Postoperative VCUG (3 months post Gil-Vernet procedure) demonstrates successfully stopped reflux bilaterally and excellent urinary stream. Patient's continuous fever after valve resection stopped only when the antireflux technique successfully stopped bilateral reflux.

Table III. The Grade of Reflux in 8 patients with persistent reflux following valve ablation in posterior urethral valve.

Patient	M.KH 1	A.M. 2	R.F. 3	E.D. 4	K.F. 5	M.J. 6	A.J. 7	A.D. 8
Grade of Reflux	IV	V	V	V	IV	IV	IV	IV
Bilateral or Unilateral	Bilateral	Bilateral	Bilateral	Unilateral	Unilateral	Unilateral	Unilateral	Bilateral
Valve ablation	1982	1984	1983	1987	1985	1985 paraureteral diverticulum	1986	1987
Gil-Vernet Antireflux Procedure	1986	1987	1986	1987	1986	1986	1987	1988
Follow up after Gil-Vernet technique	13 months	6 Months	6 Months	11 Months	One Month	9 Months	3 Months	8 Months

**REFERENCES**

1. Gil -Vernet JM: A new technique for surgical correction of vesicoureteral reflux. J Urol 131: 66,1984.
2. Simforoosh N: Gil-Vernet anti-reflux procedure in 34 children with primary vesicoureteral reflux: a longer follow up. Presented at XXI congress of the International Society of Urology, Buenos Aires, Argentina, 1988.
3. Duckett JW, Snow BW: Disorders of the urethra and penis, In: Walsh, et.al.(eds.). Campbell's Urology, 5th ed, Philadelphia: W.B. Saunders, 2000-30, 1988.