

Evaluation of surgical treatment results in parosteal osteosarcoma

Sam Haji-Aliloo Sami,¹ MD, Mikail Alt Jafarbay,² MD, Mehdi Ramezan Shirazi,³ MD.

Department of Orthopedic Surgery, Shafa Yahyaian Hospital, Baharestan Sq., Tehran, Iran.

Abstract

Background: Parosteal osteosarcoma is rare low-grade malignancy which arises on the surface of the metaphysis of long bones; it has a low propensity to metastasize. Different surgical treatment options including marginal resection, wide resection and amputation were recommended for the tumor. The purpose of the study was to assess the results of different surgical treatment of the lesion.

Methods: Thirty five consecutive patients with parosteal osteosarcoma were managed with four surgical techniques (Marginal resection, wide resection and prosthesis, wide resection and allograft application, and amputation) between 1378 - 1387, and the results were retrospectively reviewed. The mean age of the patients when the surgery was performed was 30.37 (range, eleven to seventy one years), and the mean duration of postoperative follow - up was 51 months (range, eight months to ten years)

Results: The mean time between the onset of symptoms and initial physician encounter was 15.98 months (range, 1.5 months to 60 months). None of the patients had metastasis preoperatively while three pulmonary metastases were detected postoperatively. Six patients had regional tumor recurrence postoperatively. The mean time of the recurrence postoperatively was 18.8 months (range, nine months to forty eight months). Three of thirty five patients assessed in the study died of pulmonary metastasis. All had dedifferentiated grading with different staging (Two patients had a stage of IIB and one with IIA). Medullary invasion was seen in one of them. One of the three patients was treated with Indomethacin for two years due to the misdiagnosis of myositis ossificans.

Conclusion: Wide resection of parosteal osteosarcoma produces a satisfactory long - term out come. However, individually - based treatment should be selected for each patient with parosteal osteosarcoma.

Keyword: parosteal osteosarcoma, treatment,outcome

Introduction

Parosteal osteosarcoma is a rare low grade tumor that arises from the surface of metaphysis of long bones [1]. The lesion has a peculiar tendency to occur as an ossified mass on the posterior aspect of the distal femur and proxi-

mal tibia [4]. Other locations such as the radius or the ulna are very rare [6,7]. It was described for the 1st time by Geschickter and Copeland in 1951 [2,3]. Patients with parosteal osteosarcoma usually have a long history of painless swelling [5].

The highest rate of prevalence is reported in

1. Associate Professor; Iran University of Medical Sciences, Tehran, Iran.

2. Orthopedic surgeon

3. **Corresponding Author**, Resident of Orthopedic Surgery, Shafa Yahyaian Hospital, Baharestan Sq., Tehran, Iran. Tel: +98 912 1875903. E-mail: Mehdi.shirazi@yahoo.co.uk

the 3rd and 4th decade of life with a slight female predominance [6,7]. The radiologic features include a densely ossified mass which its density of the periphery is less than that of the center [8]. Histologically, similar to low - grade intramedullary osteosarcoma, parosteal osteosarcoma consists of slightly atypical spindle cells producing slightly irregular osseous trabeculae.

The most important prognostic factor at the time of diagnosis of osteosarcomas including parosteal subtype is the extent of disease [1]. Whether medullary invasion with regard to the prognosis is of significance is discussed controversially in the literature. Unni et al.; Farmlett and Fishman [6] concluded that invasion makes the prognosis poor while Ahuja et al. [2] postulated that medullary involvement has no influence on the prognosis of patients with lower grade but worsens prognosis in those with higher grade.

Several types of treatment options including marginal resection, wide resection and amputation were recommended in the literature which each of them has advantages and potential pitfalls. The purpose of the study was to evaluate the treatment outcome of patients with parosteal osteosarcoma referring to three selected hospitals between 2000 - 2009.

Methods

We reviewed the results in thirty five consecutive patients with parosteal osteosarcoma (Table 1) who had been managed with one of four techniques (thirty two patients were treated with wide resection and allograft application

with internal fixation (plating); three cases had wide resection and prosthesis application; marginal resection and amputation were done in three and four patients respectively).

The mean age of the patients when the surgery was performed was 30.37 years (range, eleven to seventy one years). Fifteen patients were female and twenty were male. All patients had an established parosteal osteosarcoma confirmed by demographic findings, radiological characteristics and histopathological reports. The most common site for the tumor was distal portion of the femur detected in twenty one patients while ulna, distal tibia and Ilium involvement were the least sites found in three patients (table 1). The left sided involvement was seen in eleven patients and the right in ten.

Parosteal osteosarcomas were classified with use of Enneking system which includes three distinct staging of the lesion. In order to determine the stage of the tumor, through tumor work-up including relevant x-rays, chest CT, whole body scan, MRI of the involved part and also assessment of histopathology sample of the lesion was performed. Twenty seven patients had low grade, intracompartmental lesion without any metastasis (Stage IA). Five parosteal osteosarcomas developed as a low grade extracompartmental one with no metastasis (Stage IB). High grade tumors developed in three patients including intracompartmentally and two cases extracompartmentally (Stage IIA, IIB respectively). No regional and distant metastases were found in patients of our study at the time of diagnosis (Stage III).

Anteroposterior and lateral plain x-rays were

The anatomical Location of the tumor	The number of cases
Distal femur	21
Proximal tibia	7
Ulna	1
Distal tibia	1
Ilium	1
Proximal humerus	2
Ischium	2

Table 1. Illustration of the anatomical location of the tumor.

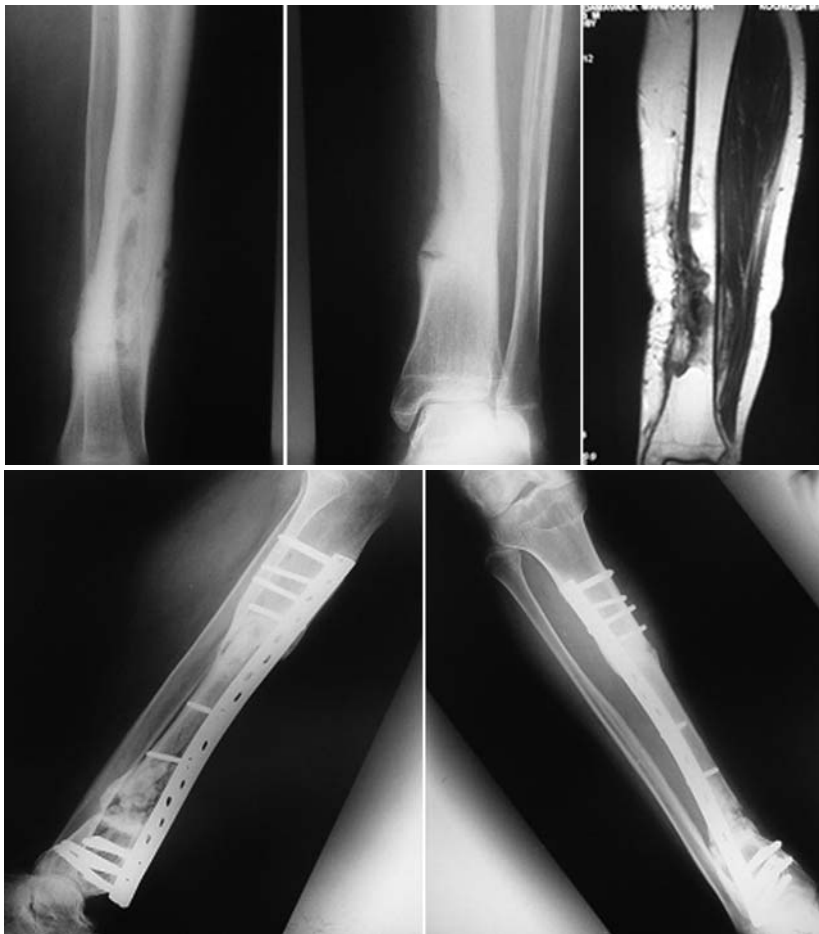

Fig. 1- A 22 year old male patient with a low grade (Stage IA) parosteal osteosarcoma treated with wide resection, allograft application and internal fixation. **c and d**, post operative X - rays. **a, b and c**: Preoperative x-rays and coronal MRI view of the lesion showing the tumor in the right distal tibia. **d and e**: Post operative X - rays showing wide resection, allograft application and internal fixation of the tumor.

made regularly postoperatively. All patients were examined by the senior author at the time of the most recent follow - up. Particular attention was paid to the range of motion of the involved joint and clinical symptoms related to regional recurrence of the tumor.

The mean duration of follow - up after performing surgery was 51 months (range, eight months to 10 years). Three patients died of pulmonary metastasis at the time of the latest follow - up.

Complications	Number of cases
Nonunion	2
Infection	1
Screw and plate breakage	2
Allograft breakage	2

Table 2. Number of patients with different complications.

Results

Twenty three patients referred to our three selected hospitals with the clinical complaint of swelling while pain and range of motion limitation were chief complaints in nine and three cases respectively. The mean time between the onset of symptoms and initial physician encounter was 15.98 months (range, 1.5 months to 60 months). In contrast to the previous series, twenty of thirty five patients in the study were male but similar to others [6,7], twenty six of them were in 3rd and 4th decades.

None of the patients had metastasis preoperatively while three pulmonary metastases were detected postoperatively. On the basis of radio-

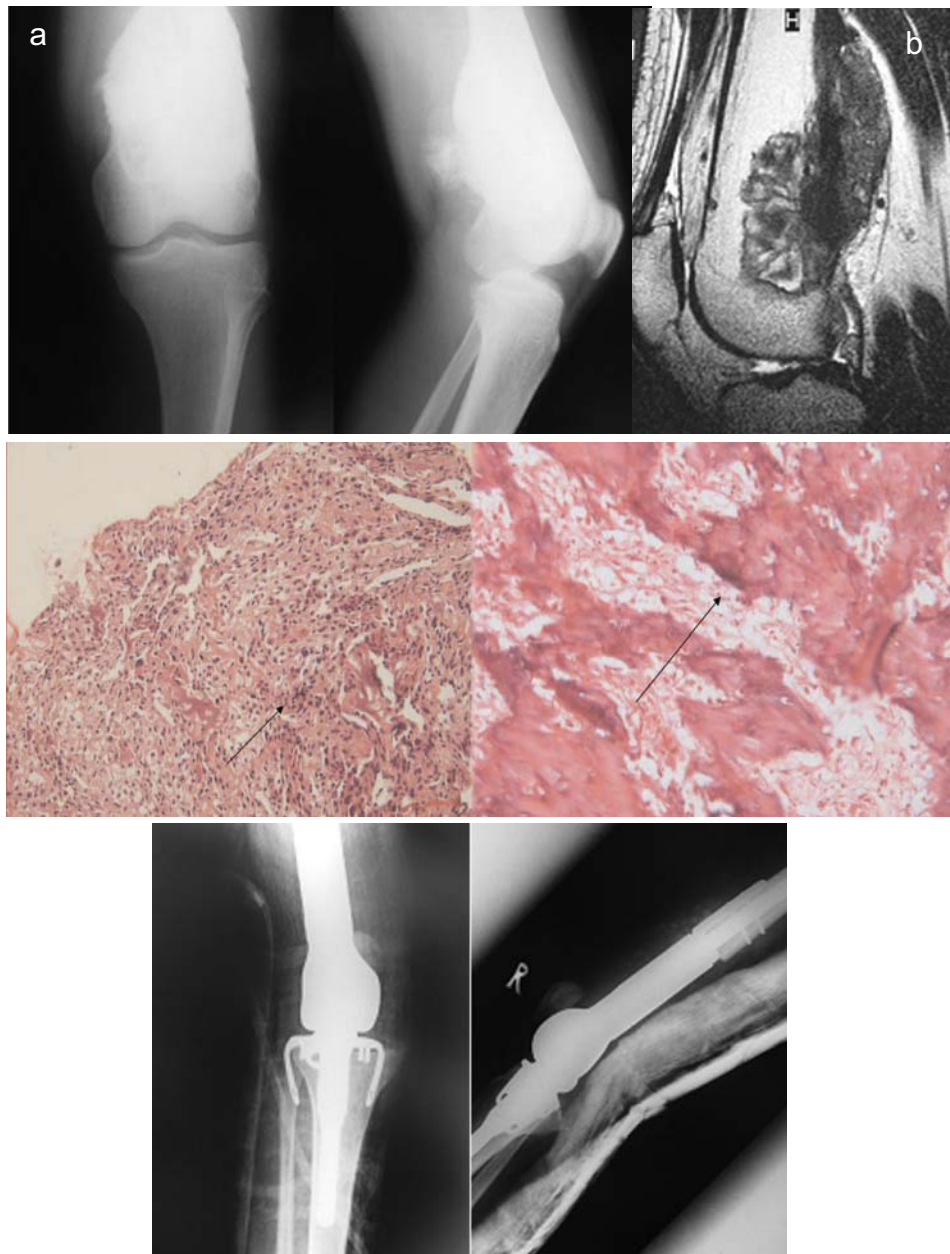


Fig. 2. A patient with a dedifferentiated parosteal osteosarcoma of the right distal femur treated with wide resection and prosthesis application. He died three years postoperatively due to regional recurrence. **a**: Preoperative anteroposterior (on the left) and lateral (on the right) radiographs of the lesion on the posterior aspect of the right knee. **b**: Preoperative sagittal MRI of the tumor showing the lesion on the posterior aspect of the knee with medullary involvement. **c** & **d**: Sections of the tumor showing a neoplastic lesion composed of sheets of mesenchymal tumoral cells with hyperchromic nuclei which produced matrix in the form of bone trabecula, osteoid and hyaline cartilage. Fibro-osseous areas composed of fibroblastic spindle cells with mild atypia. The arrow on the left shows osteoid production while the one on the right reveals mesenchymal tumor cells. **e** & **f**: Postoperative anteroposterior (on the left) and lateral (on the right) radiographs showing wide resection and prosthesis application of the tumor.

logical findings, one patient had medullary invasion.

Seven patients were treated with two surgeries: Two because of nonunion; one because of

plate breakage; three due to inadequate marginal resection and one because of regional recurrence fourteen months postoperatively. The latter had above knee amputation (Table 2).

Six patients had regional tumor recurrence postoperatively. The mean time of the recurrence was 18.8 months (range, nine months to forty eight months). The 1st was a seventy one year old female patient with a stage of IIB and dedifferentiated grade of parosteal osteosarcoma. Fourteen months postoperatively, tumor recurrence occurred treated with an above knee amputation. The patient died of pulmonary metastasis five months post amputation. Three patients with a low grade (Stage IA) parosteal osteosarcoma were treated with marginal resection in other centers. Due to regional recurrence, wide resection with allograft application and internal fixation was done in our center. The 5th case of local recurrence was a forty year old male patient with a low grade (Stage IB) tumor treated with marginal resection. The patient did not accept any other surgery at all. Interestingly, he was alive fifty one months after the time of diagnosis of the recurrence. The 6th case was a 24 year old male patient with a dedifferentiated grade (Stage IIB) parosteal osteosarcoma who had wide resection. He died of regional recurrence three years postoperatively.

Three of thirty five patients assessed in the study died of pulmonary metastasis. All had dedifferentiated grading (Table 3) with different staging (Two patients had a stage of IIB and one with IIA). Medullary invasion was seen in one of them. One of the three patients was treated with Indomethacin for two years due to the misdiagnosis of myositis ossificans.

At the latest follow - up examination, six patients had no full range of motion that were treated with wide resection technique.

Postoperatively, infection was found in one patient whereas screw, plate and allograft breakage was detected in 4 patients (Table 2).

Discussion

Currently, three surgical methods (wide resection, marginal resection and amputation) are being used. The current technique of wide resection and allograft or prosthesis application

Grading	No. of patients died
Low grade	0
Dedifferentiated	3

Table 3. Number of patient died with regard to their grading.

has been well understood and several authors have reported success in clinical outcome [10,11]. In our study, wide resection and allograft application with internal fixation (plating) was the most common technique applied. It has a high rate of reliability of tumor recurrence and metastasis prevention. However, there are many potential pitfalls. As being large at the time of diagnosis and proximity of the tumor to the relevant neurovascular components at distal femur, making a wide free margin is difficult. Therefore, in practice, this type of surgery has a high rate of morbidity. In our series, all six patients with no full range of motion were treated with the technique.

Concerning those treated by wide resection with prosthesis application, one of three patients had dedifferentiated distal femur parosteal osteosarcoma (Stage IIA). This patient had local recurrence and pulmonary metastasis six months later and died. The second patient did not have full range of motion at the latest follow up (ROM = 10 - 100). The third case had no complication in the last visit. As the number of patients treated with this technique was low, statistically it is not possible to assess the efficacy of the treatment and compare to other methods of wide resection. The worse course of the first patient's disease is due to the grade of the tumor rather than the method of treatment.

Numerous authors have reported on the use of marginal resection in the treatment of parosteal osteosarcoma. Eight of twenty one patients treated with marginal resection were reported on by Hans et al. [11]. They applied the treatment option if there was the possibility of joint surface preservation. Two of these eight

patients had the tumor recurrence.

In an attempt to decrease the rate of recurrence, attention should be paid to the following factors:

1. Marginal resection - As a treatment option in our study, all four patients experienced the recurrence.

2. Grading of the tumor - Grading is the most significant prognostic factor in parosteal osteosarcoma [10,12,13]. In our series, two of four patients with regional recurrence had dedifferentiated parosteal osteosarcoma.

3. Medullary involvement - In some series [4,6,9], it was found that medullary invasion has a negative influence on prognosis. However, no correlation between medullary involvement and local recurrence or metastasis has been reported on by Okada et al [5] and Vander Walt et al. [14]. In our study, one patient had medullary invasion that died of pulmonary metastasis.

Differential diagnoses of the subtype of osteosarcoma are myositis ossificans and osteochondroma [1]. These diagnoses should be considered in radiological and histopathological assessment as one of thirty five patients in the study was treated with Indomethacin for two years with the diagnosis of myositis ossificans and unfortunately died of pulmonary metastasis.

Bertoni et al. reported patients with dedifferentiated parosteal osteosarcoma should be treated with wide resection with or without chemotherapy. In these high grade sarcomas, adjuvant chemotherapy often has a role in the prevention of distant metastasis [15]. Five of thirty five patients had chemotherapy in our series. Two of them who had dedifferentiated tumor died. Perhaps, chemotherapy should be added to the standard surgical treatment in order to improve prognosis in those with dedifferentiated parosteal osteosarcoma.

Conclusion

As wide resection of parosteal osteosarcoma

is accompanied with a low rate of regional recurrence and metastasis, it produces a satisfactory long - term out come. However, individually - based treatment option should be selected for each patient with parosteal Osteosarcoma.

References

1. Canale T, Beaty JH. Campbell's operative orthopaedics. 11th edition. 2008; p. 904.
2. Ahuja SC, Villacin AB, Smith J, Bullough PG, Huvoos AG, Marcove RC. Juxtacortical (parosteal) Osteogenic sarcoma: Histological grading and prognosis. *J bone Joint Surg Am* 1977 59: 632 - 47.
3. Picci P, Campanacci M, Baci G, Capanna R, Ayula A. Medullary involvement in parosteal osteosarcoma. A case report. *J Bone Joint Surg Am* 1987; 69: 131 - 6.
4. Schajowicz F, McGuire MH, Araujo ES, Muscolo DL, Gitelis S. Osteosarcomas arising on the surface of long bones. *J Bone Joint Surg Am* 1988; 70: 555 - 64.
5. Okada K, Frassica FJ, Sim FH et al. Parosteal Osteosarcoma: A clinicopathological study. *J bone Joint Surg* 1994; 76: 366 - 378.
6. Farmlett E, Fishmann EK, Case report 300. *Skelet Radiol* 1985; 13: 89 - 93.
7. Luck JR, Luck JV, Schwimm CP. Parosteal osteosarcoma: A treatment - oriented study. *Clin Orthop Relat Res* 1980; 153: 92 - 105.
8. Edeiken-Monroe B, Edeiken J, Jacobson HG. Osteosarcoma: *Semin Roentgenol* 1989; 24: 153 - 173.
9. Unni KK, Dahlin DD, Beabout JW, Ivin JC. Parosteal osteogenic sarcoma: *Cancer* 1976; 37: 2466 - 2475.
10. Ritschl P, Wurnig C, Lechner G, Roessner A. Parosteal osteosarcoma: 2 - 23 year follow - up of 33 patients. *Acta Orthop Scand* 1991; 62: 195 - 200.
11. Han I, O JH, Na YG, Moon KG, Kim HS. Clinical outcome of parosteal osteosarcoma. *J Surg Oncol* 2008; 97: 146 - 49.
12. Campanacci M, Picci P, Gherlinzoni F, Guerra A, Bertoni F, Neff R. Parosteal osteosarcoma. *J Bone Joint Surg Br* 1984; 66: 313 - 21.
13. Wold LE, Unni KK, Beabout JW, Sim FH, Dahlin DC. Dedifferentiated parosteal osteosarcoma. *J Bone Joint Surg Am* 1984; 66: 53 - 9.
14. Van derwalt JD, Ryan JF. Parosteal osteogenic sarcoma of the hand. *Histopathology* 1990; 16: 75 - 78.
15. Bertoni F, Bacchini P, Staals EL, Davidovitz P. Dedifferentiated parosteal osteosarcoma: The experience of the Rizzoli Institute. *Cancer* 2005; 103: 2373 - 82.