

USHER'S SYNDROME REVISITED

MOHSEN DJALILIAN, M.D., M.S. GEORGE W.FACER, M.D.,
F.A.C.S.AND M.H.LASHKARI, M.D., F.A.C.S.

*From the Department of Ophthalmology and ENT of Iran Air and ENT Department of MayoClinic Rochester
Minnesota, U.S.A.*

ABSTRACT

Usher's syndrome is a genetically inherited autosomal recessive disorder resulting in the double handicap of deafness and progressive blindness, known as retinitis pigmentosa. The disease is also associated with psychoses, mental retardation, and other major neurophysiological changes. It appears to be more common among Jewish individuals and consanguinous marriages. While it is rare in the general population (3 cases per 100,000 population), it is significantly prevalent among those who are deaf. Most patients are forced to give up their profession around age 30 or 40 or earlier, either because of advancing failure of sight leading to blindness at age 50 or 60, or due to the other disabilities of the condition.

Although a wide variety of treatments have been tried including surgery, endocrine therapy, vitamins, and transplants, at present the disease cannot be cured nor its course significantly altered. A program for prevention through high risk diagnostic screening, coupled with genetic counseling, is both feasible and practical.

In this report, we present two siblings with this syndrome, as well as a general review of the history and literature concerning this disorder.

MJIRI, Vol.2, No.2, 143-147, 1988

INTRODUCTION

Albrecht Von Graefe¹ in Berlin in 1854 was the first to report the association of retinitis pigmentosa and congenital hearing loss. Usher² in 1914, reporting a large series, added cataracts, speech disorders, and mental illness to the syndrome. Hallgren³ in 1954 presented 151 cases and added the finding of vestibular ataxia. Usher's syndrome thus consists of retinitis pigmentosa and congenital and/or progressive sensorineural hearing loss, cataracts, speech disorders, and mental deficiency. Psychosis and vestibular ataxia are additional variable findings in Usher's syndrome. The incidence of retinitis pigmentosa in congenitally deaf individuals has been variously reported to range from 3% to 10.4%, while hearing loss has been found in 3.4% to 6.3% of patients with pigment degeneration of the retina.

Liebreich⁶ in 1861 was one of the first to construct a series of pedigrees in which there appeared cases of deafness with retinitis pigmentosa in a survey in which

he had examined 241 of the 341 deaf mutes in Berlin and found 14 with retinal pigmentation. Stephenson and Chessman⁹ in Northern Ireland and the New York population study reported by Sank²⁷ do not mention frequency of anomalies other than hearing impairment.

Etiology

While familial incidence of retinitis pigmentosa and deafness was noted by Von Graefe and Liebreich, Usher was the first to emphasize the familial nature of the syndrome and suggested that it constituted a specific genetic entity. Von Wibaut²⁸ pointed out the striking preponderance of cases showing a recessive mode of inheritance as opposed to dominant inheritance, a hereditary pattern that is commonly seen in cases of isolated retinitis pigmentosa. Bell²⁹ further emphasized the genetic aspects of the syndrome, and Lindenov⁸ presented evidence strongly supporting the contention that the two cardinal features of the syn-

drome were a pleotropic manifestation of a single recessive gene rather than effects of two separate genes. The hereditary pattern of Usher's syndrome is usually autosomal recessive with 100% penetrance; the defect is at a single chromosomal locus.

Usher's syndrome is believed to be transmitted by an autosomal recessive gene. Consequently, although it has been estimated that one out of 100 individuals is a carrier, the trait manifests in only three per 100,000. Other pertinent facts about the prevalence of Usher's syndrome are that it appears to be more common among Jewish individuals^{4,17,18} and consanguinous marriages.^{18,20}

It is also known that deafness is not the most frequent degenerative process associated with retinitis pigmentosa.²¹ Some believe the genetic code for Usher's syndrome begins to manifest itself during embryological development.^{3,10-12} The various lesions, although having different sites, are thought to have a common point of attack in the embryo.¹³

Fraser, et al.,²⁵ describe Usher's syndrome as a genetic error of metabolism and list two other syndromes (Pendred's and Jervell Lang-Nielsen). It was theorized that the common feature of congenital deafness may be due to a hypersensitivity of the VIII nerve to metabolic and chemical toxins. Francois raised the issue of whether the action of the pathology of the gene is endocrinological, neural, or toxic; or whether it is simply based on diminution in the viability of retinal cells.¹⁵ There has been some debate over whether Usher's syndrome is a bonafide genetic syndrome or three separate conditions.

Clinical features

The hearing loss is cochlear in type and is bilateral, often with mild to moderate preservation of low frequencies (from 125 to 500 Hz). Although the hearing loss is frequently congenital, it may not be recognized until the patient is one to two years old. It is generally severe and may be progressive. Vernon²⁶ showed that from 5 to 10% of patients with congenital deafness have Usher's syndrome.

The second cardinal feature of Usher's syndrome, retinitis pigmentosa, frequently does not become apparent until late childhood or adolescence. The ocular symptom is usually night blindness. The visual fields are gradually restricted and visual acuity deteriorates. Cataracts are almost always located in the posterior cortical layers of the lens and are frequently observed as the disease progresses. Vision is further compromised in the fourth to sixth decades of life. Only minimal vision may remain, with progression of the visual loss to blindness. The earliest ophthalmologic sign is an abnormal finding on a dark adapted electroretinogram, which may permit the diagnosis of

retinitis pigmentosa. In the presymptomatic state, the characteristic findings of the retina are a waxy, yellowish optic disk, narrow arteries, and bare corpuscular pigmentation in the periphery.

Not only does Usher's syndrome involve a loss of vision and hearing, but Bossu and Luypaert¹⁴ found that most patients also lacked olfactory sensitivity. Thus, three of five special sensory modalities are involved. A loss of taste and smell has also been noted by the author among some genetically deaf children (a high risk group for Usher's syndrome). The questions which arise from this and from Bossu's finding concern not only the extent to which all sensory modalities may be involved, but also the possibility of a central lesion or at least a common degenerative process

Neuropathology and psychiatric findings

Usher's syndrome has special theoretical interest for the organically-oriented psychiatrist. The neurological degeneration associated with it involves the retina, a part of the brain proper.^{14,22}

It is marked by accumulation of certain lipids in the nerve cells.¹² Possibly, the lesions causing hearing loss are central rather than peripheral.^{14,22} Consequently, an understanding of the degenerative process of Usher's syndrome may have generality to other neurological and psychiatric diseases.

In the temporal bone, irregular degeneration of the stria vascularis, atrophy of the organ of Corti and the spiral ganglion, and both peripheral and central nerve degeneration with atrophy of the end branches of the labyrinthine vessels are evident on pathologic examination.

Another neurological structure affected by the disease is the vestibular apparatus. The reported prevalence of vestibular-based disturbances of equilibrium varies from 0-100%,^{3,16,21,23} with the most comprehensive study yielding a rate of 90%. Whether the site of lesion causing the balance disturbance is in the labyrinth or cerebellum is unclear, but the general consensus favors the labyrinth.³

Psychiatric disorders are common in Usher's syndrome. Hallgren³ found that of the 114 cases in whom he obtained or made a diagnosis, 23.2% (26 cases) were psychotic: 16 presented a schizophrenic-like picture, 3 showed depressive reactions, 2 had psychotic episodes and recovered, and 5 were hospitalized due to aggressiveness and agitation. Many reported auditory hallucinations. Paranoid tendencies and violence were common among these patients, and 13 of 26 psychotics were also mentally retarded. The overall prevalence of mental retardation in the total sample of 114 patients was 23.8%. The only remaining data on Usher's syndrome and psychiatric illness comes from a survey of the total population in New York State Mental Hospital

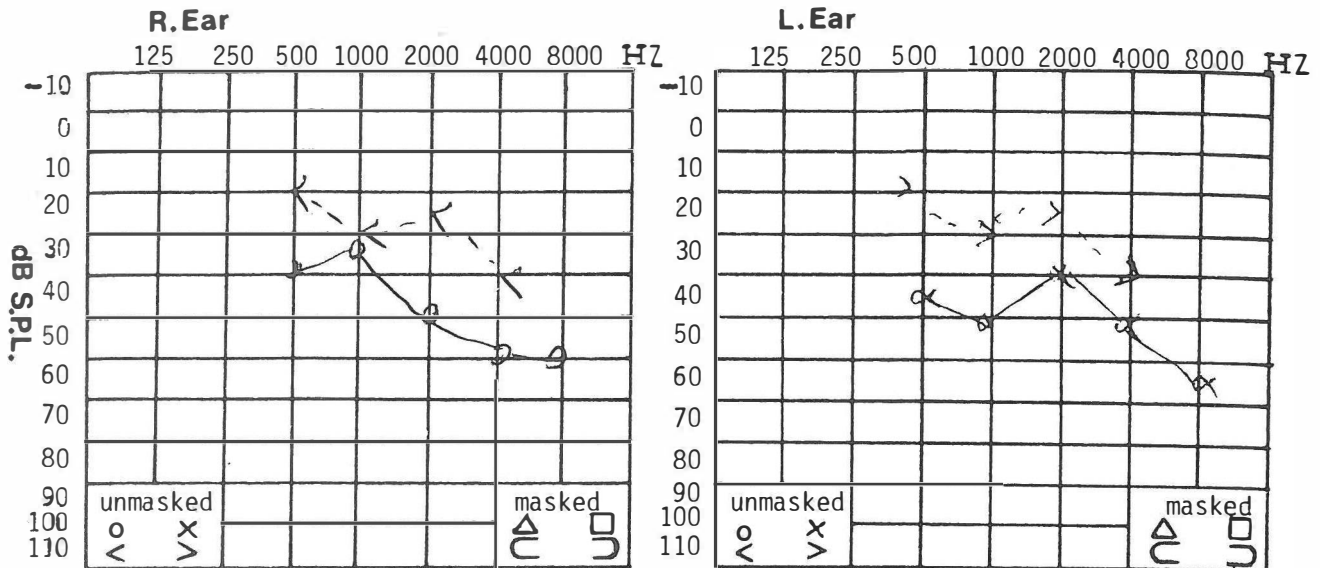


Figure 1: Pure tone audiograms of patient 1

al. It was reported that 4.6% of all of the deaf patients hospitalized for mental illness had Usher's syndrome. Rainer³⁰ and Streifler, et al²⁴ obtained EEGs from 25 cases of retinitis pigmentosa with night blindness, and five relatives. Of these 30 cases, 14 had abnormal EEGs, consisting mostly of bilaterally symmetrical and synchronous slow waves.

Prevention and management

Despite circumstances which permit a significant reduction in the prevalence of this chronic, incapacitating disease, no preventive program has been developed. Five major steps in prevention are recommended by Vernon:²⁹

1. Education of professional persons who evaluate deaf and blind children about Usher's syndrome.
2. Diagnostic screening of all congenitally deaf children with an ophthalmic battery including ERG-EOG ophthalmoscopy examination, visual field tests, and dark adaptation measurements.
3. Evaluation of an audiological test battery plus vestibular function testing.
4. Similar ophthalmic and audiological screening for relatives of deaf children identified as having Usher's syndrome.
5. Genetic counseling of identified individuals and their families.

CASE REPORTS

Case 1

A twenty-four year old white woman was referred to the ENT clinic because of bilateral hearing loss which

had been noted at the age of three. The hearing loss had been progressive and she also complained of intermittent dizzy episodes with nausea. A review of symptoms at the time was negative.

The family history was positive; one sibling, an older brother, had a hearing loss. She had a past history of infectious hepatitis. An audiogram revealed a bilateral sensorineural hearing loss (Fig. 1). Otorhinolaryngologic examination was normal. The modified Kobrak ice caloric test was unremarkable. Blood tests including biochemistry, immunoelectrophoresis and urine analysis were all within normal limits. Plain roentgenograms of the petrous bones including Stenver's and transorbital views were normal. Eye examination including angiography and visual fields were reported as follows: arterial phase: generalized disturbance of the retinal pigment epithelium; the optic disc is well circumscribed, some areas of choroid retinal atrophy can be observed and remains non-fluorescent in other places; punctate remnants of the retinal pigment epithelium contrast with the intense background fluorescence.

Altogether gross attenuation of the vessels can be seen, which is nonfluorescent. In the peripheral retina, some bone-corpuscle pigmentary aggregates can be seen.

The above observation shows retinitis pigmentosa of both eyes. If the two films of the angiography are compared, it shows roughly the same situation.

Case 2

A twenty-four year old brother of Case 1 was referred to the ENT clinic because of bilateral, progres-

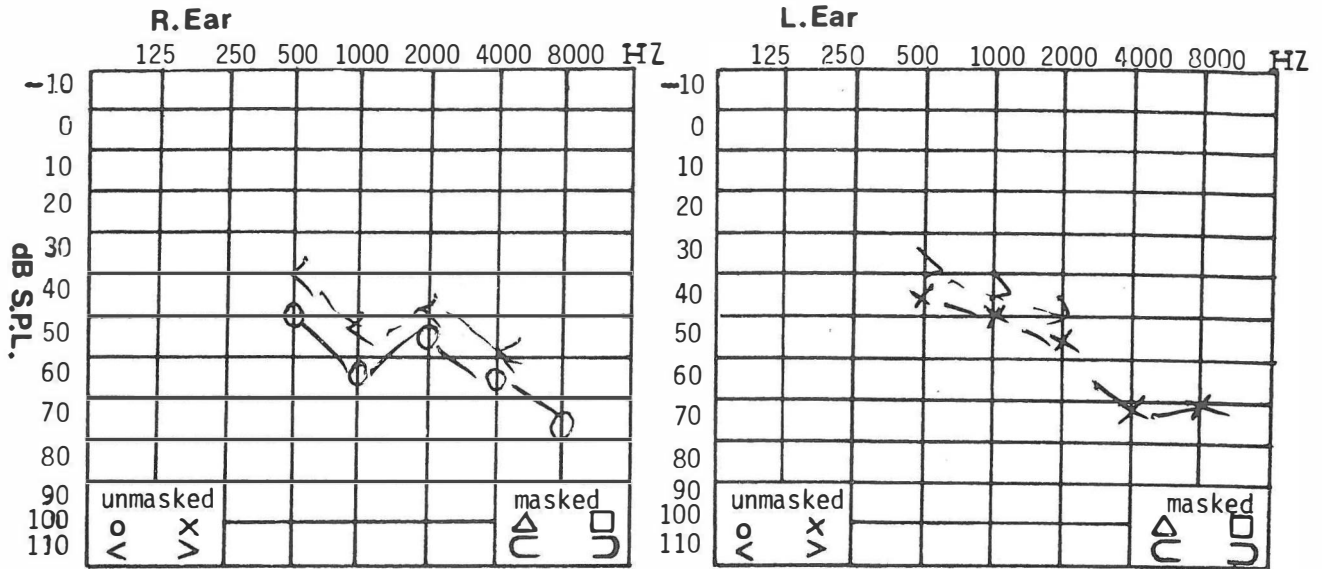


Figure 2: Pure tone audiogram of patient 2

sive hearing loss accompanied with intermittent dizziness and nausea. The hearing loss was first noted at age 13. The family history was positive. His parents' marriage was not consanguinous. Two siblings out of six had a hearing loss. His mother had a history of renal disease. His father had developed squamous cell carcinoma of the larynx which was treated with cobalt 60 irradiation. Audiometry revealed a severe bilateral hearing loss (Fig. 2). The results of the remainder of the ENT examination were unremarkable. Plain X-ray, Stenver's, transorbital and Towne's views were all normal. The patient noted night blindness and eye exam included angiography and visual fields which were reported as follows: arterial phase: generalized disturbance of the retinal pigment epithelium; the optic disc is well circumscribed; some areas of choroid retinal atrophy can be observed, and remains non-fluorescent in other places; punctate remnants of the retinal pigment epithelium contrast with the intense background fluorescence.

Altogether gross attenuation of the vessels can be seen, which is nonfluorescent. In the peripheral retina, some bone-corporcle pigmentary aggregates can be seen.

The above observation shows retinitis pigmentosa of both eyes. If the two films of the angiography are compared, it shows roughly the same situation.

Blood tests including immunoelectrophoresis and biochemistry and urine analysis were all within normal limits. Modified Kobrak ice caloric testing was unremarkable.

With the above findings, the diagnosis of Usher's syndrome was made. The following conclusions may be drawn:

1. An autosomal recessive gene with 100% penetrance located at a single chromosomal locus was found to be responsible for the more profound hearing impairment associated with Usher's syndrome.
2. Without exception, all offsprings had Usher's syndrome when both parents had the syndrome, but no case of deafness occurred among 52 offsprings when only one parent had Usher's syndrome, and the other parent was deaf from some other autosomal recessive gene.
3. With a few exceptions, known heterozygous carriers had a slight loss of hearing at all frequencies. Signs of retinitis pigmentosa and cataract were found in 13% of all known heterozygous carriers.
4. The degree of hearing impairment was greater in individuals with Usher's syndrome than in those who did not have the associated visual impairment.
5. Ophthalmological examinations are indicated for all children with severe congenital hearing impairment to aid genetic counseling.

REFERENCES

1. Von Graefe A: Exctionillis verhalten des geisicht feldes bei pigmentartung des netzhaut. Arch Ophthal (Part 2), 4:260, 1958.
2. Usher C H: on the inheritance of retinitis pigmentation with notes of cases. Roy Ophth Hosp Resp, 14:13, 1914.
3. Hallgren B: Retinitis pigmentosa combines with congenital deafness: With vestibular cerebellar ataxis and mental abnormality in proportion of cases: A Clinical study. Acta Psychiat et Neurolo Scand (Suppl), 34:138, 1454.
4. Hallgren B: Retinitis pigmentosa and congenital deafness. Lancet, 1:688, 1960.
5. Uchermann V: Dedovstummei norge idristiania. Commermayor 1846 588-584.

6. Liebreich R: Abknft asehen unter blutsver wandrten als ground von retinitis pigmentosa. Deutsche klin, 13:53-55, 1861.
7. Ane Gireff K W: Uber den zustand der augen taubs tummer schulkinden: klin Mbi Augenh L17: Neu Falce 8:(65-73, 1404).
8. Lindenov H: The etiology of deaf mutism with special reference to hereditary association open hagam musks. Guakd. 1445.
9. Steveson A C and Chessman E A: Hereditary deaf mutism with particular reference to Northern Ireland. Ann Hum Genetic, 20 177-231-1456.
10. Ammann F, Klein D and Franceschettia: Genetic and epidemiological investigation of pigmentary degeneration of retina and allied disorders in Switzerland. 7. Neurol Sci 2 183, 14.
11. Bochenek Z and Mitkienie^z Szrenia WSKW: Investigation of organ of hearing in retinitis pigmentosa Otolaryngology. Pol. 12. 457, 1958.
12. Stenger H A: Retinitis pigmentosa symmetrical inner ear deafness, typical reversible vascular fistula reaction without fistula and irritability or vestibule contribution of hereditary ear and eye disease. In, T.R. Luinse, D.M. Kienle and W.C. Huffman (eds). The Year Book of Ear, Nose and Throat of Maxillofacial Surg. P. 54-54. Year Book Publication, Chicago - 1457-1458.
13. McGovern F H: Association of nerve of deafness and retinitis pigmentosa interval repor and otolaryngology 64, 1044-1460.
14. Bossu A and Luypaert R B: The syndrome of Usher. Annals Oculist 141-521-1458.
15. Fracios J: Differential diagnosis of tapeto retinal degenerations. Am Med Asso Archs Ophthalmology 54.888. 1458.
16. Taylor U D: Congenital deafness in H.P. Schenck () Otolaryngology, p. 1-14, Prior Hagerstown 1460.
17. Hammerschlag: Lur kennntnis der hereditary degeneration. Z Ohrenheilk 54/1407 Ref 181 W. Fraser, G.R. Profound Child Hoid.
18. Parnicky J J: Characteristics of deaf blind-adult at industrial home for bfind adult at industrial home for blind in: Surgery c selected characteristics of deaf-blind adults-in N.Y. State. Fa 1457. Vol VII, P.B-78 Industrial Home for the Blind, Brookly N.Y. 1454.
19. Fraser GR: Profound childhood deafness. T. Med. Genetic 1464
20. Kloepfer H W, Lagnaite J K, and McLanrin J W: the hereditar syndrome of deafness and retinitis pigmentosa. Laryngoscope 76.3. 1466.
21. Landau landiometric. j, and Fein Messer, M: Audiometric an vestibular examination in retinitis pigmentosa. British J Ophthalmology 40/40 1456.
22. Alberth B, Balint A, and Kosa A: Audiometric investigation i patients with pigment degeneration of the retina. Klin. Mot Augenheik 133, 4/1458.
23. Gremonsese G and Mowa E: The Usher Syndrome. Arc Otolaryn 70-422-1462.
24. Sterifler M and Landau Y: Electrical brain potential in retiniti pigmentosa and familial hemerglopia. Ophthasmo. Basel 13C 116-1455.
25. Fraser G R, Froggatt P and Murphy T: Genetical aspects o cardio-auditory syndrome. Of Yenvell and Lance-Nielson (Congomitul Deaf and Electro Cardiographic Abnormalities) Annals Hum. Genet. 28-133-1464.
26. McRay Vornon, Ph.D. Ushjenls Syndrilmey. Chron. Dis. 146 Vol. 22. P. 133-151 Pergamon Pnesf.
27. Snak D: Genetic aspects of early total deafness in family an mental health problems in a deaf population. J. D. Rane (ed N.Y., 1963.
28. Von Wibant F: Stuchien uber retinitis pigmentosa. Klin MB) Augenheilk 87-298-1931.
29. Bell, Julia: Retinitis pigmentosa and allied Congenital nigh blindness, retinae. TreasHum Inherit. 2(1) 1923.
30. Rainer J D, et al (eds): Family and Mental Health Problems i Deaf population. N.Y. State Psychiatric Institute, N.Y., 1963.

