

ANTERIOR MEGALOPHTHALMOS

S.H. SAJJADI, M.A. JAVADI, AND H. AHMADIEH

From the Ophthalmology Department, Shahid Labbafi Nejad Medical Center, Shahid Beheshti University of Medical Sciences, Tehran, Islamic Republic of Iran.

ABSTRACT

Anterior megalophthalmos is a developmental anomaly of the anterior ocular segment. This is an X-linked recessive disease and manifests as bilateral enlarged corneas, open iridocorneal angle, hypoplastic iris and dislocation and opacification of an apparently small lens.

We have also observed obvious vitreoretinal degeneration in our patients.

What may threaten visual acuity later is an open angle glaucoma and retinal detachment. It should be distinguished from simple megalocornea and congenital glaucomatous buphthalmos. Two cases of anterior megalophthalmos in one family are presented and discussed here.

MJIRI, Vol.2, No.1, 11-14, 1988

INTRODUCTION

In a child with congenital anomalies of the cornea, correct diagnosis is essential before any therapy is started. Diagnosis will be much easier when evaluation of these anomalies is based on anatomical landmarks.

The origin of all of these anomalies is the embryological maldevelopment of the mesenchymal tissue secondary to defective influence of the neural crest.

The normal horizontal diameter of the cornea of a newborn is about 10 mm which increases to 11.75 mm when the child is two years old. When the diameter of the newborn cornea is 12 mm or more or that of an adult is 13 mm or more, the term "megalocornea" is used. Megalocornea manifests itself in three different clinical forms:

1) Simple megalocornea: megalocornea which is not associated with any other ocular anomalies, and is usually inherited as an autosomal dominant disorder.

2) Anterior megalophthalmos: This is transmitted as an X-linked recessive disease, and consists of megalocornea, dysgenesis of the anterior chamber angle, enlarged ciliary ring, lens dislocation and early onset cataract.

3) Buphthalmos: megalocornea which is secondary to congenital glaucoma.

In keratoglobus, in spite of the seemingly corneal enlargement which is manifested by corneal thinning and its subsequent protrusion, the corneal diameter remains normal. Megaloglobus in which the whole

eyeball may congenitally become enlarged, in the absence of increased intraocular pressure seems to be a non-existent entity.

In anterior megalophthalmos, because of enlargement of the ciliary ring and resultant lens dislocation, anterior chamber becomes extremely deep. The angle is open but contains an abundant amount of mesenchymal tissue, the iris stroma may be hypoplastic and thus may transilluminate. Late increase in intraocular pressure may threaten vision.¹ Therefore, annual measurement of intraocular pressure is mandatory.

Marfan's syndrome has also been found in association with this disorder.¹

Table I adapted from Harley's Pediatric Ophthalmology² is a good guide for differentiation of these three anomalies.

CASE REPORTS

Case 1: Massoud A. (Figure 1) is a 10 year old boy whose parents noticed the enlargement of both of his corneas since birth. He received his first aphakic glasses when he was 3 years old.

On examination, both eyes were quiet. The uncorrected vision was counting fingers from 2 meters in both eyes which would increase to 20/40 OD and 20/30 OS with this correction: OD. +11.00 - 1.00 x 20°

OS. +11.00 - 1.00 x 20°

Table I. Differentiation of simple megalocornea, anterior megalophthalmos and buphthalmos.

	Simple Megalocornea	Anterior Megalophthalmos	Primary Infantile Glaucoma with Buphthalmos
Inheritance	Autosomal dominant (?)	X-linked recessive (male preponderance)	Sporadic
Time of appearance	Congenital	Congenital	First year of life
Bilaterality	Bilateral Symmetrical	Bilateral Symmetrical	Unilateral or bilateral Asymmetrical
Natural history	Nonprogressive	Nonprogressive	Progressive
Symptoms	None	None	Photophobia, epiphora
Corneal clarity	Clear	Clear or mosaic dystrophy	Diffuse edema, tears in Descemet's membrane
Intraocular pressure	Normal	Elevated in some adults	Elevated
Corneal diameter	13-18 mm.	13-18 mm.	13-18 mm.
Corneal thickness	Normal	Normal.	Thick
Keratometry	Normal	Normal. Astigmatism	Flat
Gonioscopy	Normal	Excessive mesenchymal tissue	Excessive mesenchymal tissue
Globe diameter (A-scan)	23-26 mm.	23-26 mm.	27-30 mm.
Major ocular complications	None	Lens dislocation, Cataract 40 years, secondary glaucoma	Optic disc damage, late corneal edema
Associated systemic diseases	None	Occasionally Marfan's and other skeletal abnormalities	None consistent

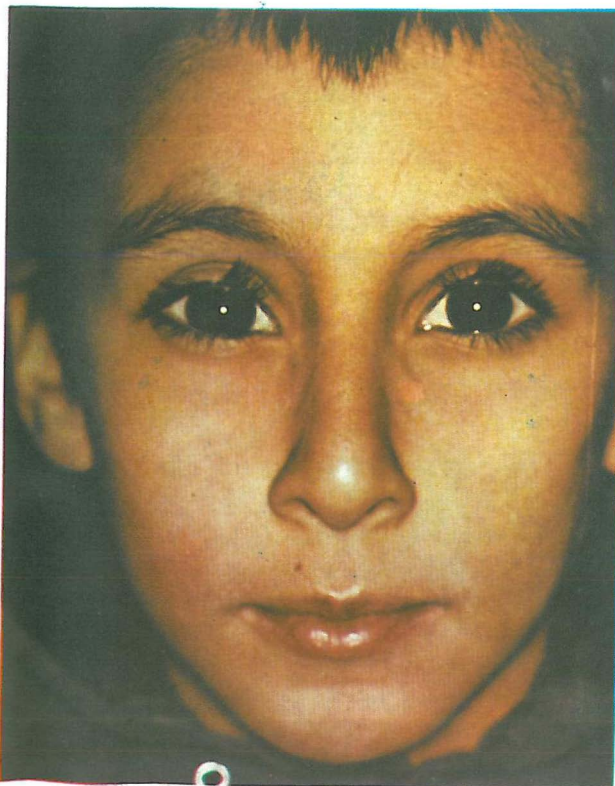


Fig 1: A 10 year old boy with enlargement of both corneas. The patient received aphakic glasses at 3 years old.

Both corneas were clear and had a horizontal diameter of 15 mm. In the right eye the anterior chamber was deep and the clear lens was found to be dislocated and floating in the vitreous cavity. The lens of the left eye was dislocated into the anterior chamber (Figure 2). Iridodonesis was observed and the iris was mildly atrophic in both eyes. The intraocular pressure in both eyes were within normal range. In gonioscopy, the angle was open and iris processes extended to the trabecular meshwork in both eyes. Details of the angle were not thoroughly visible.

In funduscopy, the disc was pink and cup to disc ratio was 3/10. Macula and retinal vasculature were normal.

Severe degenerative changes of vitreous with numerous strands and membranes were obvious in both eyes. White without pressure areas were visible in nasal and temporal peripheries.

The chief complaint of the patient was blurred vision that was attributed to repeated lens dislocation from vitreous cavity to anterior chamber. This took place two to three times a day. In order to take care of dislocation of the lens from vitreous into the anterior chamber, the patient was put in the supine position and

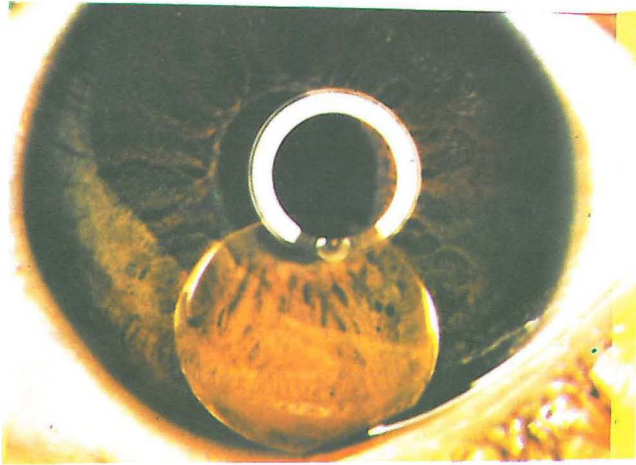


Fig 2: Dislocation of the clear lens is seen in anterior chamber.

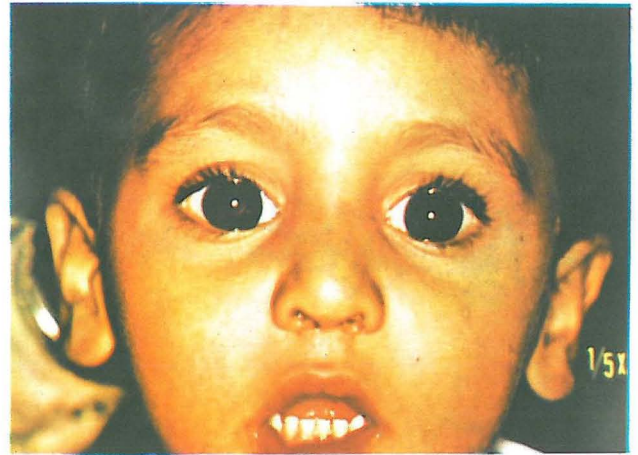

Fig 3: Corneal haziness is seen in the right eye.

the pupil of the left eye was dilated with phenylephrine 5% and tropicamide 1%, so the lens went into the vitreous cavity. Then pupils of both eyes were constricted with phospholine iodide 0.125%. Thereafter phospholine iodide was prescribed as one drop of 0.125% weekly. This once a week dosage kept the pupil at a small enough size to prevent lens dislocation into the anterior chamber.

Six months later, the patient complained of a decrease in visual acuity of his right eye. In examination, visual acuity of the right eye, with correction, was counting fingers from 2 meters. There was total retinal detachment with PVRB, seen in ophthalmoscopy. Multiple small retinal dialyses were seen in nasal periphery. They were obviously secondary to vitreous traction on the retinal periphery. The patient underwent a major operation consisting of pars plana lensectomy and deep vitrectomy and scleral buckling with external subretinal fluid drainage. The dislocated lens was brought into the anterior chamber with an intraocular cryo-probe and then lensectomy was performed there.

Three weeks later, the left eye underwent a prophylactic procedure consisting of an encircling band 240 and cryopexy of a small retinal hole at 2 o'clock near ora.

Postoperatively, the patient is doing very well. Retina is on and the patient has a visual acuity of counting fingers from 4 meters in his right eye and 20/30 in his left eye. The dosage of phospholine iodide has decreased to 0.06% q weekly in the left eye. No medication is used for the right eye. Postoperative follow up period has been about 4 months.

Case 2: Meysam A. (Figure 3), is a 3 year old boy and Massoud's brother, whose parents also noticed large corneas since birth. There was 2+ injection in the

right eye. An opacity was present in the lower part of the right cornea dating back to 2 days before this visit. The left cornea was clear. Horizontal diameters of both corneas were 15 mm and the anterior chambers were deep. Moderate iris atrophy was present in both eyes. The angle was open and the intraocular pressure was normal in both eyes.

Although the patient was uncooperative with the Snellen chart, he had central fixation with both eyes and maintained it. The refraction was:

$$\text{OD} + 10.50 - 1.00 \times 170^\circ$$

$$\text{OS} + 10.50 - 2.50 \times 10^\circ$$

In funduscopy of the right eye, vitreous strands with marked traction on pars plana and retinal periphery were obvious. Center of vitreous seemed optically empty. The clear lens was floating in vitreous.

In fundus examination of the left eye, degenerative changes of vitreous and traction of vitreous strands and membranes on pars plana and ora serrata was more severe compared with the right eye. Pigmentary changes of retinal inferior periphery and hypopigmentation of inferior pars plana were visible. Ciliary processes were longer than normal nasally. The dislocated lens was opacified in the left eye with a capsular plaque. As well as that, a vitreous strand was connected to nasal equator of lens.

The corneal opacity which was mentioned earlier and was the presenting sign of this patient was due to corneal edema secondary to contact of lens with corneal endothelium.

Using the same procedure as described for the previous case we managed the problem of lens dislocation in this patient also. The corneal edema disappeared following administration of topical steroids.

The patient's left eye underwent a prophylactic

procedure consisting of encircling band 240. The operated eye has done well postoperatively during the past 2 months.

The family history was unremarkable in these patients. The parents had another 5 year old son who was examined and found to be quite normal. The parents were not relatives and were also examined and no ocular problems were found.

RESULTS AND DISCUSSION

Frequent dislocation of lens from the vitreous cavity into the anterior chamber which took place two to three times a day resulted in corneal endothelial damage and subsequent corneal edema. The best method of treatment was found to be placing the patient in supine position and dilating the pupil with tropicamide and phenylephrine followed by dislocation of lens into vitreous cavity and then constricting the pupil in order to prevent later return of lens into anterior chamber. We strictly recommend avoiding any kind of surgery to remove the dislocated lens as far as possible. Only weekly administration of 0.06% or 0.125% phospholine iodide seems to be enough and with such low doses the danger of development of iris cyst is probably negligible, which we will report later.

The dislocated lens is usually clear and does not need to be removed. Even the presence of a cataractous lens as long as it is not associated with leakage of lens material and subsequent intraocular inflammation does not warrant lens removal.

Lens removal in these patients also requires a near total vitrectomy and phacofragmentation in the vitreous cavity or lensectomy after dislocating the lens into the anterior chamber, both of which carry a significant

intraoperative risk.

Anterior megalophthalmos is an early developmental anomaly which is inherited as an X-linked recessive disorder. The signs of this anomaly consist of megalocornea, deep anterior chamber, iris atrophy and lens dislocation. This disorder is almost always bilateral.

We have found marked vitreoretinal degeneration in our patients which has not been previously reported as far as available literature to us. Because of numerous strands and membranes in vitreous with severe traction on retinal periphery, we performed deep vitrectomy as well as scleral buckling when managing retinal detachment in the right eye of case 1. During pars plana vitrectomy, lensectomy was also done in the same manner as described previously.

Because of degenerative vitreoretinal changes which predispose these patients to retinal detachment, fundi should be checked regularly and prophylactic procedures should be performed when necessary.

Also, the patients should be closely observed regarding refractive errors and subsequent amblyopia² and the possibility of increase in intraocular pressure during follow up.

Accurate diagnosis of this anomaly and differentiating it from simple megalocornea, treatment of amblyopia and preventing optic nerve damage from the eventual increased intraocular pressure are also very important points.

REFERENCES

1. Duane T, et al: Clinical Ophthalmology. Vol 4. Philadelphia, Harper and Row, 16: 4-5, 1985.
2. Harley D, et al: Pediatric Ophthalmology. Vol. 1. Philadelphia, W.B.Saunders, 468-469, 1983.