

Case Reports

PRIMARY LEIOMYOSARCOMA OF THE URETER

D. MEHRABAN

From the Urology Section, Department of Surgery, Shariati Hospital, Tehran University of Medical Sciences, Tehran, Islamic Republic of Iran

ABSTRACT

Since 1943, fourteen cases of primary leiomyosarcoma of the ureter have been reported in English literature. The fifteenth case is presented here with a brief review of the significant aspects of the previous reports.

MJIRI, Vol.2, No.1, 67-69, 1988

INTRODUCTION

Benign and malignant neoplasms of mesenchymal origin are rare tumors, comprising less than three percent of all primary ureteral tumors.¹ Leiomyosarcomas arising from the ureter are extremely rare and including our case, only fifteen cases have appeared in English literature.

CASE REPORT

A 70 year old female was referred for further evaluation of a right non-functioning kidney on IVP. Her presenting complaint was of gross painless hematuria, several months in duration. Her right kidney was functioning perfectly two years ago, according to an IVP which was obtained for low-back pain (Fig. 1).

The significant features of her past history include hysterectomy for dysfunctional uterine bleeding 20 years ago, cholecystectomy for cholelithiasis two and a half years ago, and prolonged spastic colitis. Blood and urine tests were unremarkable except for microscopic hematuria. Urinary cytology was not obtained. A retrograde ureterography revealed a smooth filling defect in the right ureter at the cross-over region (Fig. 2).

The patient was explored through a right modified Gibson incision and a firm smooth mass measuring

7x4x4 cm was seen to have originated from the ureteral wall (Fig. 3).

It was well encapsulated and easily dissected from adjacent structures. Nephroureterectomy was accomplished through extension of the incision.

Histological examination revealed a tumor com-

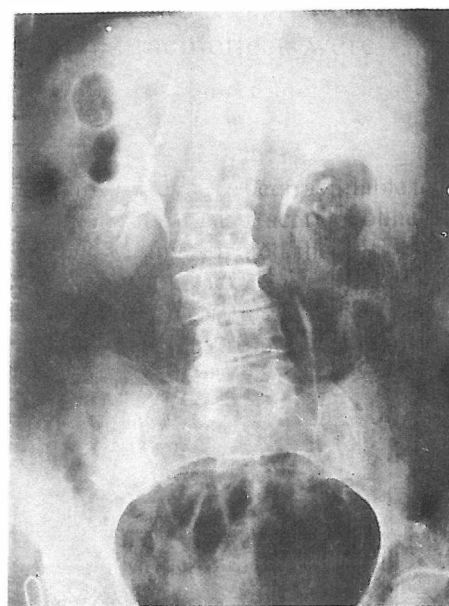


Figure 1. IVP taken for low back pain two years ago, showing normal right kidney and ureter.

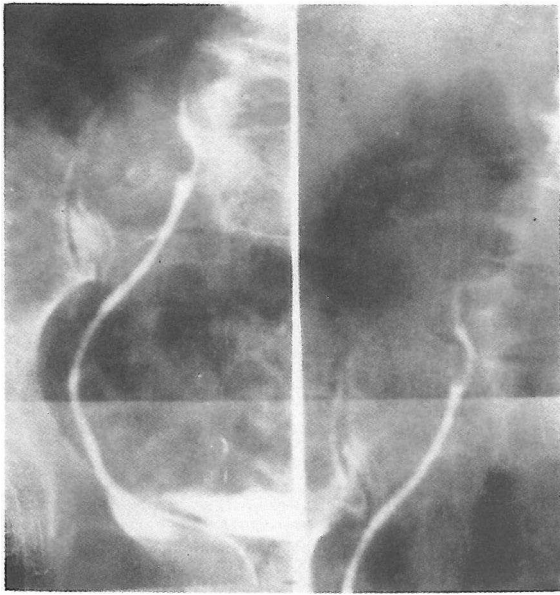


Figure 2. Right retrograde ureterogram. Smooth filling defect at the crossover region.


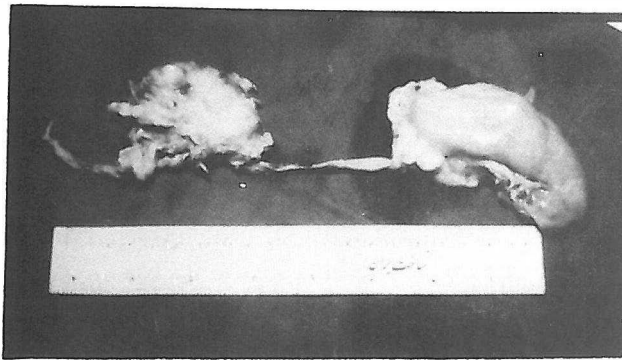


Figure 3. A and B. Photographs of the macroscopic specimen showing the right kidney and ureter with the tumor arising from the medial portion of the ureteral wall.

posed of bundles of rather uniform elongated cells with abundant eosinophilic cytoplasm and large hyperchromatic nuclei (Fig. 4). Its smooth muscle origin was confirmed using the Von Geison technique. Convalescence was uneventful and a complete metastatic workup was carried out which included abdominal CT scanning immediately post-operatively and at the third, sixth, ninth and twelfth months. All results were negative, and the patient is followed without therapy.

DISCUSSION

In a review of English literature conducted through Questel using Medline and Pascal databases (9-9-87), it became evident that this is the 15th case of primary leiomyosarcoma of the ureter.

The first documented case was described by Rade-maker in 1934,¹ and the last two cases by Gislason and Arnarson in 1984.² One interesting feature of this malignancy is that the majority of cases have been females.³ Including this case, the female: male ratio is 12:3. Hematuria has been the presenting symptom in three previous cases, bringing the number to four with this case, but the majority presented with flank pain.³ If the diagnosis is suspected, more effective use of available imaging studies seems rewarding, as reported by Roemer and associates.¹

Surgical excision of the tumor has offered no difficulty, even when partial resection of the vena cava has become necessary.²

The prognosis is guarded. Even when metastases have been identified at the time of surgery, they have appeared five months later and caused death within 15 months.¹ However, survival beyond five years post-operatively has occurred.¹

The role of radiation therapy is undefined at present. Rushton and colleagues used 4000 rads to the tumor bed,⁴ Roemer and associates used 5040 rads in 28 fractions,¹ but Gislason and Arnarson "elected not to irradiate" their patients due to the generally radioresistant nature of leiomyosarcomas.

Chemotherapy has induced a complete remission of pulmonary metastasis by using doxorubicin HCl and dimethyltriazeno imidazole carboxamide.¹

Determining an established and reasonable approach to managing this malignancy requires further experience but from available literature, it seems that surgery as radical as practical is indicated, and chemotherapy with possible tumorbed irradiation should be started when metastases are present.

There also should be an effort on the part of the pathologist to determine possible morphological evidence of tumor aggressiveness.

Lastly, if the distal ureter is not removed at the time of surgery, a yearly retrograde study of the ureteric stump should be considered.

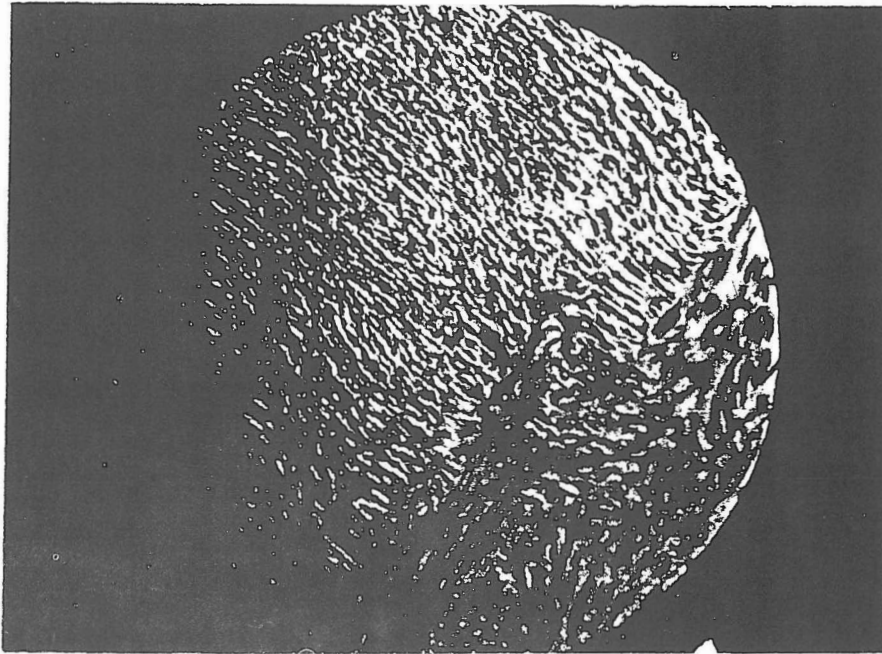


Figure 4. Low-power photomicrograph of the tumor showing bundles of uniform elongated cells with abundant eosinophilic cytoplasm and large hyperchromatic nuclei.

REFERENCES

1. Roemer CE, Pfister RC, Brodsky G, Sacknoff EJ: Primary leiomyosarcoma of ureter. *Urology* 16 (5): 492-5, 1980.
2. Gislason T, Arnarson OO: Primary ureteral leiomyosarcoma. *Scand J Urol Nephrol* 18 (3): 253-4, 1984.
3. Rushton HG, Sens MA, Garvin AJ, Turner WR: Primary leiomyosarcoma of the ureter: a case report with electron microscopy. *J Urol* 129(5): 1045-6, 1983.
4. Werth DD, Weigel JW, Mebust WK: Primary neoplasms of the ureter. *J Urol* 125 (5): 628-31, 1981.
5. Shah JP, Kothari AB: Leiomyosarcoma of the ureter. *J Urol* 105: 505-6, 1971.

