

INFECTIVE ENDOCARDITIS IN CHILDREN

SHAHLA ROODPEYMA, M.D.

From the Department of Pediatrics, Ayatollah Taleghani Medical Center, Shahid Beheshti University of Medical Sciences, Tehran, Islamic Republic of Iran.

ABSTRACT

A total of 14 cases of infective endocarditis (IE) in children aged 6 months to 10 years were seen from December 1987 to December 1992 at the pediatric unit of Ayatollah Taleghani Medical Center. The majority of patients (12 of 14) were between 5 and 10 years of age. Acyanotic congenital heart disease was known to preexist in 78.6% and rheumatic valvular heart disease in 21.4% of cases. Organisms were identified by blood culture in 50%, the majority being *Streptococcus viridans* (36% of cases). Vegetations were detected by echocardiography in 64%. The overall death rate was 21.4%. Two patients with aortic stenosis developed IE after cardiac surgery for repair of stenotic valves and both of them died. One patient with rheumatic aortic and mitral valve insufficiency underwent valve replacement due to intractable heart failure.

In conclusion, the frequent presence of underlying heart disease, the rarity of IE in infancy, and the ominous prognosis of postoperative endocarditis and aortic valve involvement are emphasized.

Key Words: Children, Infective endocarditis (IE), Congenital heart disease (CHD), Valvular heart disease.

MJIRI, Vol. 8, No. 4, 221-224, 1995.

INTRODUCTION

Infective endocarditis (IE) is a severe infection which is becoming more frequently recognized in children. The reported incidence of IE in infancy and childhood is one in 4500 hospital admissions.^{1,4} Most studies of IE in children have been reported from industrialized countries,^{3,6,10,11,12,15} whereas only a few have been reported from nonindustrialized countries.^{1,7} In this study, I will present my experience with IE in a group of Iranian children who were admitted to a pediatric department over a 5-year period.

MATERIALS AND METHODS

Charts were reviewed on 14 patients discharged from the pediatric ward of the Ayatollah Taleghani

Medical Center from 1987 to 1992 with a diagnosis of infective endocarditis. The entire hospital course of each patient was reviewed. The following data was acquired from the patients' medical record: basic identifying information, dates of hospitalization, follow-up status, antecedent diseases, predisposing factors, symptoms, signs, laboratory data, treatment, course, and complications. Patients with previously known congenital or rheumatic heart disease (RHD) were accepted into the study if they fulfilled at least two of the following criteria:

- 1- Vegetations verified by echocardiography
- 2- Fever without any extracardiac foci
- 3- Bacteremia without an extracardiac focus
- 4- Symptoms compatible with embolism

Standard methods were employed for obtaining and processing blood cultures, as well as for the identification and isolation of microorganisms.

Infective Endocarditis in Children

Table I. Significant clinical and laboratory features of 14 children with IE and their treatment, complications and outcomes

Case	Age	Sex	Clinical and laboratory findings at time of diagnosis	Underlying heart disease	Possible source	Blood culture	Echocardiography	Treatment	Complications	Outcome
1	9 years	F	Fever, heart murmur, ↑ ESR, leukocytosis	PDA	unknown	<i>Streptococcus viridans</i>	no vegetation	P+S	none	survived
2	9 years	F	Fever, heart murmur, CHF, splenomegaly, anemia, ↑ ESR, leukocytosis	PDA	unknown	-----	PA vegetation	P+S	none	survived
3	9 years	M	Fever, heart murmur, anemia, splenomegaly, petechiae, ↑ ESR, leukocytosis	VSD	unknown	Klebsiella	RV vegetation	C	CHF, none	survived
4	2 years	M	Fever, heart murmur, CHF, anemia, ↑ ESR	PDA	unknown	-----	PA vegetation	P+G	none	survived
5	7 years	F	Fever, heart murmur, CHF, anemia, ↑ ESR	RHD(MR)	unknown	-----	MV vegetation	P+S	none	survived
6	9 years	F	Fever, heart murmur, ↑ ESR, leukocytosis	VSD	unknown	<i>Streptococcus viridans</i>	no vegetation	P+S	none	survived
7	6 years	F	Fever, heart murmur, CHF, ↑ ESR	VSD+CO.A	unknown	<i>Streptococcus viridans</i>	no vegetation	P+G	none	survived
8	5 years	M	Fever, heart murmur, splenomegaly, ↑ ESR	AS	unknown	<i>Streptococcus viridans</i>	AV vegetation	P+G	none	survived
9	6 months	M	Fever, heart murmur, CHF, splenomegaly, anemia, ↑ ESR, leukocytosis	VSD	unknown	-----	RV vegetation	V+G	none	unknown
10	10 years	F	Fever, heart murmur, ↑ ESR	PDA	unknown	<i>Streptococcus viridans</i>	no vegetation	P+S	none	survived
11	9 years	M	Fever, heart murmur, CHF, anemia, hematuria, ↑ ESR	AS	cardiac surgery	-----	AV vegetation	V+G	cerebral embolism	died
12	7 years	M	Fever, heart murmur, anemia, ↑ ESR, leukocytosis	AS	cardiac surgery	-----	AV vegetation	V+G	renal acute	died
13	6 years	M	Fever, heart murmur, CHF, anemia, ↑ ESR, leukocytosis	RHD(MR+AR)	unknown	-----	AV vegetation	V+G	MV replacement	survived
14	9 years	M	Fever, heart murmur, CHF, anemia, petechiae	RHD(MR)	unknown	<i>Staphylococcus aureus</i>	-----	V+G	sepsis + DIC, ↑ ESR	died

M= male; F= female; CHF= congestive heart failure; ↑ = increased; PDA= patent ductus arteriosus; VSD= ventricular septal defect; RHD= rheumatic heart disease; MR= mitral regurgitation; CO.A= coarctation of aorta; AS= aortic stenosis; AR= aortic regurgitation; PA= pulmonary artery; RV= right ventricle; MV= mitral valve; AV= aortic valve; P= penicillin; S= streptomycin; C= ceftriaxone; G= gentamicin; V= vancomycin; DIC= disseminated intravascular coagulation.

Predisposing events, including dental procedures, were accepted as portal of entry if they occurred within 4 weeks prior to the first symptoms of IE. Recent cardiac surgery (less than 2 months before onset of symptoms) was accepted as a predisposing event. Recent antibiotic treatment was defined as antibiotic therapy within two weeks prior to admission.

Parenteral antibiotics were started in all patients after taking multiple blood cultures. In patients with a good general condition, antibiotic therapy was usually initiated with a combination of aqueous penicillin G and an aminoglycoside. In patients with critical general conditions, vancomycin plus gentamicin was administered. All patients were treated intravenously for a minimum period of 4 weeks. Autopsy was not possible in any of the patients who died, mainly because parents refused permission and wanted to bury the dead immediately according to traditional and religious rites.

RESULTS

In this study, which was performed in a university hospital, all pediatric cases with a discharge diagnosis of IE were reviewed. Their significant clinical and laboratory features are summarized in Table I. The mean

age of the patients was 7 years with a range of 6 months to 10 years. 86%(12 of 14) were 5 to 10 years old. Of 14 children, 8 (57%) were boys and 6 (43%) were girls (M/F= 1.3/1). Fever of variable duration and grade, loss of appetite and weight loss were seen in all patients. Cardiac murmurs were auscultated in all patients and congestive heart failure (CHF) was present in 9 (64%) cases.

Congenital heart disease (CHD) was the predominant lesion, occurring in 11 (78.6%) children. 4 (28.6%) patients had ventricular septal defect (VSD) and in one of them it was accompanied by coarctation of the aorta. 4 had patent ductus arteriosus (PDA) and the other three (21.4%) suffered from aortic stenosis. In 3 patients (21.4%) rheumatic valvular heart disease was diagnosed. In all of them mitral valve incompetence was present and in a 6 year old boy it was accompanied by aortic valve insufficiency. All of the above anomalies were acyanotic.

Splenomegaly was detected in 4 (28.6%) patients. Peripheral mucocutaneous manifestations such as Osler's nodes, Janeway lesions and splinter hemorrhage were not seen in any patient, but two (14%) had subconjunctival petechiae. Anemia (defined as a hemoglobin concentration of less than 10g/dL) was present in 9 (64%) cases. An elevated erythrocyte sedimenta-

tion rate (defined as an ESR greater than 35 mm in the first hour by the Westergren method) was present in all patients and in the majority of them it was greater than 50 mm in the first hour. A mild leukocytosis (defined as a leukocyte count greater than $13000/\text{mm}^3$) was demonstrated in 7 patients (50%). Microscopic hematuria was seen in one patient. Blood cultures were positive in 7 patients (50%) and negative in the rest. Of 7 culture-positive cases, *Streptococcus viridans* was found in 5, *Staphylococcus aureus* in 1, and klebsiella in 1 case.

Echocardiography (M-mode and two-dimensional) was performed in all patients and vegetations were detected in 9 (64%) of them. In one patient (no.13) with RHD, surgery was required because of intractable heart failure. His aortic valve was repaired and mitral valve replaced. One patient (no.9) had been discharged by his parents before completing his course of therapy and in spite of physician's advice. Three patients (21.4%) died, two of which were boys with aortic stenosis who developed IE after cardiac surgery and repair of their stenotic valves. One of these two children (case no. 11) died because of a sudden embolic cerebrovascular accident and the other one died due to renal impairment manifested by oliguria and an elevated serum creatinine level. The third patient died in septic shock.

DISCUSSION

The present study is an analysis of patients with IE diagnosed over a period of 5 years at our center. In this study, 12 of 14 patients were between 5 and 10 years of age. This is in accordance with the observation of IE in older children.^{5,10}

In Western reports, positive blood cultures were high and varied from 80% to 92% in different series.^{4,14} In two reviews from developing countries,^{1,7} positive blood cultures were reported in 47.8% and 58% respectively. In our study bacterial isolation was achieved in 7(50%) patients. We ascribe the high proportion of negative cultures to previous antibiotic therapy, fastidious organisms with difficult culture requirements, very low numbers of circulating organisms, and less than meticulous culture techniques. Suppression of blood culture positivity by outpatient antibiotic therapy in patients with bacterial endocarditis has been reported by Pazin et al.¹³ Patients who have received antibiotics should have more cultures taken initially, and all patients suspected of having IE should have additional blood cultures drawn if the first cultures fail to grow an organism and symptoms persist.²

The introduction of echocardiography has made it possible to demonstrate vegetations in 75-80% of cases of IE.⁹ Hence one would expect that the diagnosis of IE

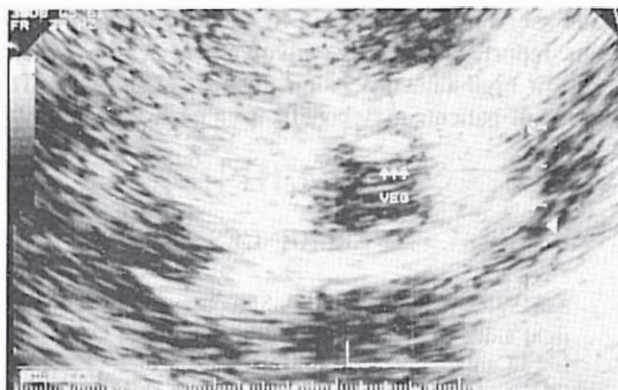

Fig. 1. Case no. 13: Vegetation at the ring of the aortic valve.

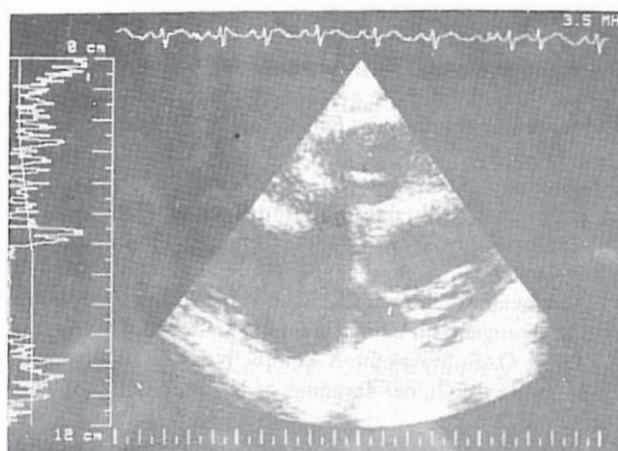


Fig. 2. Case no. 3: VSD and vegetation at the right ventricular surface of the interventricular septum.

could be established earlier. There is, however, no doubt that in the future the transoesophageal echocardiographic approach will yield a better access in clinically suspected cases with normal transthoracic echocardiographic studies.¹⁶ In the present study, two-dimensional echocardiography revealed vegetations in 9 of 14 (64%) cases.

Similar to several previous reports,^{11,14} in the present review no dental procedures were performed prior to IE. Poor dental hygiene is possibly of greater importance than the dental procedures themselves as a factor of susceptibility to IE.

A special note concerning "high-risk" individuals is appropriate. In the pediatric age group, these so-called "high-risk" individuals include those with prosthetic heart valves, those with aortic valve stenosis or insufficiency, and those patients with surgically constructed systemic to pulmonary arterial shunts.⁸ In a study by Bahl et al.¹ including 23 patients with right heart endocarditis, five of six patients with postoperative endocarditis died, signifying an ominous prognosis for

Infective Endocarditis in Children

this subgroup when treated by medical means only. In this report, aortic valve involvement was associated with a high rate of complications and mortality. This group of patients may benefit from early surgical intervention.

REFERENCES

- 1- Bahl VK, Vasan RS, Jain P, Shrivastava S: Spectrum of right sided infective endocarditis: an Indian experience. *Intl J Cardiol* 35: 187-193, 1992.
- 2- Baltimore RS: Infective endocarditis in children. *Pediatr Infect Dis* 11 : 907-12, 1992.
- 3- Berkowitz FE, Dansky R: Infective endocarditis in Black South African children: report of 10 cases with some unusual features. *Pediatr Infect Dis J* 8: 787-791, 1989.
- 4- Frankin CD: The aetiology, epidemiology, pathogenesis and changing pattern of infective endocarditis, with a note on parophylaxis. *British Dental Journal*, 172: 369-373, 1992.
- 5- Gersony WM: Infective endocarditis. In: Behraman RE, Kliegman RM, (eds.) *Nelson Textbook of Pediatrics*, Philadelphia, W.B. Saunders Co., 1199-1204, 1992.
- 6- Hansen D, Schmiegelow K, Jacobsen JR: Bacterial endocarditis in children: Trends in its diagnosis, course, and prognosis. *Pediatr Cardiol* 13: 198-203, 1992.
- 7- Ifere OAS, Masokano KA: Infective endocarditis in children in the Guinea savannah of Nigeria. *Annals of Tropical Paediatrics* 11: 233-240, 1991.
- 8- Kaplan EL: Bacterial endocarditis prophylaxis. *Pediatric Annals* 21: 249-255, 1992.
- 9- Kaye REW, Frank DM, Byrum CJ, Blackman MS, Sondheimer HM, Bove EL: Two-dimensional echocardiographic assessment of infective endocarditis in children. *Am J Dis Child* 137: 851-856, 1983.
- 10- Moethilalh R, coovadia HM: Infective endocarditis in thirteen children: a retrospective study (1974-1981). *Ann Trop paediatr* 2: 57-62. 1982.
- 11- Nissen H, Nielsen PF, Frederiksen M, et al: Native valve infective endocarditis in the general population: a 10-year survey of the clinical picture during the 1980's. *European Heart Journal* 13: 872-877, 1992.
- 12- Parras F, Bouza E, Romero J, et al: Infectious endocarditis in children. *Pediatr Cardiol* 11: 77-81, 1990.
- 13- Pazin GJ, Saul S, Thompson ME: Blood clure positivity, suppression by outpatient antibiotic therapy in patients with bacterial endocarditis. *Arch Intern Med* 142: 263-268, 1982.
- 14- Sholler GF, Hawker RE, Celermajar JM: Infective endocarditis in childhood. *Pediatr Cardiol* 6: 183-186, 1986.
- 15- Schollin J, Bjarke B, Wesstrons G: Infective endocarditis in Swedish children. *Acta Paediatr Scand* 75: 993-1005, 1985.
- 16- Taams MA, Gussenhoven EJ, Bos E, et al: Enhanced morphological diagnosis in infective endocarditis by transoesophageal echocardiography. *Br Heart J* 63: 109-113, 1990.