

Case Reports

SUBCUTANEOUS FASCIOLIASIS: A RARE COMPLICATION

MOHSEN EMAMI AL-AGHA* AND AMID ATHARI**

From the* Department of Pathology, Faculty of Medicine, Kermanshah University of Medical
Sciences, Kermanshah, and the ** Department of Parasitology, Faculty of Medicine, Shahid Beheshti
University of Medical Sciences, Tehran, Islamic Republic of Iran.

ABSTRACT

A case of ectopic fascioliasis due to migration of an immature *Fasciola hepatica* fluke is described in a 23 year old woman from western Iran.

MJIRI, Vol. 8, No. 4, 269-270, 1995.

INTRODUCTION

Fascioliasis is a zoonotic infection caused by the sheep liver fluke, *Fasciola hepatica*. Man is an accidental host for this parasite and human infection occurs by ingestion of watercress contaminated with infective metacercariae. Human fascioliasis has been reported from many parts of the world, particularly in sheep-rearing areas.¹ However, in Iran *F. hepatica* is widespread among herbivorous animals but human cases are mainly restricted to northern provinces.² Ectopic fascioliasis is not an uncommon complication, but few reports on subcutaneous localization of immature flukes are available.^{3,4}

CASE REPORT

A 23 year old housewife living in Sahneh (west part of Iran) was admitted to a private clinic with a painful mass 2×3 cm in size in her right axillary area accompanied with right upper quadrant pain and intermittent fever. The growth of the mass had started 3 months prior to admission and had grown progressively larger. Macroscopically the nodule was rigid and indurated without any discharge. Abdominal examination revealed no abnormality. Lymphadenopathy was not present. The chest x-ray was normal. In hematological tests, the white cell count was 8300/mm³ with 3% eosinophils,

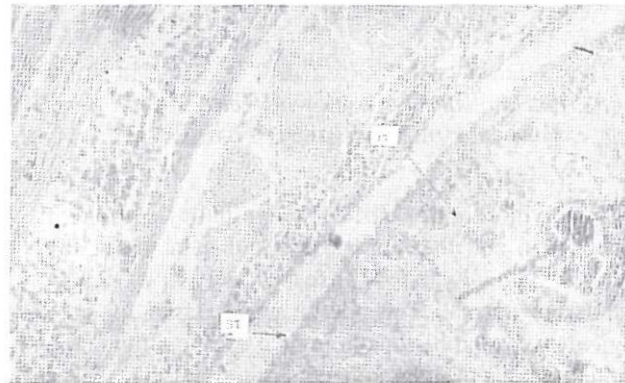


Fig. 1. Longitudinal section of immature *F. hepatica*.

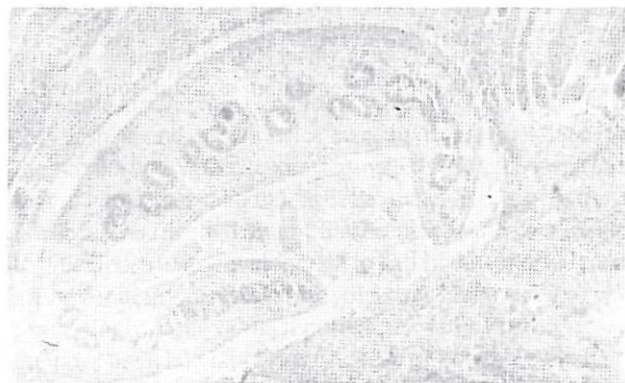

Fig. 2. Higher magnification of the parasite showing the spiny tegument (ST) and parenchymal cells (PC).

Subcutaneous Fascioliasis




Fig. 3. *Falcaria vulgaris*; a plant suspected to contain metacercariae.

59% polymorphonuclear, 35% lymphocytes, and 3% monocytes, and the hemoglobin and hematocrit levels were 14.3 mg/dl and 44% respectively. Liver function tests were normal. The nodule was excised for pathological study and histopathological examination demonstrated masses of disorganized striated muscle fibers infiltrated by lymphocytes, histiocytes, plasma cells, and mainly eosinophils. Many foci of granulomatous reactions were seen surrounding the foreign bodies. In one of the sections a longitudinal section of an immature *F. hepatica* (Figs. 1&2) was observed surrounded by inflammatory cells and degenerated skeletal muscle fi-

bers. IFAT (indirect fluorescent antibody test) was performed for fascioliasis and the result was positive, but fasciola ova were not found in the feces.

DISCUSSION

Our patient used to live on a farm and had close contact with livestock. She also gave a history of continuous consumption of a raw vegetable locally named "Paghaze" and scientifically named "*Falcaria vulgaris*" (Fig. 3). It seems that she has eaten the mentioned grass contaminated with metacercariae.

Supporting our findings, Prociv et al.⁴ emphasized that migratory fascioliasis can present superficially and not necessarily in association with peripheral blood eosinophilia.

Concerning the diagnostic features of trematoda in longitudinal sections, the following characteristics are of great importance:

- 1- Leaf-shaped body.
- 2- Spiny tegument (ST).
- 3- Parenchymal cells scattered throughout the matrix (PC).

Regarding this report and similar observations, it appears that in any undiagnosed cutaneous nodule, ectopic migration of parasites should be considered as an etiological agent.

REFERENCES

1. Harinasuta T, Bunnag D: Fascioliasis. In: Warren KS, Mahmoud AF(eds), Tropical and Geographical Medicine, McGraw-Hill, 478-479, 1990.
2. Assmar M, et al: Seroepidemiological investigation of fascioliasis in northern Iran. Med J Islamic Rep Iran 5(1,2): 23-27, 1991.
3. Dowlati Y, Dowlati A and Seyyedi BV: Cutaneous fascioliasis. Med J Islamic Rep Iran 1: 62-65, 1987.
4. Prociv P, Walker JC, Whitby M: Human ectopic fascioliasis in Australia: first case reports. Med J Aust 156(5): 349-51, 1992.