

AUTOANTIBODIES AGAINST THYROID CONSTITUENTS AND CIC IN GRAVES' DISEASE ASSOCIATED WITH EXOPHTHALMUS

S. RAFIEI, M.D., M. NAKHJEVANI,* M.D., AND
M. GHARAGOZLOU***, D.V.M.

*From the Dept. of Immunology and *Endocrinology, School of Medicine, Tehran University of Medical Sciences, Tehran, and **Bu Ali Sina University of Medical Sciences, Hamedan University, Hamedan, Islamic Republic of Iran.*

ABSTRACT

32 patients (19 female, 13 male) suffering from Graves' disease with exophthalmus and five without exophthalmus were studied for various autoantibodies including anti-thyroglobulin (ATAB), anti-microsomal antibody (AMAB), anti-parietal antibodies (APAB) and also circulating immune complex (CIC). 43 normal subjects were tested concurrently.

Immunofluorescent technique was employed for autoantibody detection. Frozen sections of human thyroid tissue and rat stomach were utilized as antigen sources for thyroid and parietal CIC estimated by PEG (polyethylene glycol) precipitation method and the specific classes of immunoglobulins were detected by SRID (single radial immunodiffusion).

The results were analyzed statistically. From the point of view of presence of antibodies, there were significant differences between patients and control groups ($P=0.005$). Comparing Graves' with or without exophthalmus, no significant difference was seen between autoantibody levels, but higher titers of CIC were elucidated in the latter group.

We will discuss that autoantibodies have an important role in thyroid autoimmune diseases and also that CIC may have a critical role in the pathogenesis of exophthalmus associated with Graves' disease.

MJIRI, Vol. 8, No. 3, 149-153, 1994.

INTRODUCTION

Graves' disease is a common disorder which is considered to be an autoimmune disease. It was first described by Robert Graves in 1835.¹

Patients with hyperthyroidism due to Graves' disease have a high prevalence of autoantibodies directed toward several components of the thyroid gland. Other body organs such as stomach parietal cells and pancreatic islet cells may also be targeted. Clinical manifestations are related to

presence of these autoantibodies.¹⁻⁴ The suspected autoantigens are thyroglobulin, thyroid microsomes and TSH receptors.^{5,10} Thyroglobulin antigens are present on the thyroid cell surface and anti-thyroglobulin antibodies have a binding capacity for iodothyronines and interfere with the RIA test (T3 and T4).¹¹

Microsomal antigen is a protein with a molecular weight of about 100-110 KD and its major antigenic component is thyroid peroxidase (TPO). TPO is known to be a membrane protein of exocytotic vesicles containing newly synthesized

Autoantibodies and CIC in Graves'

thyroglobulin. It is believed that cytoplasmic microsomal antigen is also presented on the surface of human thyroid cells.¹⁴ It is exclusively located in the apical microvilli of thyroid follicular cells facing the colloid space.¹⁵

TPO has the ability to catalyse thyroid hormones.¹² Some autoantibodies may block the catalytic function of the enzyme. The finding of anti-TPO antibodies in chronic thyroiditis suggests that it differs from the TPO antibodies which may occur in the absence of disease and its production may be due to cross reaction between thyroglobulin and TPO.¹³

Recent reports of anti-thyroglobulin and anti-membrane antibodies indicate that there is an association between the presence of these two antibodies and dietary iodine, which increases their production.¹²

An antibody to a colloid component (C2) other than thyroglobulin, is demonstrable in patients with Graves' disease.¹⁵

The ophthalmopathy of Graves' is characterized by lymphocytic infiltration of retroorbital muscles with edema and mucopolysaccharide deposition. The degree of infiltration correlates with the presence of some autoantibodies in patient sera and action of circulating immune complexes (CIC). This study investigated the autoantibodies and their possible role in exophthalmus in Graves' patients.^{2, 17-19}

PATIENTS AND METHODS

32 patients with hyperthyroidism and exophthalmus were studied. Their eye signs were compatible with grade III or higher stage of eye involvement. 43 healthy age-matched persons were selected as a control group. They had no evidence of any systemic or thyroidal illness. Thyroid function tests including FT4I and serum total T3 were normal in this group. A patient control group including 13 with multinodular goiters, six with surgically proven Hashimoto's thyroiditis and 43 with primary hypothyroidism were tested simultaneously.

Antigens

Human thyroid tissue was utilized as thyroid antigen source.

Techniques

1) Immunofluorescent technique (IFT) was performed as conventional methods, using fluorescein conjugated total antihuman immunoglobulins.

2) Looking for antimicrosomal antibody (AMA), thyroid frozen sections were used as slide preparation with no further treatment, but for anti-thyroglobulin antibody (ATA), the sections were incubated with absolute methanol for 10 min. at 56°C.

3) Antiparietal antibody (APA) was detected by IFT and stomach frozen section was used as antigen.

4) Circulating immune complex was detected by Haskova method (based on protein precipitation by PEG 6000). The final contents of immune complex were analysed by Sigma RID plates.

Statistical analysis

The rate of autoantibodies and CIC presence between individual groups were compared by t,t', chi-square correction and Fisher tests.

RESULTS

Fig. 1 demonstrates the sum of patient and controls divided by sex and clinical manifestations. Some Graves' cases were associated with other diseases, one with scleroderma and one with diabetes mellitus. Anti-microsomal

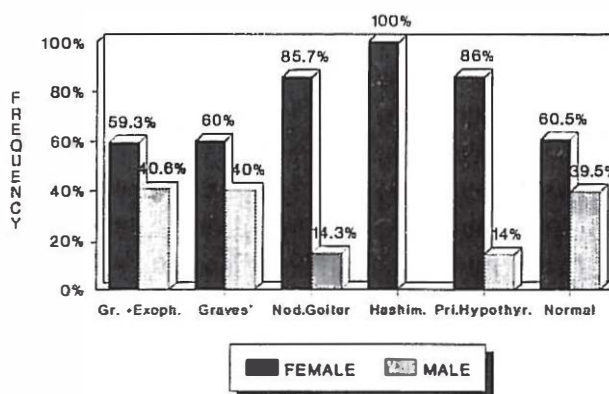


Fig. 1. Sex distribution in patients and normal controls.

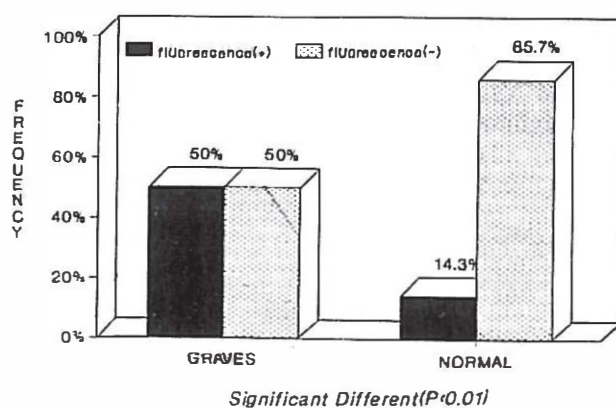


Fig. 2. Comparison of patients who have Graves' disease & exophthalmus with normal subjects from the point of view of ATMAb.

Table I. Various autoantibody titers in patients and controls.

Parameters Groups	Anti-thyroid microsomal antibody (ATMAB) No. & %				Anti-thyroglobulin antibody (ATAB) No. & %								Anti parietal cell antibody Intensity, No. & %		
	1/10	1/20	1/40	1/80	1/10	1/20	1/40	1/80	1/160	1/320	1/640	1/1280	++	+++	++++
Graves' with exophthalmus	4 12.5%	3 9.37	2 6.25	10 31.2	4 12.5	2 6.25	1 3.13	5 15.6	4 12.5	-	-	-	5 1	6 18.7	2 6.25
Graves' without exophthalmus	-	-	2 40	-	-	-	-	-	1 20	-	-	1 20	2 50	-	-
Hashimoto's disease	-	1 16.6	-	3 50	2 33.33	-	-	-	2 33.33	-	-	1 16.6	-	2 40	-
Nodular Goiter	1 5.2	1 5.26	2 10.5	-	1 7.14	1 7.14	1 7.14	-	-	-	-	-	2 16.6	3 25	-
Primary Hypothyroidism	3 8.11	4 10.8	2 5.4	3 8.11	3 10.8	4 10.8	1 2.7	2 5.4	2 5.4	2 2.7	1 2.7	1	-	-	-
Normal population	-	2 5.1	-	2 4.7	1 2.3	-	-	-	-	-	-	-	5 12.29	3 7.3	-

antibody detected by IFT revealed a yellow-greenish pattern of thyrocyte cytoplasm in positive titers.

Table I shows pair-wise comparison between patients and control groups for various autoantibodies. The highest titer of AMA (1:80) was seen in Graves' and Hashimoto's disease, but for ATA, a titer of 1:128 was seen in the Hashimoto group. APA could be detected only in the Graves' group.

In Fig. 2, the frequency and percent of AMA in the study groups are compared. There was a significant difference between patients and normal controls ($P < 0.0021$) but no

difference was seen between males and females.

Comparing the study groups for ATA, again we found a significant statistical difference between normal and Graves' patients ($P < 0.0052$, Fig. 3).

Table II demonstrates the presence, amount and frequency of CIC in the various groups. There was a significant difference between patients with and without ophthalmopathy.

The RID evaluation is shown in Table III. The dominant antibody was IgG, and we detected Clq and C3 in the CIC solution.

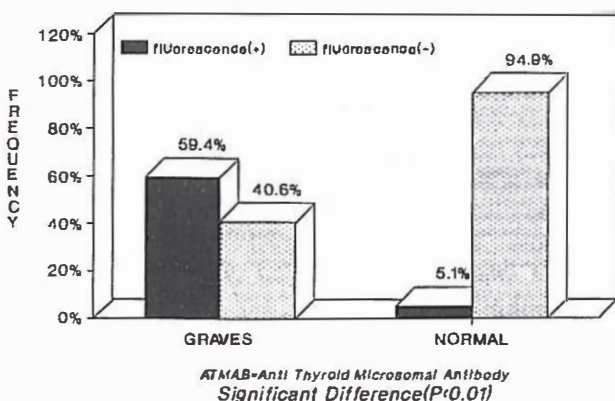


Fig. 3. Comparison of patients who have Graves' disease & exophthalmus with normal subjects from the point of view of ATAB.

DISCUSSION

Graves' disease is considered as an autoimmune disease. For the first time in Iran, we have assayed the various immunological aspects in 32 Graves' subjects with or without ophthalmopathy and 108 normal and patient controls. Their mean age was 40 for females and 50 for males.

Different autoantibodies including anti-microsomal antibody (AMA), anti-thyroglobulin antibody (ATA) and anti-parietal antibody (APA) were estimated by immunofluorescent test (IFT).

Our results indicate a significant difference between compared groups. It has been claimed that AMA and ATA inhibit the formation of thyroid hormones,²⁰ and they possess cytolytic ability due to antibody dependent cell-mediated

Autoantibodies and CIC in Graves'

Table II. Comparison between different test groups for CIC.

Parameters Test Groups		CIC		Total No. & %	X ² Test
		1.3 mg/ ml No. & %	1.3 mg/ ml No. & %		
Graves' with exophthalmus	Male	10 76.9	3 23.1	13 100	Non- significant
	Female	12 53.5	7 36.5	19 100	
Graves' with exophthalmus & normal population	Male & Female	22 72.1	10 27.9	32 100	significant
	Male & Female	2 5.8	39 84.2	41 100	difference
Graves' with exophthalmus & Graves' without exophthalmus	Male & Female	22 53.5	10 46.5	32 100	significant
	Male & Female	0 0	5 100	5 100	difference
Graves' with exophthalmus primary hypothyroidism	Male & Female	22 53.5	10 46.5	32 100	significant
	Male & Female	9 26.5	25 73.5	34 100	difference

Table III. Immune complex composition in patients' sera.

Sera No.	CIC mg/mL	CIC COMPOSITION (SRID METHOD)				
		IgG	IgM	IgA	C3	C1q
121	3.15	+	+	-	+	+
101	0.50	+	+	-	+	+
123	1.15	+	-	-	+	+
305	1.30	+	+	-	+	+
309	1.05	+	+	-	+	+
629	1.95	+	-	-	+	+
628	1.30	+	-	-	+	+
636	1.80	+	+	-	+	+
611	2.60	+	+	-	+	+
625	0.50	+	+	-	+	+

ated cytotoxicity (ADCC) on thyroid follicular cells and are believed to be involved in thyroid destruction.^{21,22} We suggest that looking for antimicrosomal and anti-thyroglobulin antibodies may play a critical role not only in diagnosis, but also for prognosis.²¹ It has been reported that a significantly lower rate of relapse of hyperthyroidism occurred in those patients who were positive for both AMA and ATA (11%) compared to those who were positive only for AMA (25%)

and those negative for both (39%). The possible mechanism is that patients with positive titers for AMA and ATA had destruction of thyroid cells due to autoantibodies.²⁴⁻²⁶

It should be born in mind that the probable expression of MHC II antigens on thyroid epithelial cells following interferon gamma induction may play a role in recognizing the thyroid antigen by T cells and evoke thyroid destruction in certain cases.¹²

It is notable that these two antibodies (AMA and ATA) operate in opposition to thyroid stimulating antibodies and the interaction between these two opposing sets of antibodies determines eventual thyroid function and the prognosis of Graves' disease.²⁷⁻³¹ The presence of APA in patients confirms the autoimmune etiology for Graves' disease.

Looking for circulating immune complexes (CIC), we found a significant difference between normal and patient groups. Our data is supported by other studies which suggest that CIC are formed by autoantibody and thyroid antigen interaction. Their deposition and complement fixing component are potentially damaging to the thyroid and other organs including kidney and retroorbital tissues.

Thyroglobulin has been known as a nephritogenic antigen.³² CIC deposition in eye muscles and the postorbital space may be responsible for Graves' ophthalmopathy.

REFERENCES

- Gossage AAR: The pathogenesis of Graves' disease. *Clinics in Endocrinology and Metabolism* 14 (2): 299, 1985.
- Reginal H: *Fundamentals of Clinical Endocrinology*. 4th ed, Edinburgh. Churchill-Livingstone, pp. 82-89, 97-100, 122-143, 1989.
- Valente WA: Antibodies that promote thyroid growth, a distinct population of thyroid stimulating auto-antibodies. *New Eng J Med* 309: 1028, 1983.
- Zakarija M: Evidence supporting the identity in Graves' disease of Thyroid Stimulating Antibody. *J Clin Invest* 81(3): 879, 1988.
- Wortsman J: Immunoglobulins that cause thymocyte proliferation. *Am J Med* 85: 117, 1988.
- Nakajima Y: Characteristics of antibodies to calmodulin in patients with Graves' disease. *Endocrinol Jpn* 34(4): 513, 1987.
- Cho BY: Spontaneous hypoglycemia and insulin autoantibodies in patients with Graves' disease. *Diabetes Res Clin Pract* 3(3): 119-124, 1987.
- Baethge BA: Antibodies to nuclear Ag in Graves' disease. *J Clin Endocrinol* 66(3): 485, 1988.
- Noborou H: Identification of a thyroid microsomal antigen by Western blot and immuno-precipitation. *J Clin Endocrinol Metab* 61: 121, 1985.
- Nakamura S: Thyroid hormone autoantibodies in two cases of Graves' diseases. *Endocrinol J* 33(6): 751, 1986.
- Himsworth RL: Studies on the antigenicity of human thyroglobulin. *Life Sciences* 32: 119-123, 1983.

12. Brian R: Thyroid autoimmunity. *Current Opinions in Immunology* 4(6): 770-778, 1982.
13. Kohno Y: Antithyroid peroxidase antibodies in sera from patients with chronic thyroid peroxidase antibodies in sera. *Clinical Experimental Immunology* 85: 459-463, 1991.
14. Ludgate S: Antibodies to human thyroid peroxidase in autoimmune thyroid disease. *J Clin Endocrinol Metab* 68: 1091, 1989.
15. Khoury EL: The thyroid microsomal antibody revisited: its paradoxical binding to the apical surface of the follicular epithelium. *J Exp Med* 159: 577, 1984.
16. Libert J: Complete nucleotide sequence of the human thyroperoxidase microsomal antigen cDNA. *Nucleic Acids Res* 15: 6735, 1987.
17. Faryna M: Measurement of autoantibodies against human eye muscle plasma membrane in Graves' ophthalmopathy. *Br Med J* 290: 191, 1985.
18. Kodoma K: Demonstration of circulating autoantibodies against a soluble eye muscle antigen in Graves' ophthalmopathy. *Lancet* 36: 1353, 1989.
19. Wiersinga WM: Temporal relationship between onset of Graves' ophthalmopathy and onset of thyroidal Graves' disease. *J Endocrinol Invest* 11(8): 615, 1988.
20. Tamai H: The mechanism of spontaneous hypothyroidism in patients with Graves' disease after antithyroid drug treatment. *J Clin Endocrinol Metab* 69: 49-53, 1989.
21. Kendal-Taylor P: The pathogenesis of Graves' ophthalmopathy. *Clin End Metab* 14(2): 331-349, 1985.
22. Dessaint JP: Antibody-dependent lymphocyte cytotoxicity (ADCC) and lymphocyte-mediated cytotoxicity in autoimmune thyroid diseases. *Pathol Biol* 29: 211-5, 1981.
23. Wasserman J: Antibody-induced *in vitro* lymphocyte cytotoxicity in Hashimoto thyroiditis. *Int Arch Allergy* 47: 473-82, 1974.
24. Khoury EL: Presence of the organ specific "microsomal" autoantigen on the surface of human thyroid cells in culture. *Clin Exp Immunol* 45: 316-28, 1981.
25. Bogner U: Antibody-dependent cell-mediated cytotoxicity against human thyroid cells in Hashimoto's thyroiditis but not Graves' disease. *J Clin Endocrinol Metab* 59: 734-8, 1984.
26. Hamada N: Antibodies against denatured and reduced thyroid microsomal antigen in autoimmune thyroid disease. *J Clin Endocrinol Metab* 64: 230-8, 1987.
27. Weetman AP: The relationship of HLA-DR3 and outcome after antithyroid drugs to the IgG subclass distribution of thyroid autoantibodies in Graves' disease. *Acta Endocrinol* 114(2): 293-297, 1987.
28. Takaiehi Y: The significance of antithyroglobulin and antithyroidal microsomal antibodies in patients with hyperthyroidism due to Graves' disease treated with antithyroidal drugs. *J Clin Endocrinol Metab* 68(6): 1097-1100, 1989.
29. Szabo J: Detectability of antimicrosomal antibodies. *Medical Hungary* 49: 23-30, 1989.
30. Lopez JM: Autoimmune thyroid disease in puerperium: predictive value of thyroid enlargement and related hormonal changes occurring during pregnancy. *J Endocrin Invest* 13(4): 250, 1990.
31. Hamada N: Retrospective re-evaluation of the significance of microsomal antibody in the treatment of Graves' disease. *Acta Endocrinol* 114(3): 328-335, 1987.
32. Jordan SC: Studies of immune complex glomerulonephritis mediated by human thyroglobulin. *New Eng J Med* 304(20): 1212-15, 1981.