

TRANSITIONAL CELL CARCINOMA OF THE BLADDER IN A 17 YEAR OLD MALE

ALI SHAMSA, M.D.

*From the Department of Urology, Ghaem Hospital, Mashhad University of Medical Sciences, Mashhad,
Islamic Republic of Iran.*

ABSTRACT

Epithelial tumors are rarely seen during the first two decades of life. We report a 17 year old male with primary transitional cell carcinoma (TCC) of the bladder. *MJIRI, Vol. 8, No. 1, 57-58, 1994.*

CASE REPORT

A 17 year old student from Sabzevar referred to us with a history of gross, painless hematuria for the last two weeks. He had had another episode of hematuria 2 years back, but his first cystoscopy and bladder biopsy were negative at that time.

In his IVP and bladder ultrasonography, there was a filling defect and papillary lesion in the bladder (Figs. 1,2). His cystoscopy showed a papillary lesion about 3 × 3 cm in diameter in the left lateral bladder wall far from the left ureteral orifice. Transurethral resection of bladder tumor

was done successfully. His bladder sonography was repeated after one week (Fig. 3) and showed no residual tumor.

The histopathological report proved it to be a TCC-GI, stage 0.

DISCUSSION

Transitional cell carcinoma of the bladder is very rare before 20 years of age. It has been reported in approximately 100 cases since 1950.¹

Javadpour and Mostofi reported 28 cases of TCC who were younger than 20 years of age from 100,000 cases of bladder TCC.

Since 1989, 30 cases of bladder TCC in adolescents have been reported in Japan² and 125 cases in the world.³

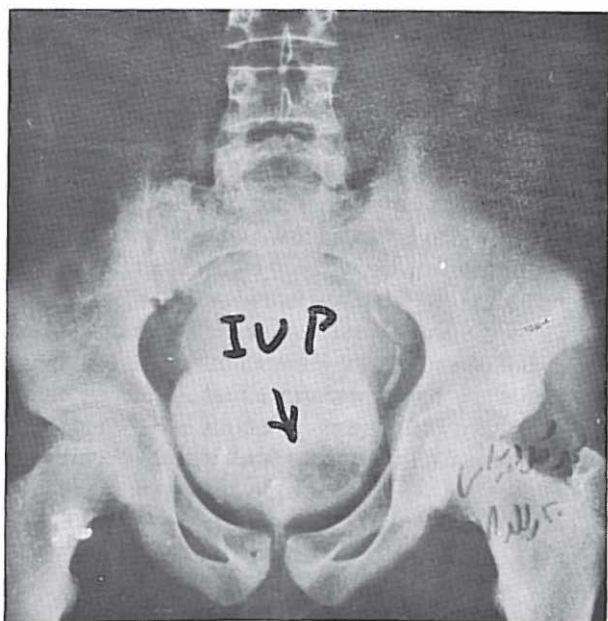


Fig. 1. IVP cystogram showing filling defect.

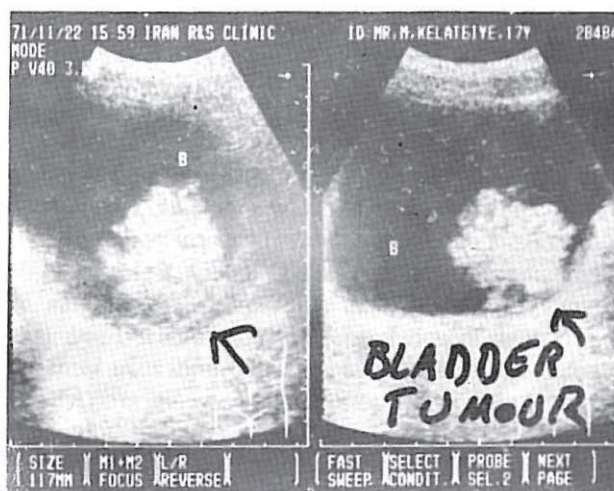


Fig. 2. Bladder sonography demonstrating tumor.

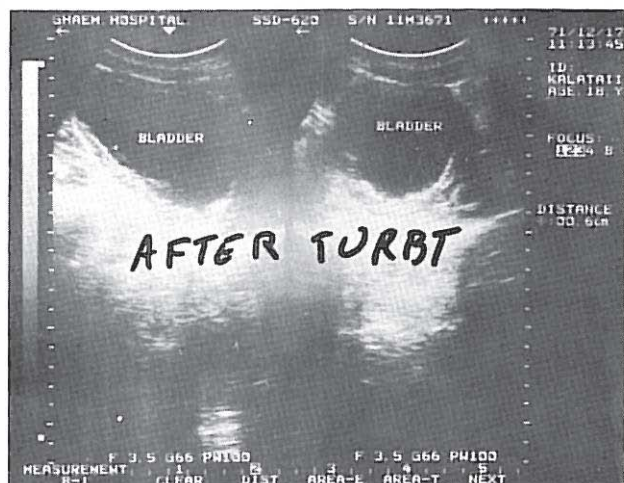

Fig. 3. Postoperative sonogram.

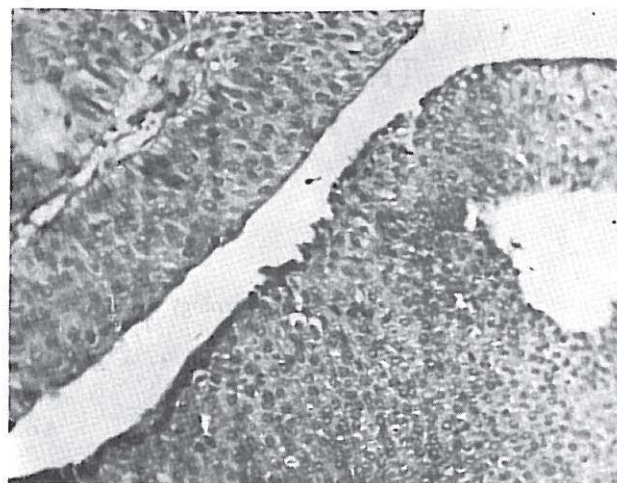


Fig. 4. Grade I Transitional Cell Carcinoma of the bladder in 17 years old man

It is very important to emphasise that TCC among children is a single papillary lesion³ like our case. These tumors tend to be of low grade and low stage.¹ Our case was bladder TCC-GI, stage 0.

Although these tumors do not tend to recur and have a favourable prognosis,⁴ (unlike TCC in the elderly) periodic urinalysis and bladder ultrasound is advised.

REFERENCES

1. Khasidy LR, Khashu B, Mallett EC, Kaplan GW, Brock WA: Transitional cell carcinoma of bladder in children. *Urology* 35(2): 142-144, 1990.
2. Kim CJ, Takeuchi H, Tomoyoshi T, Nishio T: Transitional cell carcinoma of the urinary bladder in adolescence. *Hinyokika-Kyo* 35(2): 337-341, 1989.
3. Scott AA, Stanley W, Worsham GF, Kirkland TA, Gansier T, Garvin AJ: Aggressive bladder carcinoma in an adolescent. *Am Surg Pathology* 13(12): 1057-1063, 1989.
4. Witjes JA, Debruyne FM: Bladder carcinoma in patients less than 40 years of age. *Urol Int* 44(2): 81-83, 1989.