

## Original Articles

### A STUDY OF 765 CASES OF CLINICALLY SOLITARY COLD THYROID NODULES FROM AN IODINE- DEFICIENT AREA

MANOOCHHR NAKHJAVANI, MOHAMMAD HASAN  
BASTANHAGH, REZA KASSAYAN, RADINA ESHTIAGHI, AFSAR  
ASADI, AND MOHAMMAD RAJAI



*From the Department of Internal Medicine, Division of Endocrinology and Metabolism, Tehran University  
of Medical Sciences,*

#### ABSTRACT

We studied the clinical, radioisotopic, and pathologic characteristics and the incidence of cancer in clinically solitary cold nodules of the thyroid in an iodine-deficient area. The study included retrospective analysis of 765 patients who underwent thyroidectomy for a clinically single cold nodule in a ten-year period. We compared the pathological findings with clinical data. In pathological examination, 34% of glands were multinodular. The incidence of nodular colloid goiters were 81.7% and of thyroid cancer 10.2%. Thyroid malignancy increased significantly after age thirty ( $p < 0.005$ ). The incidence of cancer was 8.3% in true solitary nodules versus 13.8% in clinically solitary nodules found to be pathologically multinodular ( $p < 0.05$ ). Papillary carcinoma was the most frequent type (70.5%) and medullary carcinoma the least frequent type (2.6%). Benign nodular lesions were the most common cause of cold nodules. There was no sex difference in the incidence of thyroid cancer. In the patients with thyroid carcinoma the percentage of multinodular glands was higher. Iodine deficiency may be a factor in changing certain characteristics of thyroid nodules.

*MJIRI, Vol. 7, No. 3, 145-150, 1993.*

#### INTRODUCTION

Terms such as "solitary cold nodule" or clinically dominant nodule commonly signify that a nodule is more apt to be a neoplasm, whereas multiple nodules are likely to represent benign colloid nodular goiter.<sup>1,2</sup>

Correspondence to: Dr. Manoochehr Nakhjavani, Endocrine Ward, Vali-Asr Hospital, Imam Khomeini Medical Center, Keshavarz Blvd., Tehran, Iran

In this study we report the clinical, radioisotopic, and histologic characteristics of clinically solitary cold nodules in an iodine-deficient area. The incidence of thyroid cancer in 765 patients seen in a 10-year period is also reported.

#### PATIENTS AND METHODS

A consecutive series of 765 patients undergoing thyroidectomy for a clinically single cold nodule from

## Cold Thyroid Nodules in Iodine-Deficient Area

1979-1989 was studied. The patients were mostly from Tehran and its suburbs and other provinces of Iran. The analysis of drinking water has shown that the endemic goiter as it occurs in Iran is usually due to inadequate supply of iodine.<sup>3</sup> There had been no attempt to correct iodine deficiency before this study. The goiter prevalence in school children is estimated to be at least 17.5%.<sup>4</sup> The age range was from nine to seventy-six years. Seventy-eight percent of patients were female.

Nodules were identified as solitary on clinical examination and on thyroid scan with [<sup>99m</sup>Tc] - pertechnetate. The reasons for thyroid surgery included: presence of a cold nodule, 90.5%; a cellular lesion on fine needle aspiration, 6.1%; continued nodule growth despite suppressive l-thyroxine therapy, 1.3% and patient request, 2.1%. Patients with a history of radiation to head and neck were excluded.

Based on the gross pathological findings a thyroid gland was considered to have a single nodule if only one nodule was present. A multinodular gland was one with two or more separate macroscopic nodules. The histopathological findings were determined by a pathologist. We used Pearson chi-square test for statistical analysis.

### RESULTS

The chief complaint of the patients was: neck swelling, 64.9%; recent growth, 22.9%; pressure feeling in the neck, 6%; dysphagia, 3.1%; and neck pain, 3.1%. The most frequent nodule location was in the right lower lobe and the least frequent site in the left upper lobe. The incidence of malignancy was 19.2% at the upper poles of thyroid lobes and 7.1% at the remaining sites. The age and sex distribution of the patients are outlined in Fig. 1. 334 (43.7%) were between 9-30 years of age and 431 (56.3%) between ages 31-76.

34 percent of patients with a clinically apparent solitary nodule were found to have additional nodule(s) on pathological examination. The results of the analysis of 765 patients, 504 cases with solitary nodules and 261 with more than one nodule, are outlined in Figs. 2 and 3. 625 (81.7%) had nodular colloid goiters, 78 (10.2%) thyroid carcinoma, 50 (6.5%) thyroid adenoma, and 12 (1.5%) other lesions such as granulomatous reaction or lymphocytic thyroiditis. The incidence of thyroid carcinoma was 6.6% for patients younger than thirty years of age; it was 13.3% after this age. This difference was statistically significant ( $p < 0.005$ ). The age distribution of patients with carcinoma is outlined in Table I. The comparison of incidence for various types of thyroid carcinoma in male and female patients are outlined in Table II. There was no difference in the incidence of carcinoma between both sexes. The

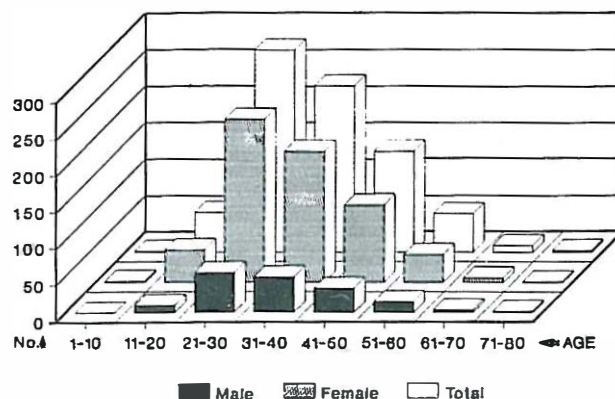


Fig. 1. The age and sex distribution of 765 patients with a solitary cold nodule of the thyroid.

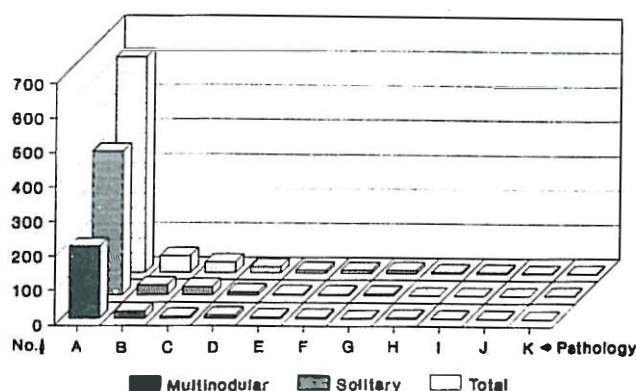


Fig. 2. The various pathologic entities comprising 765 cases of solitary cold nodule of the thyroid:

- A: Nodular Colloid Goiter
- B: Papillary Carcinoma
- C: Follicular Adenoma
- D: Papillary Adenoma
- E: Fetal Adenoma
- F: Lymphocytic Thyroiditis
- G: Anaplastic Carcinoma
- H: Granulomatous Reaction
- I: Medullary Carcinoma
- J: Embryonal Adenoma

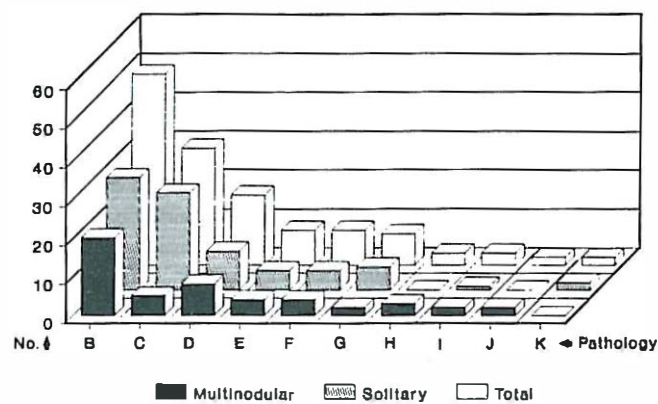


Fig. 3. Demonstration of Fig. 2 after exclusion of nodular colloid goiter.

Table I. The age distribution of patients with thyroid carcinoma

Age Group		9-20	21-30	31-40	41-50	51-60	61-70	70-76
Patients	No.	57	277	266	139	53	10	3
Malignancy	No.	4	18	29	14	8	3	2
Malignancy	%	7	6.5	12.8	10.1	15.1	30	66

Table II. Comparison of the incidence of various types of thyroid carcinoma in male and female

Total	No. & Percent of Carcinoma	Mixed Papillary & Follicular Ca.	Follicular & Hurthle Cell Ca	Medullary Ca.	Anaplastic Ca.
Female	599	61(10.2%)	45(73.8%)	14(23.0%)	2(3.3%)
Male	166	17(10.2%)	10(59.0%)	4(23.6%)	0
Total	765	78(10.2%)	55(70.5%)	18(23.1%)	2(2.6%)



mean age at diagnosis of malignancy was  $46.4 \pm 14.9$  years in males and  $36.9 \pm 11.3$  years in females. Moreover, 8.3% of patients with true solitary nodules had thyroid carcinoma versus 13.8% in multinodular goiters ( $p < 0.05$ ). 36 out of 78 cases (46.2%) of thyroid carcinoma were multinodular in pathological examination. There were 24 (66.6%) cases of multicentric carcinoma and 12 (33.3%) nodular colloid goiter plus a focus of carcinoma.

Papillary carcinoma was the most frequent type (70.5%) of cancer and comprised 75% of multicentric lesions. Medullary carcinoma was the least frequent type of cancer (2.6%). The incidence of follicular carcinoma was 15.4%, increasing to 23.1% if Hurthle cell tumors were included. 17.5% of thyroid cancers in males were due to anaplastic carcinoma. Two of the four patients with cervical lymphadenopathy had papillary carcinoma and another two had nodular colloid goiters.

The female to male ratio was 3.6: 1, which decreased from 4.2: 1 before age 30 to 3.2:1 after this age. Of 22 patients with thyroid carcinoma below the age 30 only one was male. Of 56 patients over 30 years old with thyroid cancer, 40 were female and 16 were male.

84 patients underwent surgery based on the results of the needle aspiration of the cold nodule. Four of the 55 patients with a report of a benign lesion proved to have a malignant lesion. 10 of 29 (34.5%) patients with a cellular lesion on fine needle aspiration had thyroid malignancy on pathological examination.

The mean age of patients with colloid nodular goiters was  $34 \pm 11$  years and showed no difference in both sexes. The frequency of nodular colloid goiters decreased after age 60.

The mean age for adenomas was  $34 \pm 11$  years with no

difference in male and female. The most frequent type of adenoma was follicular type (60%). The incidence of fetal and papillary adenoma each was 18 percent. Two patients had embryonal adenomas and both patients were 23 years old.

## DISCUSSION

Palpation of the thyroid nodules is highly subjective. Its sensitivity in detecting nodules is reported to be 38-40%.<sup>5,6</sup> In this study, 34 percent of thyroid glands with clinically solitary nodules had additional nodules on pathological examination.

The incidence of thyroid nodules has ranged from 4% to 7% in clinical studies as reported from iodine sufficient areas.<sup>6,7,8</sup> Nodular goiter is more common in persons living in areas of iodine deficiency.<sup>9,10</sup> Cold thyroid nodules have been estimated to be 2.5 times more frequent in iodine deficient areas in comparison with the iodine sufficient areas.<sup>11</sup>

Available reports about the pathological nature of thyroid nodules varies. Taylor studied 189 patients with clinically solitary cold thyroid nodules with cutting needle biopsy.<sup>12</sup> The incidence of adenomas was 87.5% and carcinomas 80%. Yao studied needle biopsies of 906 patients with thyroid nodules done at Massachusetts General Hospital between 1952-1973.<sup>13</sup> He found 42.8% to be various types of thyroiditis, 30.3% adenomas, 4.4% carcinomas, and 8.6% nodular colloid goiters. Veith et al. studied 503 patients selected for thyroidectomy because of some degree of nodularity of the thyroid.<sup>14</sup> The pathological distribution of the nodules was as follows: adenomatous goiter 60%,

true adenomas 26%, carcinomas 9% and thyroiditis 5%. Solitary cold nodules have long been considered more likely to be malignant than multinodular goiters.<sup>1,2</sup> Multinodularity in goiter may be defined by clinical, pathological, and ultrasonographic examination. Older series suggest that the cancer prevalence in clinically multinodular goiters is one fourth to half that in solitary nodules.<sup>3</sup> However in later series the prevalence of malignancy in solitary nodules does not seem to differ significantly from multinodular goiters.<sup>12,14,15,16</sup> McCull et al.<sup>16</sup> found no significant difference in the frequency of carcinoma between patients with a true solitary cold nodule and those with clinically evident multinodular goiters. In Veith's study<sup>4</sup> the incidence of malignancy in multinodular glands was 13.3% versus 6.6% in uninodular glands. He attributed the higher incidence of cancer in thyroid glands that were multinodular to the policy of not operating on all multinodular thyroid glands. Also, in Veith's study multinodularity was significant in malignant tumors. Taylor's study included 207 patients with clinically solitary thyroid nodules. On pathological examination 108 cases had true solitary nodules and 99 multinodular goiters. The incidence of malignancy was 12.9% and 12.1%, respectively. The significance of multinodularity in pathologic examination may be different from that in clinical examination. As many as 40 per cent of patients with clinically apparent solitary nodules have multiple nodules as visualized by ultrasound.<sup>17</sup> High-resolution ultrasonography with real-time capability visualizes nodules with great detail and may detect lesions as small as 1 mm.<sup>17</sup> It is not known whether ultrasonographically-determined multinodular glands are associated with the same low risk of malignant disease as clinically apparent multinodular goiters.<sup>6</sup> The present study confirms the increased risk of malignancy in glands with clinically solitary nodules found multinodular in pathologic examination. Either a multicentric carcinoma or a nodular colloid goiter with a focus of carcinoma may explain multinodularity in thyroid malignancy. The mechanism of the carcinogenic stimulus in the area of iodine deficiency is unknown. The possibility that iodine deficiency is a risk factor for thyroid cancer, particularly for the follicular and anaplastic types, has been suggested for a long time.<sup>11,18</sup> TSH is a known cell growth factor,<sup>19</sup> and certain animal and human thyroid tumors are TSH dependent.<sup>20,21</sup> Thyroid growth response to exogenous TSH in the hypophysectomized rat is greater in iodine-deficient than in iodine-replete rats.<sup>22</sup> Iodine inhibits the growth proliferative effect of TSH in thyroid cells in culture.<sup>23</sup> Excessive growth stimulation leads to an increased chance of development of nodules and adenomas.<sup>24</sup> It seems that the anatomical changes in the thyroid are exaggerated by prolonged stimulation of iodine deficiency.

The role of age as a risk factor for thyroid carcinoma is

questionable.<sup>25-27</sup> The incidence of carcinoma in children in series studied in the past has ranged from 14 to 40%.<sup>28-30</sup> In two series that deliberately excluded children who had been exposed to radiation, the incidence of cancer in thyroid nodules was approximately 15 percent and the predominant lesion was a follicular adenoma.<sup>31,32</sup> Elderly patients have a high incidence of benign nodular disease,<sup>6,8,33-35</sup> but the incidence of thyroid carcinoma does not decline with age.<sup>6</sup>

Undifferentiated carcinomas occur more commonly in elderly patients,<sup>36</sup> and the rate of mortality from thyroid cancer is higher in elderly patients even when undifferentiated cancers are excluded.<sup>37</sup> The prevalence of occult thyroid cancer has been reported to increase with age,<sup>38</sup> and with exposure to radiation.<sup>39</sup> We found an increase in the incidence of carcinoma after age 30. We also found no sex difference in the incidence of carcinoma. Regional differences in the prevalence of cancer unrelated to the prevalence of goiter have been reported.<sup>40</sup>

In 1940s when essentially all solitary nodules were excised the cancer incidence was 4.5%. This rate increased to 25% to 35% in 1970s when selection of the nodules for surgery was based on thyroid scans, clinical suspicion, and response to thyroid suppression.<sup>25,41</sup> In this study the incidence of carcinoma was lower (7.4%), if the primary indication for thyroid surgery was to rule out cancer in a solitary cold nodule.

Thyroid hormone suppression therapy is not a reliable method for distinguishing benign from malignant thyroid nodules.<sup>42-46</sup> Fine needle aspiration (FNA) biopsy has emerged as the best initial diagnostic step for the evaluation of the nodular thyroid.<sup>6,47,49</sup> The ability of fine needle aspiration biopsy to predict malignancy in a thyroid nodule is reported to be two to four times greater than that of other methods.<sup>50,51</sup> The rate of cancer diagnosis increased from 7.4% by thyroid scan to 16.6% by FNA cytology in this study.

Substitution of the term predominant cold nodule for single cold nodule seems appropriate. The initial diagnostic step can be chosen based upon patient and physician preference, expertise in and availability of the procedure and general clinical assessment.<sup>52</sup>

### ACKNOWLEDGEMENTS

The authors express appreciation to Dr. Hossein Gharib for his review of the manuscript.

### REFERENCES

1. Anglem TJ, Bradford ML: Nodular goiter and thyroid cancer. *N Engl J Med* 239: 217-20, 1948.

2. Cole WH, Majarakis JD, Slaughter DP: Incidence of carcinoma of the thyroid gland in nodular goiter. *J Clin Endocrinol Metab* 9: 1007-11, 1949.
3. Emami A, Shahbazi H, Sabzevari M, Gavam Z, Sarkissian N, Hamed P, et al: Goiter in Iran. *Am J Clin Nutr* 22: 1584-8, 1969.
4. Bastani SJ: Endemic goiter in Iran. In: Dunn JT, Pretell EA, Daza CH, Viteri FE, (eds). *Towards the Eradication of Endemic Goiter, Cretinism, and Iodine Deficiency*. Washington DC: Pan American Health Organization Scientific Publication, 357, 1986.
5. Christensen SB, Tibbilen S: The reliability of the clinical examination of the thyroid gland. *Acta Chirurg Gynecol*; 74: 151-4, 1985.
6. Rojeski MT, Gharib H: Nodular thyroid disease: evaluation and management. *N Engl J Med* 313: 428-36, 1985.
7. Stoffer RP, Welch JW, Helwing CA, Chesky VE, McCusker EN: Nodular goiter: incidence, morphology before and after iodine prophylaxis, and clinical diagnosis. *Arch Intern Med* 106: 10-4, 1960.
8. Vander JB, Gaston EA, Dawber TR: The significance of non-toxic thyroid nodules: final report of a 15-year study of the incidence of thyroid malignancy. *Ann Intern Med* 68: 537-40, 1968.
9. Bray GA: Increased sensitivity of the thyroid in iodine-depleted rats to the goitrogenic effects of thyrotropin. *Clin Invest* 47: 1640-7, 1968.
10. Vigneri R: Studies on the goiter endemia in Sicily. *Endocrin Invest* 11: 831-43, 1988.
11. Belfiore A, La Rosa GL, Ippolite O, Padova G, Sava L, Vigneri R: Frequency of cold thyroid nodules and thyroid malignancies in subjects from an iodine deficient area. *Cancer* 60: 3096-102, 1987.
12. Taylor S: Sporadic nontoxic goiter: etiology and pathogenesis. In: Wener SC, Ingbar SH, (eds). *The Thyroid*. Maryland: Harper & Row, 501-11, 1978.
13. Yao Y: Thyroid nodules benign or malignant: 1. Diagnosis 2. Management. *Postgraduate Medicine* 61: 65-85, 1975.
14. Veith FJ, Brooks JR, Grisby WP, Selenkow HA: The nodular thyroid gland and cancer: a practical approach to the problem. *N Eng Med* 270: 431-5, 1964.
15. Cerise EJ, Randall S, Ochsner A: Carcinoma of the thyroid and non-toxic nodular goiter. *Surgery* 31: 552-61, 1952.
16. McCall A, Jarosz H, Lawrence AM, Playton E: The incidence of thyroid carcinoma in solitary cold nodules and in multinodular goiters. *Surgery* 100: 1128-32, 1986.
17. Scheible W, Leopard GR, Woo VL, Gosink BB: High resolution real-time ultrasonography of thyroid nodules. *Radiology*, 133: 413-7, 1979.
18. Konig MP, Ruchi CH, Studer H, Berchtold R, Rosler H: Thyroid cancer in regions of endemic goiter. In: Andreoli M, Monaco F, Robbins J (ed.). *Advances in Thyroid Neoplasia*. Rome: Field Educational Italia, 177-87, 1981.
19. Wollman SH, Breitman TR: Changes in DNA and weight of thyroid glands during hyperplasia and involution. *Endocrinology* 86: 322-7, 1970.
20. Nadler NJ, Mandavia M, Goldberg M: The effect of hypophysectomy on the experimental production of rat thyroid neoplasia. *Cancer* 30: 1909-11, 1970.
21. Clark OH, Castner BJ: Thyrotropin receptors in normal and neoplastic human thyroid tissue. *Surgery* 85: 624-32, 1979.
22. Bray GA: Increased sensitivity of the thyroid in iodine-depleted rats to the goitrogenic effects of thyrotropin. *J Clin Invest* 47: 1640-7, 1968.
23. Becks GP, Egge MC, Burrow GN: Organic iodine inhibits the deoxyribonucleic acid synthesis and growth in FRTL-5 thyroid cells. *Endocrinology* 123: 545-51, 1986.
24. Thomas GA, Williams ED: Aetiology of simple goiter. *Bailliere's Clin Endocrin Metab* 3: 703-18, 1988.
25. Thomas CG, Buckwalter JA, Staab EV: Evaluation of dominant thyroid masses. *Ann Surg* 183: 463-9, 1976.
26. Messaris G, Evangelu GN, Tountas C: Incidence of carcinoma in cold nodules of the thyroid gland. *Surgery* 74: 447-8, 1973.
27. Hoffman GL, Thompson NW, Heffron C: The solitary thyroid nodule: a reassessment. *Arch Surg* 105: 379-85, 1979.
28. Kirkland L, Clayton GW: Solitary thyroid nodules in thirty children and report of a child with a thyroid abscess. *Pediatrics* 51: 85-90, 1973.
29. Hopwood NJ, Carroll RG, Kenny FM, Foley TP: Functioning thyroid masses in childhood and adolescence: clinical, surgical, and pathologic correlations. *J Pediatr* 89: 710-8, 1979.
30. Scott MD, Crawford JD: Solitary thyroid nodules in childhood: is the incidence of thyroid carcinoma declining? *Pediatrics* 58: 521-5, 1979.
31. Silverman SH, Nussbaum M, Rausen AR: Thyroid nodules in children: a ten-year experience at one institution. *Mount Sinai J Med* 46: 460-3, 1979.
32. Hung W, August GP, Randolph JG, Schisgall RM, Chandra R: Solitary thyroid nodules in children and adolescence. *J Pediatr Surg* 17: 225-9, 1982.
33. Mortensen JD, Woolner LB, Bennett WA: Gross and microscopic findings in clinically normal thyroid glands. *J Clin Endocrin Metab* 15: 1270-80, 1955.
34. Tunbridge WMG, Evered DC, Hall R, et al. The spectrum of thyroid disease in a community: the *Whickham survey*. *Clin Endocrin (Oxford)* 7: 481-93, 1977.
35. Ashcraft MW, Herle AJ: Management of thyroid nodules. I. History and physical examination, blood tests, and ultrasonography. *Head Neck Surg* 3: 216-27, 1981.
36. Thomas CG, Buckwalter JA: Poorly differentiated neoplasm of the thyroid gland. *Ann Surg* 177: 632-42, 1973a.
37. Rawson RW, Leeper R: Factors influencing benignancy versus malignancy of thyroid neoplasms. In: Young S, Inman DR, (eds). *Thyroid Neoplasia*. New York: Academic Press, 159-77, 1968.
38. Hanson GA, Komorowski RA, Cerletty JM, Wilson SD: Thyroid gland morphology in young adults: normal subjects versus those with prior low dose neck irradiation in childhood. *Surgery* 94: 984-8, 1983.
39. Sampson RJ: Prevalence and significance of occult thyroid cancer, In: DeGroot LJ, Forham LA, Kaplan EL, Refetoff S (eds). *Radiation-Associated Thyroid Carcinoma*. New York: Grune & Stratton, 137-53, 1977.
40. Konig MP, Ruchi CH, Studer H, Berchtold R, Rosler H: Thyroid cancer in regions of endemic goiter. In: Andreoli M, Monaco F, Robbins J, (eds). *Advances in Thyroid Neoplasia*.

## Cold Thyroid Nodules in Iodine -Deficient Area

- Rome: Field Educational Italia, 177-87, 1981.
41. Hill I: Thyroid suppression. *Arch Surg* 108: 403-5, 1974.
  42. Balme HW: Metastatic carcinoma of the thyroid successfully treated with thyroxine. *Lancet* 1: 812-3, 1954.
  43. Staunton MD, Greening WP: Treatment of thyroid cancer in 293 patients. *Br J Surg* 63: 253-8, 1979.
  44. Blum M, Rothschild M: Improved non-operative diagnosis of the solitary "cold" thyroid nodule: surgical selection based on risk factors and three months of suppression. *J Am Med Assoc* 243: 242-5, 198.
  45. Gharib H, James EM, Charboneau JW, Naessens JM, Offord KP, Gorman CA: Suppressive therapy with levothyroxine for solitary thyroid nodules. A double-blind controlled clinical study. *N Eng J Med* 317: 70-5, 1987.
  46. Smith SA, Gharib H: Thyroid nodule suppression. In: Mazzaferri EL, Bar RS, Kreisberg RA, (eds). *Advances in Endocrinology and Metabolism*. St. Louis: Mosby-Year Book, 107-24, 1991.
  47. Norton LW, Wangenstein SL, Davis JR, Paplanus SH, Werner SC: Utility of thyroid aspiration biopsy. *Surgery* 92: 700-5, 1982.
  48. Kendall CH: Fine needle aspiration of thyroid nodules: three year's experience. *J Clin Path* 42: 23-7, 1989.
  49. Pepper JM, Zwickler D, Rosen Y: Fine needle aspiration biopsy of the thyroid nodule. *Arch Intern Med* 149: 594-99, 1989.
  50. Hamburger JI, Hamburger SW: Fine-needle biopsy of thyroid nodules: avoiding the pitfalls. *New York State Journal of Medicine* 86: 241-9, 1986.
  51. Koher HD, Goretzki PE. Management of goiter and thyroid nodules in an area of endemic goiter. *Surg Clin N Amer* 67: 233-49, 1987.
  52. Ross DS: Evaluation of the thyroid nodule. *J Nucl Med* 32: 2181-92, 1991.