

## DENTAL CAVITY MYIASIS DUE TO *WOHLFAHRTIA* *MAGNIFICA*

AMID ATHARI AND TEIMUR FALLAH

*From the Department of Microbiology, School of Medicine, Kermanshah University of Medical Sciences,  
Kermanshah, Islamic Republic of Iran.*

### ABSTRACT

A 79 year old farmer referred to a dental clinic because of toothache for one week. After extraction of a painful tooth, three larvae, 1.5 cm in length emerged from the dental cavity. Morphological study of the larvae proved them as *W. magnifica*. This is the first report of dental cavity myiasis from Iran.

*MJIRI, Vol. 7, No. 3, 209-210, 1993.*

**Key words:** *Wohlfahrtia magnifica*; dental cavity, myiasis

### INTRODUCTION

Human and animal tissue infestation by eggs or larvae of some non-sucker flies (*Cyclorrhapha*) have been frequently observed in poor sanitary areas and cause a pathogenic condition known as myiasis.<sup>1</sup> Dental cavity myiasis is less common and conservative management by removal of dead maggots could be an effective method for treatment.

### CASE REPORT

A 79 year old farmer residing in a village near Kermanshah city (west province of Iran) was admitted to

a health center because of toothache with a history of dizziness, headache and drowsiness for one week. He had only four teeth in his oral cavity, with necrotic gingival tissue. After extraction of a painful second premolar tooth, three larvae 1.5 cm in length were removed from his cavity (Fig. 1). The X-ray showed opacity of right maxillary

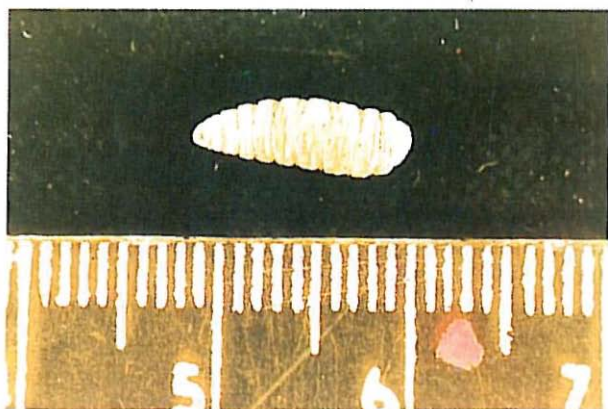


Fig. 1. One of the three *W. magnifica* larvae extracted from the dental cavity.

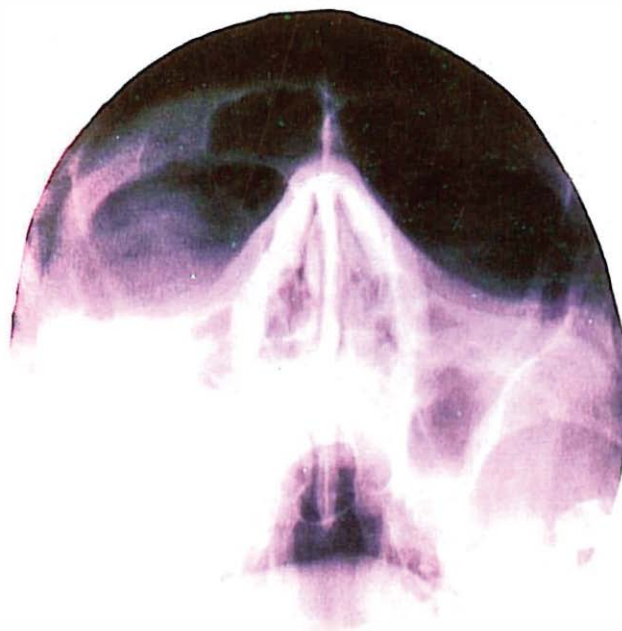


Fig. 2. X-ray shows opacity of right maxillary sinus and hypertrophy of left sinus mucosa.

## Dental Cavity Myiasis

sinus and hypertrophy of left sinus mucosa (Fig. 2). Haematological examinations were normal. The patient made a good recovery three days after operation. Entomological study of the larvae and observation of typical anterior and posterior spiracles revealed them as third-instar larvae of *W. magnifica*.

### DISCUSSION

Myiasis is a subject of medical and veterinary importance.<sup>2</sup> In human cases, skin wounds, ear, eye and nasal cavity are the commonest affected areas.<sup>3</sup> *W. magnifica* larvae, the causative agent in our case, are obligatory parasites in warm-blooded vertebrates and in contrast to Sarcophaga species, never develop in carcasses.<sup>2</sup> In recent years this agent has been reported as the cause of otitis media and aural myiasis in Egypt<sup>4</sup> and ophthalmomyiasis.<sup>5</sup> In Iran, *W. magnifica* has been frequently known as one of the most important myiasis-producing flies in animals<sup>6</sup> and also one case of gingival myiasis due to this agent has been reported.<sup>7</sup> In our case, the patient's house was nearby a sewage terminal and during the summer there were a large number of insects around the area. It is probable that the larvae were deposited on the necrotic periodontal tissues when he was asleep with an open mouth (because of sinusitis) and they migrated into the dental cavity. Due to

rapid growth of *W. magnifica* larvae and their large size, treatment should be directed toward prompt removal of the fly maggot by means of incision and extraction.

### ACKNOWLEDGEMENT

The author would like to express his thanks to Dr. B. Janbakhsh and Dr. S. Targari for valuable advice.

### REFERENCES

1. Portschnisky IA: *Wohlfahrtia magnifica* and allied Russian species. *Bull Entomol Sci Com Agr Men* 11(9): 108-115, 1961.
2. Zumpt F: Myiasis in man and animals in the world. London: Butterworths, 267-268, 1983.
3. Manson-Bahr PEC, Bell DR: *Manson's Tropical Diseases*. London: Bailliere and Tindall, 913-918, 1989.
4. Fawzy AF: Otitis media and aural myiasis. *J Egypt Soc Parasitol* 21: 883-885, 1991.
5. Morsy TA, Farrag AM: Two cases of human ophthalmomyiasis. *J Egypt Soc Parasitol* 21: 853-855, 1991.
6. Janbakhsh B, Targari SH, Aghamohamadi A: Myiasis in Iranian sheep. *Iranian Entomol Soc Let* 3: 8-12, 1975.
7. Sahba GH: A case of gingival myiasis in man and animals in Iran. Presented in III International Congress for Tropical Medicine and Malaria, Canada, 1981.