

ELLIS-VAN CREVELD SYNDROME: REPORT OF A CASE IN AN ADULT PATIENT

*ALI ANDON PETROSSIANS, M.D. AND
** MAJID MALEKI, M.D.

*From the Cardiovascular Research Center, Shahid Rajaii Heart Hospital, Tehran,
Islamic Republic of Iran.*

ABSTRACT

Ellis-van Creveld syndrome is transmitted as an autosomal recessive trait. This syndrome is accompanied in 60% of cases with congenital heart disease, mostly single atrium or large ASD. Patients are mostly symptomatic, but in this rare case despite 68 years of age, the patient was free of symptoms except for complete heart block for which pacemaker was inserted.

MJIRI, Vol. 7, No.1, 59-60, 1993.

Keywords: Ellis-van Creveld syndrome, Single atrium, Autosomal recessive trait

INTRODUCTION

A 68-year-old male referred with the chief complaint of dyspnea and palpitation for three years, becoming aggravated in the last three months. Physical examination revealed polydactyly and a holosystolic murmur at the left sternal border.

Echocardiography showed a single atrium, in accordance with the diagnosis of Ellis-van Creveld syndrome. We found no previous report this syndrome in old age.

CASE REPORT

A 68-year-old male complained of dyspnea on effort and palpitation. His condition had gradually worsened and he referred to the out-patient clinic for further evaluation.

On referral, physical examination showed a cachectic patient with a heart rate of 45/min and blood pressure 120/80 mm Hg. Wheezing was present in both lungs. A grade III/VI holosystolic murmur was heard at the 4th left intercostal space, radiating to the apex.

The liver was palpable 3 cm below the right costal

margin. Extremities were short and there were six digits in each hand (Fig. 1) and the patient's height was 125 cm. Nails were hypoplastic, mouth was normal.

Electrocardiography revealed complete heart block with narrow QRS and escape rhythm for which a pacemaker was inserted.

Chest X-ray showed enlargement of the heart (cardiothoracic ratio 61%) and increased pulmonary blood flow in both right and left lungs (Fig. 2), and the pulmonary knob was prominent. X-ray of hands showed a sixth digit with the same bony configuration as the fifth digit, and metacarpal fusion of the two (Fig. 3). Two-dimensional echocardiography showed a single atrium (Fig. 4). Colour doppler echocardiography revealed mild mitral valve regurgitation, being mixed in the single chamber.

Diagnosis of Ellis-van Creveld syndrome was given. Treatment was started with digoxin and diuretics and because the patient was old and not in satisfactory mental condition, we did not suggest further cardiac catheterization and only out-patient clinic follow-up was recommended.

DISCUSSION

Ellis-van Creveld syndrome is a rare form of congenital heart disease that is inherited as an autosomal recessive trait. Abnormalities in different organs are seen with this syndrome, of which the cardiovascular system, skeletal

Correspondence: Ali Andon Petrossians, *Fellow of Electrophysiology,
**Associate Professor in Cardiology, Cardiovascular Research Center,
Shahid Rajaii Heart Hospital, Tehran, Islamic Republic of Iran.

Ellis-Van Creveld Syndrome

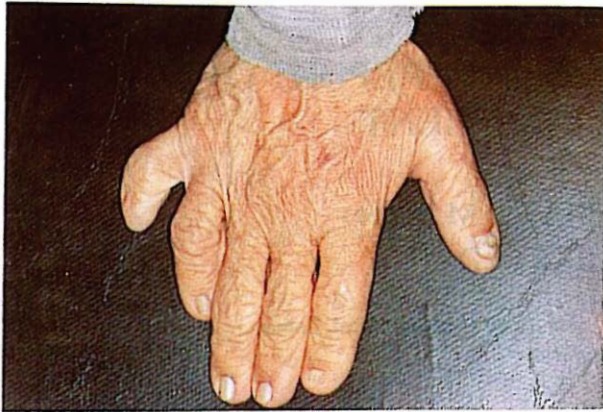

Fig. 1. Radiography of the hand shows six fingers and hypoplastic nails.

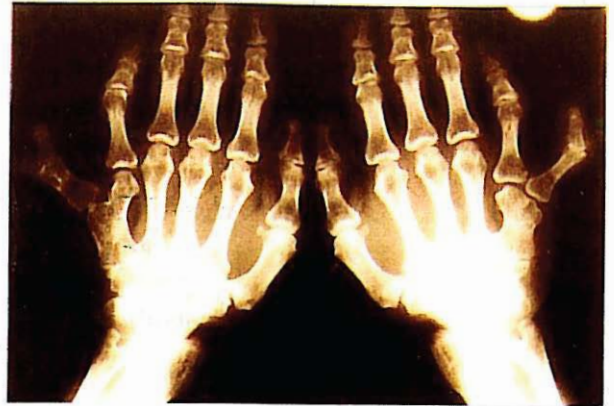


Fig. 3. X-ray of both hands showing polydactyly and fusion of the fifth and sixth metacarpals.

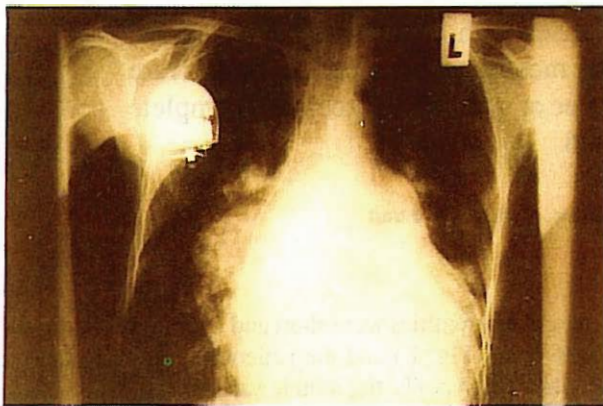


Fig. 2. Posteroanterior chest x-ray showing pulmonary artery at left hilar area and increased pulmonary blood flow in both lungs, especially the right lung. Pacemaker of the patient is also seen.

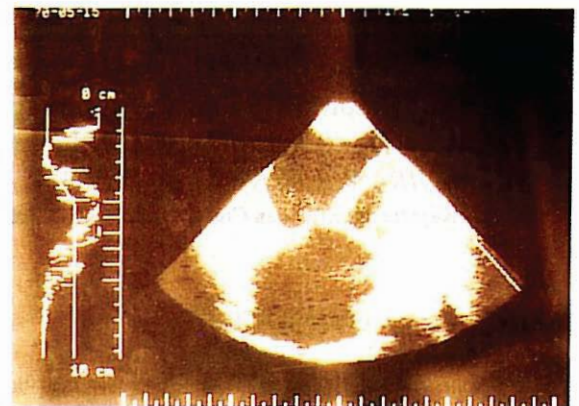

Fig. 4. Two-dimensional echocardiography, apical view, showing single atrium with two-chamber ventricle.

system, nails, and mouth are the most common.^{1,2}

Congenital heart disease is seen in 60% of patients and usually causes death in infancy (more than 50%), mostly due to cardiorespiratory problems. The most common cardiac lesion is single atrium or large atrial septal defect, and may be accompanied by hypoplastic left ventricle, aortic atresia, or hypoplastic ascending aorta.

Skeletal abnormalities are seen in 80% of patients, which consist of short stature in the range of 115 to 150 cm, bilateral polydactyly and fusion of the carpal bones,⁴ hypoplastic nails, and several oral abnormalities, namely labiogingival adhesions, accessory frenula, and hypodontia.³ Males and females are affected equally.

In this rare case, despite 68 years of age and a single atrium, patient presented with no significant symptoms except for mild palpitation and dyspnea. We did not plan

for cardiac catheterization due to old age and only yearly follow-up was suggested.

REFERENCES

1. Da Silva EO, Janovitz, de Albuquerque SC: Ellis-van Creveld syndrome, Report of 15 cases in inbred kindred. *J Med Genet* 17: 349-53, 1980.
2. Blackburn MG, Belliveau RE: Ellis-van Creveld syndrome. *Am J Dis Child* 122: 267-72, 1971.
3. McKusick VA, Egeland JA, Eldridge R, Krusen DE: The Ellis-van Creveld syndrome. *Bull Johns Hopkins Hosp* 115: 306-13, 1964.
4. Tayler GA, et al: Polycarpaly and other abnormalities of the wrist in chondroectodermal dysplasia. *The Ellis-van Creveld syndrome. Radiology* 151 (2): 393-6, 1984.