

## METAGENOUS CARCINOMA OF THE BREAST: SECONDARY DEPOSIT OF PAPILLARY CARCINOMA OF THE THYROID IN A BREAST WITH PRIMARY DUCTAL CARCINOMA - A COINCIDENCE

S.A. JALALI, M.D.

*From the Department of Surgery, Firoozgar Medical Center, Iran University of Medical Sciences, Tehran, Islamic Republic of Iran.*

### ABSTRACT

Papillary carcinoma of the thyroid constitutes 80% of thyroid malignancies in adults. Females are affected at least twice as often as males. It metastasizes to distant sites very rarely, but to the cervical nodes quite often. Occasionally metastatic lymph node enlargement is the sole presenting feature.<sup>1,3,6,7</sup> The tumor is slow growing and sometimes the patient has good survival even in spite of distant metastases. The following case is a coincidence of two separate rare diseases, one is metastasis of the thyroid papillary carcinoma to the breast and the second one is coincidence of this unheard metastasis with carcinoma of the breast itself. By my knowledge, this is the first case of its kind being reported.

*MJIRI, Vol. 6, No. 4, 303-305, 1993.*

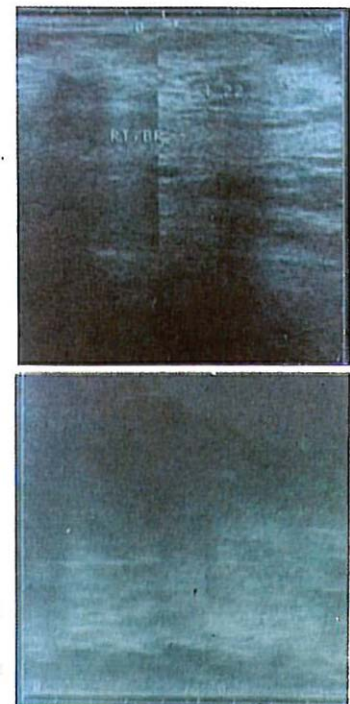
### CASE REPORT

A 56-year-old woman, was seen for a right breast mass. The breast mass was located in the retromamillary region with some nipple retraction. She also had a 2x3 cm movable node-like lesion in the axillary tail of her breast, which was thought to be an extension of her possible carcinoma of the breast (Fig. 1).

She had a history of thyroid lobectomy and isthmectomy for papillary carcinoma of the thyroid 25 years back. She also had developed pulmonary metastases of her papillary carcinoma 15 years later; and these pulmonary lesions were capable of picking up radioactive iodine on radionuclide scan (Figs. 2,3,4). At that time she went through a total thyroidectomy and neck dissection. The patient underwent  $I^{131}$  therapy as well as external beam radiation.

The progress of the pulmonary metastases seem to have ceased in recent years. This was clearly shown by the few chest x-rays that she had with her.

Clinically she was well and had no clinical signs or



**Fig. 1.** Sonogram of the breast, showing a solid mass. Abdominal sonography was reported negative at the same time.

## Metagenous Carainoma of the Breast

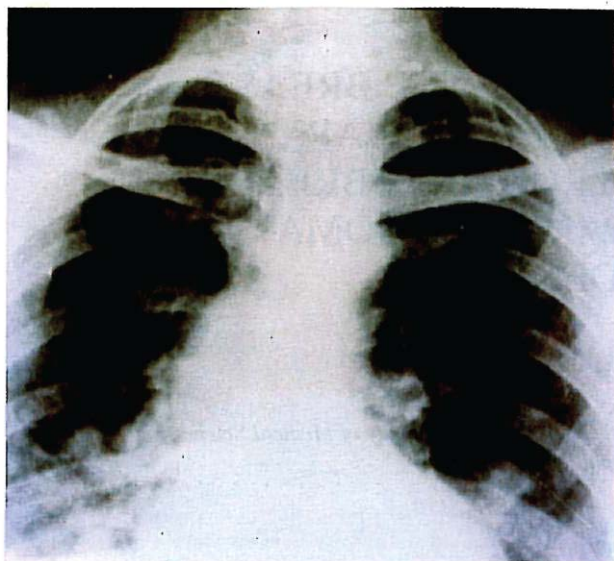


Fig. 2. Nodular densities in the lung fields, ten years before the last admission.

symptoms of pulmonary involvement; in other words, she was a quite fit individual except for her breast mass, thyroidectomy, and her silent pulmonary metastases. She was taking thyroid tablets for replacement therapy and control of her metastases and dihydrotachysterol because her parathyroids have also been removed in total thyroidectomy.

She was admitted for breast surgery. At surgery, frozen section of her retromamillary mass showed ductal carcinoma, so we proceeded with a modified radical mastectomy. The whole breast and axillary contents were removed and sent for histopathologic examination (Fig. 5).

Surprisingly, the firm node which was thought to be the extension of her breast carcinoma turned out to be papillary carcinoma of the thyroid. In the dissected axillary nodes a few were also positive for intraductal carcinoma of the breast which were not palpable on clinical examination before surgery (Figs. 6,7,8).

The patient had an uneventful recovery postoperatively. Chemotherapy was refused by the patient. She was quite well when seen six weeks after surgery.

### DISCUSSION

Distant metastases in papillary carcinoma of the thyroid is uncommon. In a 26-year study in the M.D.Anderson Cancer Institute in Texas, only 30 cases of PTC metastases have been diagnosed in the bones, lungs, mediastinum, and the liver.

The incidence of metastases is higher in the white population of the U.S.A. compared with the black

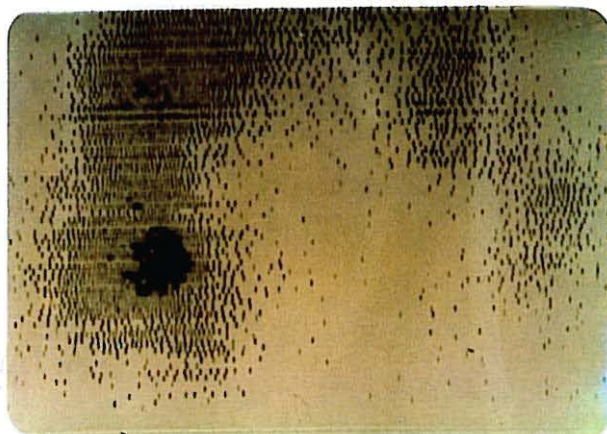


Fig. 3. I<sup>131</sup> uptake of the lung fields, especially in the middle and lower lobes of the right lung, proving the thyroid origin of the metastases.

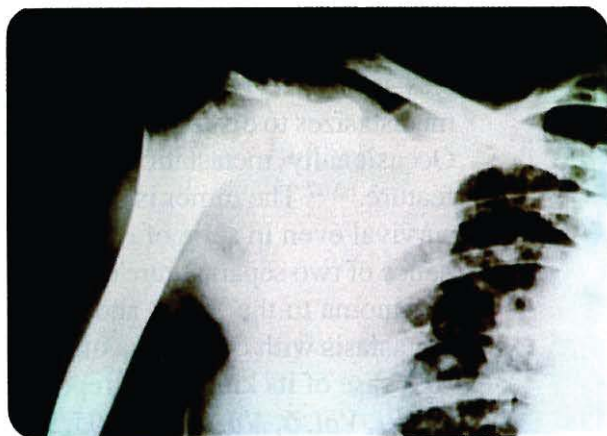


Fig. 4. Lytic lesions of the right shoulder along with pulmonary metastases.

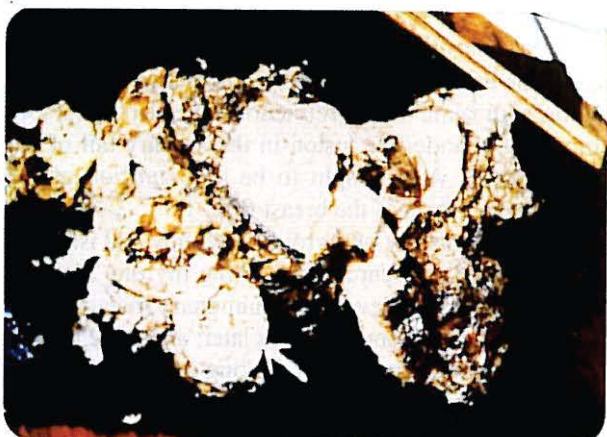

Fig. 5. Mastectomy specimen of lesion found to be papillary carcinoma (arrow).

Americans, but in the Spanish and Asian population the incidence of metastases is still higher than the two previously mentioned groups. In Iran the incidence is even



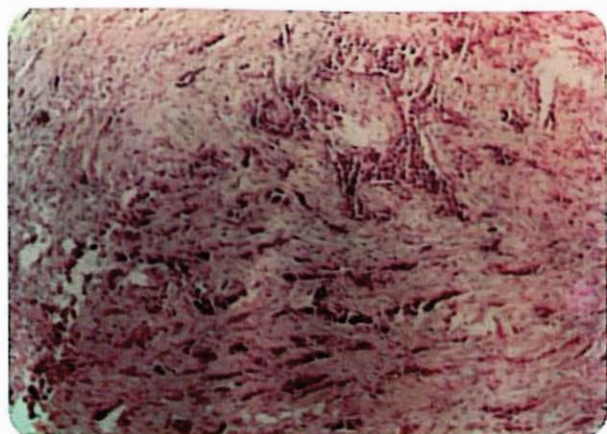


Fig. 6. Invasive breast tumor with fibrosis of the stroma.

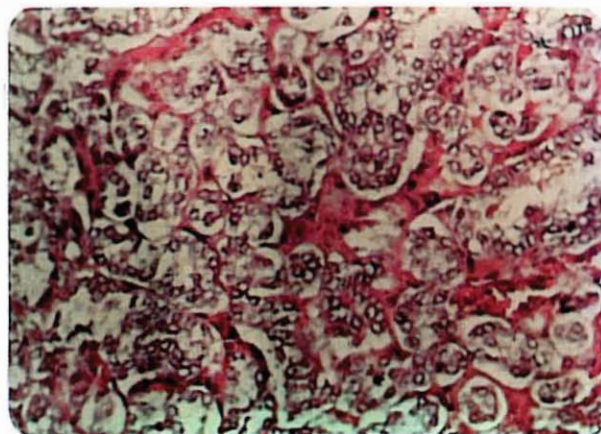


Fig. 8. Invasion of metastatic thyroid tumor to a lymph node.

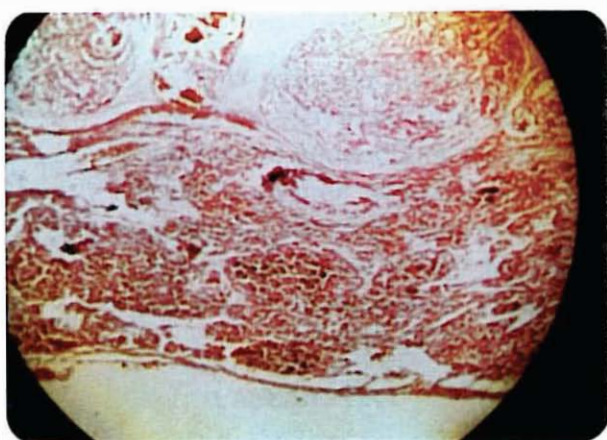


Fig. 7. Nucleated cells and ground-glass appearance with follicle formation.

higher than that; because we see these distant metastases occasionally. The reason for this could be genetic as well as improper and inadequate treatment of PTC. In my experience, I believe that the slow progression of the disease makes the patients not to follow their treatment protocol properly.

In the case presented, I would like to assume that the radiation therapy to the cervical and mediastinal nodes, could have caused the development of cancer of the breast twenty years later; this is a well known hypothesis which has been proved in Hiroshima. The secondary papillary carcinoma in the breast is indeed very rare and has never been reported to my knowledge. The interesting discussion is that whether this metastasis occurred as a blood-borne metastases just as she had metastases in her bones and lungs or this occurred as a lymphatic spread.

I believe that because the lymphatics of the breast have some anatomical connections with the cervical lymphatic chain, this metastasis could have occurred in a retrograde manner through lymphatics rather than via the blood stream. The interesting thing about the case is the genesis and coincidence of metastatic PTC of the breast and intraductal carcinoma of the breast at the same time.

Whether lung and bone metastases of the PTC caused her some lack of immunity which in turn in a twenty year period made her more prone for carcinoma of the breast, is not known.

## REFERENCES

1. Allo DM, et al: Not all "occult" papillary carcinomas are "minimal". *Surgery* 104(6): 971-6, 1988.
2. Bierwaltes WH: Carcinoma of the thyroid-radionuclide diagnosis, therapy, and follow-up. *Clin Oncol* 5(1): 23-35, 1986.
3. Grant S, et al: Local recurrence in papillary thyroid carcinoma: is extent of surgical resection important? *Surgery* 104(6): 959-62, 1988.
4. Nederie B, et al: Surgical treatment of distant metastases in differentiated thyroid cancer, indications and results. *Surgery* 100: 1088-97, 1986.
5. Schumberger M, Tubiani M, et al: Long-term results of treatment of 283 patients with lung and bone metastases from differentiated thyroid carcinoma. *J Clin Endocrinol Metabol* 63: 960-7, 1988.
6. Kaplan, EL: Thyroid and Parathyroid. In: Schwartz, S, et al (eds.). *Principles of Surgery*. New York, Mc Graw-Hill, 5th ed, P 1633-35, 1989.
7. Ingbar SH: Thyroid gland. In *Williams Textbook of Endocrinology*. 7th ed. W.B. Saunders, Philadelphia, 798-99, 1985.
8. Wood J, et al: Current results of treatment for distant metastatic well differentiated thyroid carcinoma. *Arch Surg* 124: 1374-7, 1989.