

## Original Articles

# MODIFIED METHYLMETHACRYLATE CRANIOPLASTY IN 127 CASES OF WAR CASUALTIES

MAZIAR AZAR, M.D., AHMAD TAHAMY, M.D., AND  
AFSOUN KABOLY, M.D.

From the Dept. of Neurosurgery, Iran University of Medical Science, Tehran, Islamic Republic of Iran.



### ABSTRACT

We report 127 cases who have had elective operation on cranium because of skull bone defect during 1984-1989. Usually repair of skull bone defect and preserving normal anatomy were the major therapeutic goals.<sup>10,11</sup>

In these cases a new surgical technique is described which can successfully accomplish these goals in a single but staged operative procedure.

*MJIRI, Vol. 6, No. 1, 1-6, 1992*

### INTRODUCTION

In standard technique of acrylic cranioplasty<sup>1-4</sup> after routine prep and drape the bony defect is freed from the underlying dura with a periosteal elevator. If the margin of the defect is irregular it will be rongeured back to the full thickness of the bone to facilitate insertion of the prosthesis.

A prosthesis of methylmethacrylate which is molded at the time of operation is suitable for repair of most cranial defects after mixing the powder and solvent in a metal basin in the consistency of thick syrup. The plastic is poured into a polyethylene bag. The bag is then placed over the cranial defect and stretched tightly by the assistants who exert digital pressure against the bony margins of the edges of the bag. It can be accurately shaped to recreate natural prominency. Then the bag is held in place until the plastic begins to warm up and become translucent. This is the beginning of the polymerization process which takes place rapidly and is associated with a great release

of heat. After the plastic has cooled off, it is removed from the bag and smoothed with rongeur or file. The plate is then secured to adjoining bone with wire or silk sutures through multiple drill holes.

Modified methylmethacrylate cranioplasty is going to progress with many difficulties and problems during

Table I. Etiological factors of cranial defect

shell fragment	87 cases
road accident in war field	20 cases
bullet injury	15 cases
falling down	3 cases
penetration of sharp foreign body	1 cases
grenade injury	1 cases

Table II. The site of cranial defects

A: single defect	89 cases
frontal	40 cases
parietal	29 cases
temporal	19 cases
orbit	1 cases
B: multiple cranial defects	38 cases
temporo-parietal	15 cases
parieto-occipital	7 cases
fronto-temporal	7 cases
fronto-parietal	4 cases
fronto-orbital	5 cases

Amiralmomenin Hospital

Shahr-Ara

P.O. BOX. 14455-481, Tehran, Tel. 985001-9

\*This paper was presented at the First Congress of Trauma in Kerman Medical School in April, 1989.

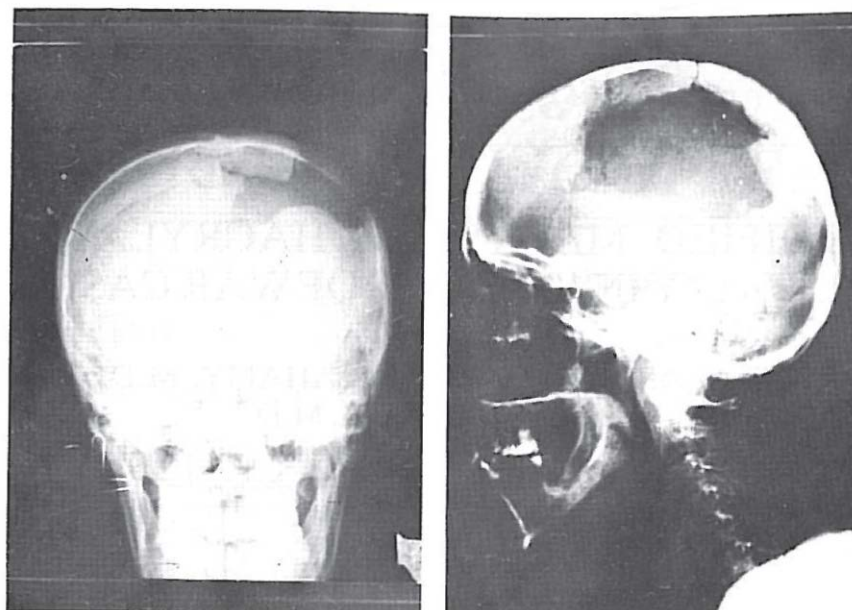


Fig. 1-2. Radiography of skull bone defect in war casualty.

the first few months as follow:

1) In the first step, the operation takes place through the previous incision. For dissecting skin from dura and related tissue we inject normal saline with adequate antibiotic, preferably from the bony margin to the center of defect. In this way the risk of dural tears, pneumocephalus and skin sacrificing is going to be very low.

2) In the standard technique, because of the removal and replacement of prosthesis the chance of dislocation is very high. In the modified technique we prefer to use methylmethacrylate syrup *in situ* and for cooling and prevention of brain damage and cortical vein thrombosis, we induce many holes in the prosthesis during polymerization and by injecting and irrigating with normal saline in the same holes, the induced heat is diminished and prevention of brain damage is gained.

3) Also for prevention of extradural hematoma and extradural effusion, we use tagging suture from the dura to the bone cement during the polymerization period to encourage adhesion of dura to prosthesis.<sup>19</sup>

4) In the standard type of operation the prosthesis is thin and risk of fracture is high. In our method because the prosthesis will not be removed it is thick enough, so for full fixation, we insert in a layer of methylmethacrylate under the bony margin and also another thin layer over it, but in large defects, because of the risk of fracture and displacement, we used wiring in the following way.<sup>21</sup>

In a large defect, by inducing x or + shape wiring through multiple drill holes in bone, at the beginning of the molding the fragility of the prosthesis is minimized. The remaining part of the operation is the same as

previously mentioned (Fig.10).<sup>7,17,18</sup>

5) The cosmetic aberration when the defect is in the face and frontal area is an important problem—in the single stage cranioplasty and the standard type is very difficult to reconstruct the normal shape of eyebrow and frontal bone.

We prefer staging this procedure of molding. At the

Table III. The size of the cranial defect and it's distribution

35 cases	36 cm <sup>2</sup>
28 cases	6 cm <sup>2</sup>
27 cases	9 cm <sup>2</sup>
12 cases	30 cm <sup>2</sup>
7 cases	20 cm <sup>2</sup>
4 cases	35 cm <sup>2</sup>
3 cases	24 cm <sup>2</sup>
3 cases	40 cm <sup>2</sup>
2 cases	16 cm <sup>2</sup>
2 cases	25 cm <sup>2</sup>
1 case	15 cm <sup>2</sup>
1 case	28 cm <sup>2</sup>
1 case	32 cm <sup>2</sup>
	42 cm <sup>2</sup>

The cases of defect size less than 20 cm<sup>2</sup> had forehead location

Table IV. The most frequent deficit associated with cranial defect

severe hemiparesis	30
seizures	22
post-traumatic syn	16
mild hemiparesis	15
visual deficit	12
speech deficit	11
deafness	1
post traumatic hydrocephalus	1
no detectable deficit	48

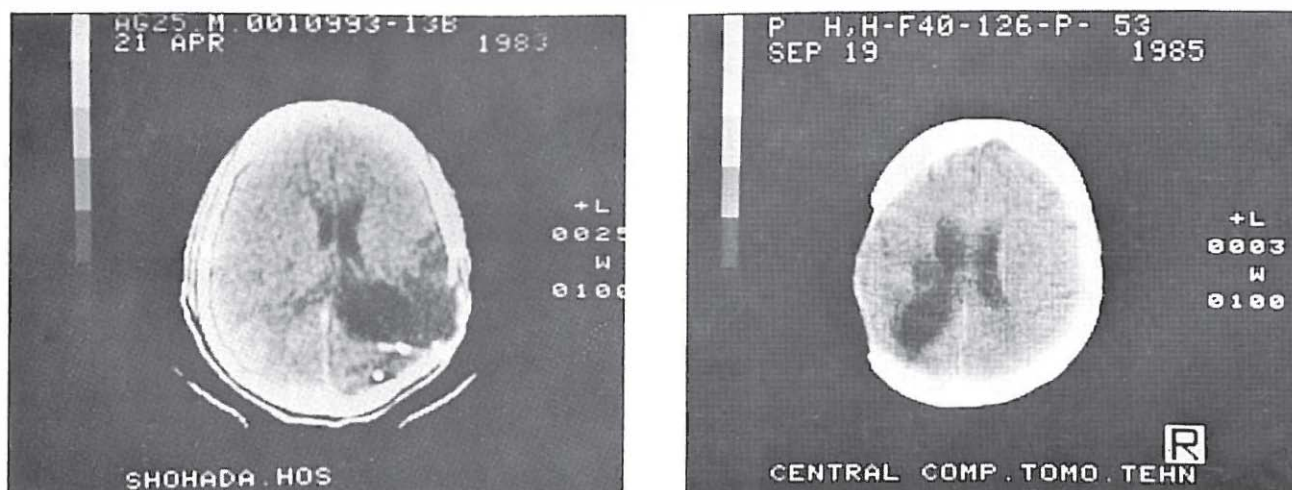


Fig. 3-4. C.A.T. Scans that show encephalomalatia and bone defect due to missile injury.

first step the coverage of defect is performed as mentioned above. Then by preparing another part of methylmethacrylate in 6-8 minutes, the surgeon and his assistant have enough time to build the prosthesis for the best shape of the face.<sup>22</sup>

We prefer to use the methylmethacrylate due to the following reasons:

a- Most of our patients have multiple trauma in

Table V. Complication of cranioplasty

seizure	5 cases
subcutaneous effusion	3 cases
infection	2 cases
intracerebral hematoma	1 case
mental intolerance	1 case

Table VI. The time between the first and second operation

4 months	5 cases
5 months	13 cases
6 months	26 cases
7 months	5 cases
8 months	13 cases
9 months	7 cases
10 months	3 cases
11 months	3 cases
1 year	26 cases
2 years	14 cases
3 years	5 cases
4 years	4 cases
6 years	1 cases
7 years	1 cases
10 years	1 cases

Table VII. Intracranial foreign body

intracranial bone fragment	46 cases
metallic fragment	28 cases
no foreign body seen	53 cases

head, limbs, chest and will not accept another destructive operation, for example removal of bone from iliac or elsewhere.

b- due to shell shock and other causes, most of the patients usually have psychiatric problems and will not accept that procedure.

c- Using autogenous bone graft for cranioplasty usually takes a long time and it is impossible to use this kind of operation for 127 patients in our situation.<sup>2,24,25</sup>

d- Usually in our technique the cosmetic result and protection of the brain is satisfactory.

## MATERIAL AND METHODS

The records of 127 patients who have had cranioplasty (125 men and 2 women) were admitted to the Amiralmomenin Hospital during 1984-1989. The average ages were between 5 - 70 years. Each patient had moderate to severe brain damage due to shell fragment injury.

The demographic data, the neurologic deficit , volume of brain loss in C.A.T. scan, remaining bone

Table VIII. Pre and post-operative medication

A: antibiotics	
1/	107 cases gentamicin 80 mg TDS and cephalothin 1g QID
2/	20 cases chloramphenicol 1g QID and ampicillin 1g QID
B: antiepiletics	
	197 cases
	dilantin (phenytoin) 100mg TDS and phenobarbital 100mg daily

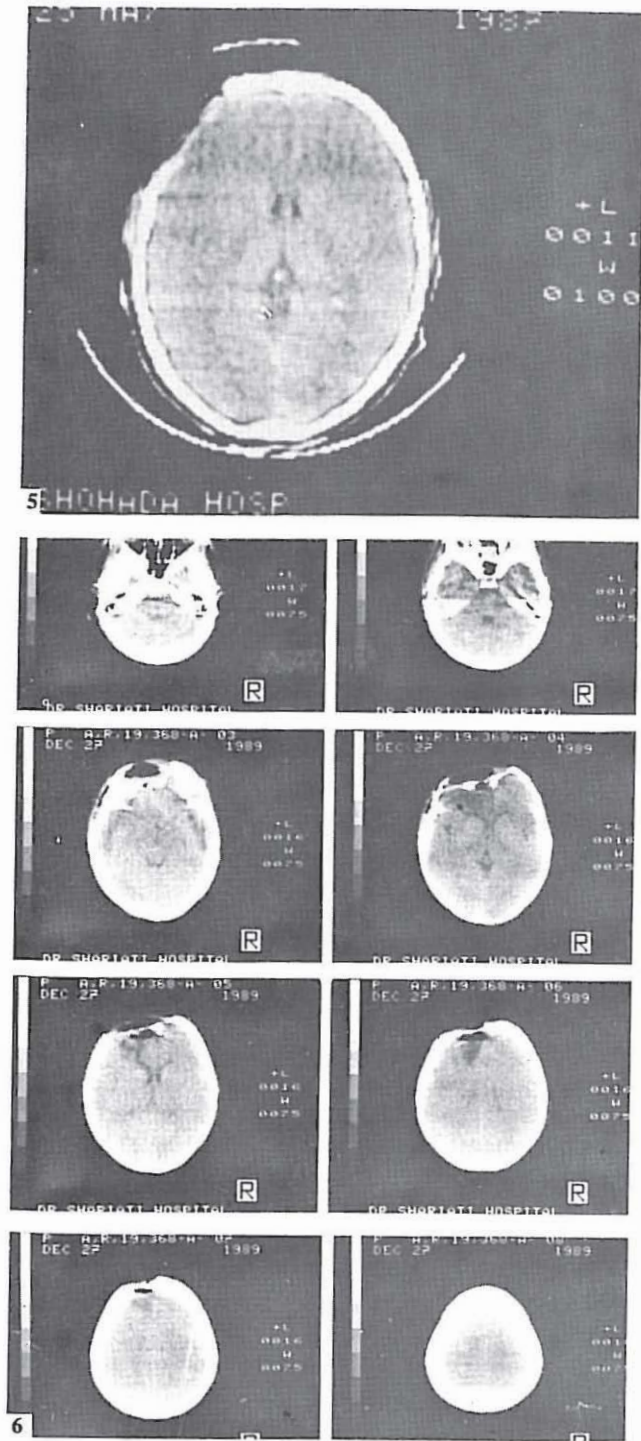


Fig. 5-6. Skull bone defect before cranioplasty.

and metallic fragment, site of injury and the duration between the first and second operation are summarized in Tables I-IV. The trauma in each patient was severe enough to penetrate the skull (in eight cases through and through)(Fig. 1.2).

Radiological studies including simple X-ray and C.A.T. scans were performed for all of them and in

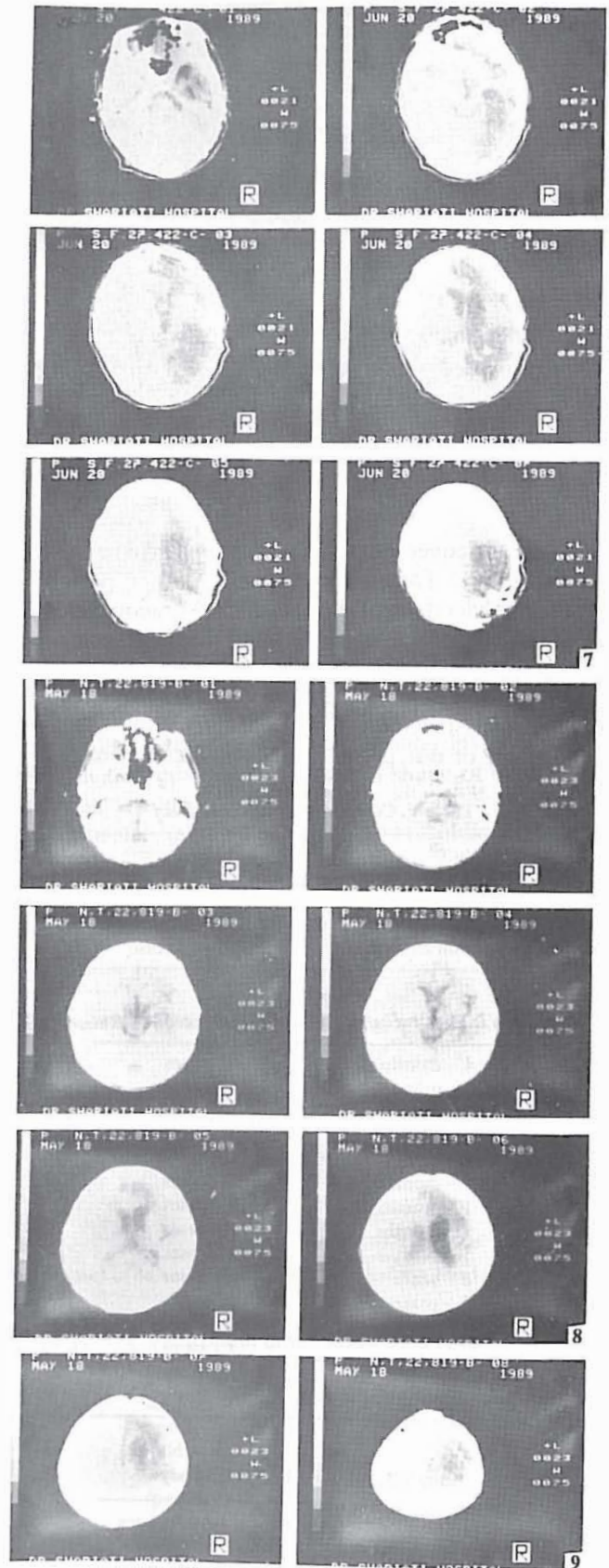


Fig. 7-8-9. 2 Patients after modified cranioplasty.

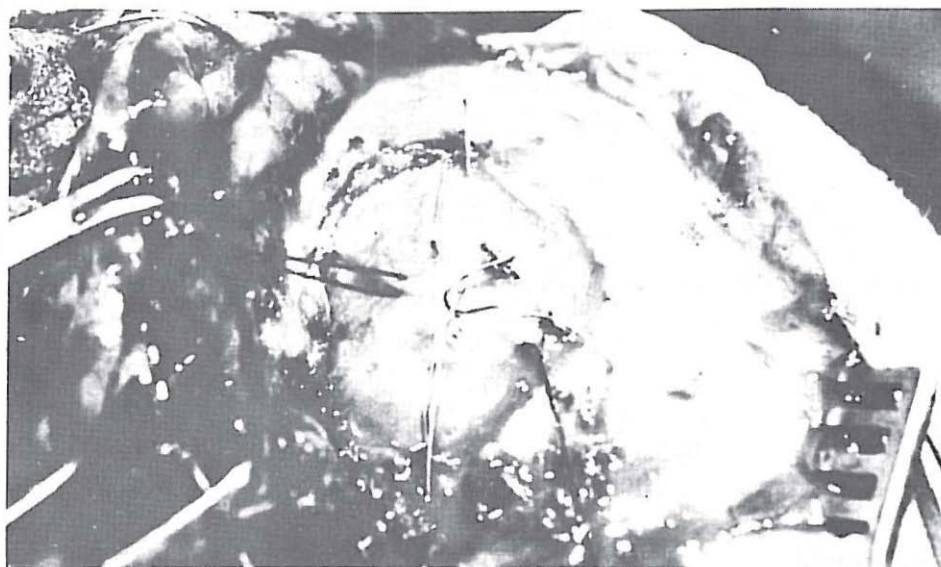

Fig. 10. During operative procedure.

cases that missile fragment has passed near major blood vessels, angiography was done for detecting traumatic aneurysm. Pre- and post-operative medications were given to prevent seizure and infection (Table VIII) (Figs. 3-4, 5-6).

All of them had a primary operation in the time of injury in the warfield hospitals performed by a neurosurgeon that included brain debridement, duraplasty (in most of them), and removal of accessible foreign body (bone and missile fragment).

According to the patients' history, the neurological condition in most of them between the first and second operation was stable.

## RESULTS

In following up these patients from four months to six years, there was two cases of infection due to *S.epidermidis* and one intracerebral hematoma that resolved spontaneously by medical treatment, five cases of grand mal epilepsy immediately after operation, and one case of subdural effusion that absorbed spontaneously. There was no case of dislocation, fracture and displacement.<sup>12,14,16,20,23</sup>

## DISCUSSION

In the modified technique previous incision is opened and there is no more skin loss; by injection of normal saline, the dissection of the dura from skin is facilitated, the chance of displacement and fracture minimized, and the cosmetic and brain protective result is excellent.

## ACKNOWLEDGEMENT

We are very grateful to Ms. Shaabaniy and Mr. Tehrani for manuscript preparation.

## REFERENCES

- 1-Prolo DJ: Cranial defects and cranioplasty. In: Clinical Neurosurgery. Williams & Wilkins Co, Baltimore, pp. 16-17-56.
- 2- Abbasioan K: Repair of skull defect with iliac bone graft. Nezam Pezeshki Journal (Persian) vol 4, No.1, p. 28, 1974.
- 3- Blair CAS, Fannin IF, Gordon DS: Titanium-strip cranioplasty. Br Med J 2:907-908, 1976.
4. Timmons RL: Cranial defects and their repair. In: Youmans JR, (ed). Neurological Surgery: A Comprehensive Reference Guide to the Diagnosis and Management of Neurosurgical Problems. 2nd ed. Philadelphia, W.B. Saunders. 1982, pp 2228-2250.
- 5- Black SPW: Reconstruction of the supraorbital ridge using aluminum. Surg Neurol 9:121-128, 1978.
- 6- Galicich JH, Hovind DH: Stainless steel mesh-acrylic cranioplasty: Technical note. J Neurosurgery 27:376, 1967.
- 7- Habbal MB, Leake DL, Maniscalco JE: A new method for reconstruction of major defects in the cranial vault. Surg Neurol 6: 137-138, 1976.
8. Karvounis PC, Chin J, Sabin H: The use of prefabricated polyethylene plate for cranioplasty. J Trauma 10:249-254, 1970.
- 9- Roux FX, Brasnu D: Madreporic caral: A new bone graft substitute for cranial surgery. J Neurosurg 69:510-513, 1988.
- 10- Williams. PL, Warwick R: The Skull. In: Gray's Anatomy. Churchill Livingstone, 1981, pp. 293-297.
- 11- Romanes GJ: The skull. In: Cunningham's Textbook of Anatomy. Oxford University Press. 1981, pp:108-109.
- 12- Till KD, Hoare R: Growing fractures of the skull. J Neurol Neurosurg Psychiatry 41:312-318, 1978.
- 13- Vanofakos DA: Case report: Recurrent osteoma overlying cranioplasty. J Neurosurgery 55:845-847, 1981.
- 14- Lahay GW, Weir B, Carter R: Case report: Dermatofibrosarcoma protruberans of the scalp treated by radical excision, immediate cranioplasty, and free groin flap. J Neurosurg 55:640-642, 1981.

## Cranioplasty in War Casualties

- 15- Sela M, Sahar A: Case report: Agenesis of parietal bones with restoration of the cranial vault. *J Neurosurg* 50:674-676, 1979.
- 16- Tabaddor K, La Margese J: Case report: Complication of a large cranial defect. *J Neurosurg* 44:506-508, 1976.
- 17- Scott M, Wyeis H T, Murtagh F: Long term evaluation of stainless steel cranioplasty. *Surg Gynec Obstet* 115:453-461. , 1962.
- 18- McFadden JT: Metallosurgical principals in neurosurgery. *J Neurosurg* 31:373-385, 1962.
- 19- Black S P W, Kam C C M, Sighs W P, Jr: Aluminum Cranioplasty. *J Neurosurg* 29:564, 1968.
20. Henry HM, Guerreo C, Moody RA: Cereberspinal fluid fistula from fractured acrylic cranioplasty plate. *J Neurosurg* 45:227-228, 1976.
- 21- Takis J, Asimacopolus M, Papadakis, N: Technical note: A new method of cranioplasty. *J Neurosurg* 47:790-792, 1977.
- 23- Charnley J: The reaction of bone to self-curing acrylic cement. A long term histological study in men. *J Bone Joint Surg* 52-B:340-353, 1970.
- 24- Kyoshima K: Cranioplasty with inner table of bone flap. *J Neurosurg* 62:607-609, 1985.
- 25- Matukas VJ: Hydroxylapatite-an adjunct to cranial graft. *J Neurosurg* 69:514-517, 1988.