

EXPERIENCE WITH ADRENOCORTICAL TUMORS IN CHILDREN: A REPORT OF ELEVEN CASES

M. RAZZAGHIAZAR, MD, J. AHMADI, MD, A. RABBANI, MD, N.
NEZAKATGOO, MD, M. MOSAVATI, MD. AND *Y. SHAFEGHATY,
MD

From the Department of Pediatric Surgery and Pediatric Endocrinology, Children's Medical Center Hospital, Tehran University of Medical Sciences, and Shahid Rahnamoon Hospital, Iran University of Medical Sciences, Tehran, Islamic Republic of Iran.

ABSTRACT

During a period of 15 years from 1975 to 1989, eleven children with adrenocortical tumors were managed with relatively favorable results in our center. Despite its rarity in the pediatric age group, our series is one of the largest reported in the literature in the given period of time. All of our 11 patients presented with hyperfunction of the adrenal cortex. Virilization alone was the most frequent presenting sign, occurring in eight patients.

Two patients suffered from Cushing's syndrome and one patient had mixed presentation of Cushing's syndrome and virilization. There were six females and five males in the series. Four of five males presented before two years of age. Female patients presented at an older age.

In nine out of 11 patients the tumor was on the right side. Mean age at presentation was 3.55 years. Serum levels of testosterone, dehydroepiandrosterone (DHEA), and cortisol were elevated in all cases tested and apparently are superior alternatives to more traditional measurements of urinary 17-ketosteroids and 17-hydroxy corticosteroids.

The majority of our cases were investigated by the employment of IVP and sonography. In one patient I¹³¹-iodocholesterol scintigraphy was used. Transabdominal approach through a transverse upper abdominal incision is recommended.

In this series only one intraoperative complication was encountered. At a mean follow-up of five years, 10 out of 11 children were alive and had no evidence of tumor recurrence.

In all patients pre-operative steroid replacement was essential. Contrary to our pathologic reports «six adenoma, three carcinoma, and two undetermined» we found favorable outcomes in the majority of our patients. We conclude that in contradiction to previous consensus, most pediatric adrenocortical tumors will behave as a benign neoplasm and that the size and weight are the only morphologic predictors of their biological behavior.

MJIRI, Vol. 6, No. 1, 29-34, 1992

Address reprint requests to Dr. J. Ahmadi, Head of Department of Pediatric Surgery, Children's Medical Center Hospital, Tehran University of Medical Sciences, Tehran, Iran.

INTRODUCTION

Adrenocortical carcinoma comprises only 0.2 percent of all malignancies encountered in the pediatric age group and represents only a small percentage of tumor of the adrenal gland.¹ Neuroblastomas represent the largest group of adrenal tumors.²

An overwhelming majority of adrenocortical neoplasms are hormonally functional in childhood, and in a review of 222 cases in childhood, it was found that two-thirds manifested with virilization as their predominant sign and one third suffered from hypercortisolism.³ Very rarely feminization and hyperaldosteronism have been described as the major primary presenting symptom complexes.⁴

In 1966, Hayles' review of the literature revealed a distressingly poor outcome in children with adrenocortical tumors and he found only 23 two-year survivors among 127 cases with known outcome.³ On the other hand, a review of adult cases showed a 50% 2-year survival rate.⁵ Many of the mortalities in the older literature are undoubtedly due to suboptimal perioperative care and inadequate steroid replacement.⁶ More recent series have shown an amazingly good prognosis in pediatric patients.^{2,7,8,9}

The purpose of this report is to present an institutional experience with analysis of 11 cases of adrenocortical neoplasms treated in our center and to compare our results with the recent consensus that more pediatric adrenocortical neoplasms will behave in a benign manner than previously reported.¹⁰

MATERIALS AND METHODS

A retrospective study of our hospital records of all patients with adrenocortical neoplasms 14 years of age and younger managed in the Children's Medical Center Hospital from 1975 to 1989 was carried out. In review of the charts the following parameters were considered to be of value: age, sex, major presenting complaint and clinical syndrome, plasma and urinary steroid values, associated anomalies, family history of other malignancies, radiological diagnostic modalities, pathologic reports, tumor size and weight, laterality, operative treatment and subsequent post-operative clinical course. Eleven cases were collected for this study. Data from all children 14 years or younger with adrenocortical tumors were extracted and formed the basis for the following statistical analysis.

RESULTS

During the period of study, eleven children suffering from adrenocortical neoplasms were treated.

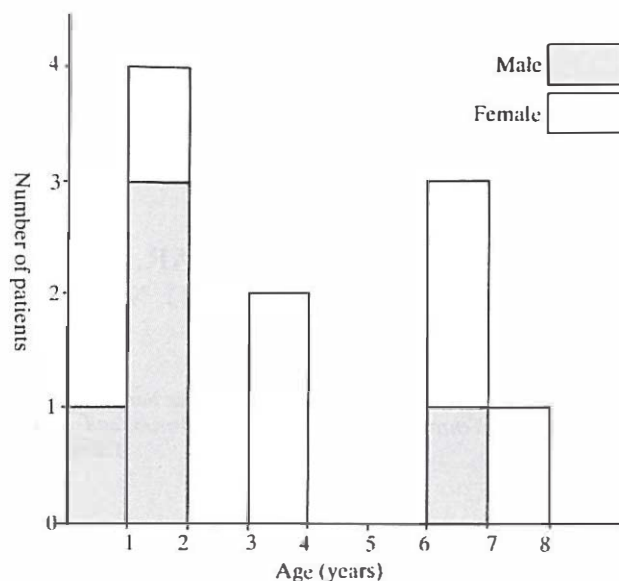


Fig. 1: Age distribution of the patients.

There were six girls and five boys. Their ages ranged from 11 months to eight years (mean age 3.55 years) as shown in Fig. 1.

Four out of five boys presented before two years of age (mean age for males, 2.28 years), while female patients manifested their main clinical symptom complexes at an older age (mean age for females 4.61 years). In 9 out of 11 patients the tumor was on the right side.

Virilization alone was the initial sign in eight patients, with cushingoid features prominent in two, and mixed Cushing's syndrome and virilization features in one patient.

Three patients had high blood pressure levels for their age. Two out of three patients with hypertension had Cushing's syndrome and another suffered from mixed Cushing's syndrome and virilization features.

Tables I and II illustrate the major clinical features noted at first presentation.

A majority of the patients were investigated by IVU and sonography with a satisfactory index of accuracy. Iodocholesterol scanning was done in one patient with unilateral visualization and enlargement of the right

Table I. Main Clinical Features

Cushing's syndrome		Virilization	
Central obesity	2	Hirsutism	7
Moon facies	2	Acne	5
Buffalo hump	1	Phallic enlargement	5
Hypertension*	3	Precocious puberty	3
		Hyperpigmentation	3
		Hoarseness	5
		Clitoromegaly	5

*Includes two patients with Cushing's syndrome and one patient with mixed virilization and Cushing's syndrome.

Table II, Summary of 11 cases with Adrenocortical Neoplasms

No	Age	Sex	Side	Presenting Symptoms	IVP	Sonography	Iodocholesterol	Histology	Weight	Treatment	Survival& outcome
1	15m	M	Rt	Virilization	Mass effect	-	+	U	-	Excision	alive after 6 years
2	12m	M	Rt	Virilization	Mass effect	tumor calcification	-	C	250 ^g	Excision	lost to follow up
3	20m	F	Rt	Cushing's	dropping flower appearance	mixed echogenicity	-	A	-	Excision	alive after 5 years
4	11m	M	Rt	Virilization	downward displacement of the Kidney	47 ^{mm} x 47 ^{mm} Rt supra-renal mass	-	A	110 ^g	Excision	alive after 5 years
5	6y	F	Rt	Virilization	Mass effect	-	-	A	400 ^g	Excision	alive after 6.5 years
6	21m	M	Rt	Virilization	displacement	mixed echogenicity	-	C	100 ^g	Excision	alive after 8.5 years
7	3y	F	Rt	Mixed Virilization+ Cushing's	calcification, downward mass displacement	-	-	C	-	Excision	alive after 6.5 years
8	6.6y	M	Lt	Virilization	Normal	-	-	C	-	Excision	alive after 2.5 years
9	3y	F	Rt	Virilization	Normal	-	-	A	30 ^g	Excision	alive after 4.5 years
10	6y	F	Rt	Virilization	downward displacement of the kidney	huge supra-renal mass, mixed echogenicity	-	U	1180 ^g	Excision of tumor c' residual tumor	recurrence+ died 1 year later
11	8y	F	Lt	Cushing's	downward displacement of the lt kidney	lt. supra-renal mass	-	A	143 ^g	inadvertant splenicin jury-adrenal-ectomy	alive after 9 years

U = undetermined C = carcinoma A = adenoma - = no. info. found

Table III. Summary of endocrinologic studies in our 11 patients.

No	Pathology	Urinary 17OHCS	Urinary 17 KS	Urinary Pregnatriol	Plasma cortisol	Plasma testosterone
1	U	0.16	6.5	0.06 (0-0.1)	23.12	2.1
2	C	-	35.82		19.44	
3	A	0.36	0	0.31 (0-0.1)	40.38	
4	A	6.16	50.11	0 (0-0.1)	16.11	45
5	A	1.85	35.83	Pre ACTH= O Post ACTH= ●	22.22	
6	C	0.33	118.32	NL	46.99	
7	C		22.64	0.81 (0-0.1)		
8	A	0.4	21.72			400
9	A	0.61		0.45 (0-0.1)	29.74	
10	U	0.9	1.38			20
11	A	3.66	9.1	0.46 (0.43-)	300	

adrenal gland with suppressive effect upon the left adrenal.

Fig.2 shows the iodocholesterol scan in patient no.1, and Fig.3 depicts sonographic finding of the mass in patient no. 2.

DISCUSSION

Although adrenocortical tumors are more common in adults than children, the presence of virilization, Cushing's syndrome and rarely, feminization in a child should seriously be investigated as being a possible case of adrenocortical neoplasm. Females more frequently develop the tumor than males, accounting for 65 to 90 percent in the reported series.¹¹

The female to male ratio was 6:5 in our series. While some investigators report a left sided prevalence,¹³ others have encountered a right-sided predominance.²

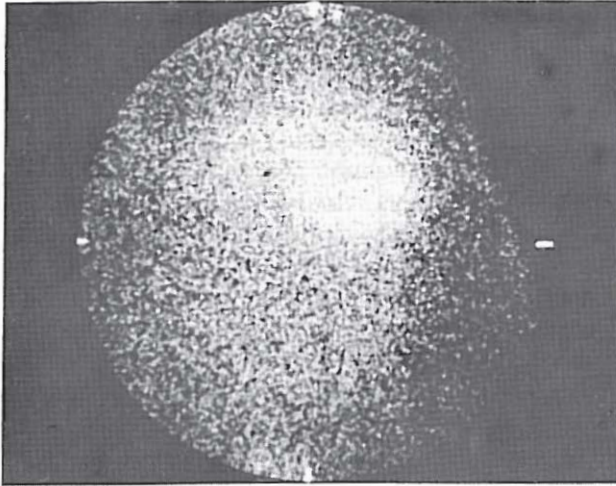


Fig. 2 Case No. 1, a 15-month-old boy with adrenal tumor, scintigram in posterior projection shows significant uptake in the area of right adrenal gland indicative of a functioning adrenal tumor (adenoma) with suppression of the left adrenal.

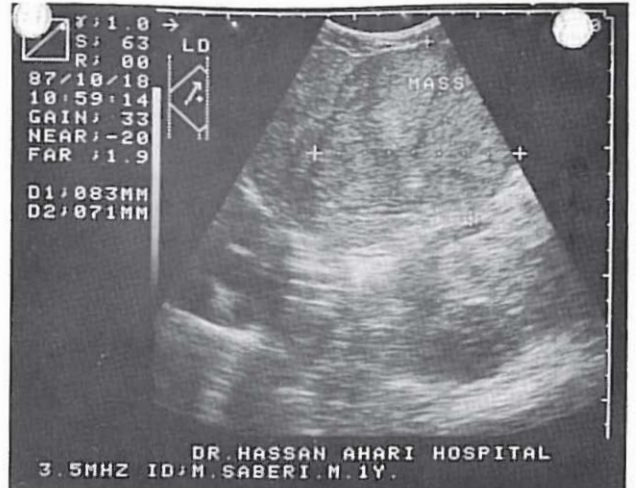

Fig. 3 Case No. 2, a 12-month-old boy with right sided adrenocortical tumor. Sonography of right flank shows a hyperechoic large, round, well-encapsulated mass, non-homogenous in character, causing displacement of the liver tissue in the area of the right adrenal gland indicative of adrenal neoplasm.

However, there was a significant right to left predominance in the present series with a ratio of 9:2, the reason for this significant discrepancy is unclear to us. Significant male involvement in our series is contrary to the results of Neblett, et al.¹³ that show a female to male ratio of 9:1. In their recent comprehensive review of the English literature from 1956 to 1986, 209 patients with adrenocortical neoplasms were found. The majority were female, with a female: male ratio of 2.2:1. Mean age at presentation was 4.63 years (range five days to 16.5 years). The age range of our patients varied from 11 months to eight years (mean age 3.55 years). In our series the occurrence of tumor was in a younger age range in males than females and four male patients out of five were under two years of age. This interesting incidence has not been reported in other series.

In a 20-year review of 141 cases of adrenal tumors in children in Manchester, England, 130 were neuroblastoma, three were pheochromocytoma and only eight were adrenocortical neoplasms.⁷ It seems that adrenocortical tumors are rare in the general population especially in childhood. One of the largest series from a single institution was reported by Neblett, et al.¹³ who in a retrospective study of hospital records of all patients with adrenocortical tumor 16 years of age and younger treated at Vanderbilt University Medical Center from 1956 to 1986, found only 10 cases.

Our series appears to be the largest single institutional report of the disease with 11 cases in a period of 15 years which is reported in the literature.

In adults, adrenocortical tumors occur more frequently in females, with a median age of 40 to 50 years.¹⁴ A similar female to male predominance has been noted in children. In the same series reported by

Neblett, et al.¹³ the female to male ratio was 2.2:1. Mean age at presentation was 4.63 years. In our series female to male ratio was 1.2:1. Hayles, et al.³ found a female to male ratio of 2.3:1. There appears to be a clustering of cases in early childhood in all pediatric series with the majority of cases occurring in children less than five years of age. Congenital cases have been reported sporadically¹⁵ but none of our cases had congenital adrenocortical tumor.

For unknown reasons a high incidence of congenital anomalies and secondary tumors has been reported in association with adrenocortical neoplasms. Hemihypertrophy alone or in combination with the Beckwith Wiedemann syndrome has been reported in several children with adrenocortical carcinoma.^{16,17} A relationship between hemihypertrophy and the development of Wilms' tumor, primary hepatocellular carcinoma, as well as adrenal tumors has been postulated previously.¹⁶ However we did not find any remarkable congenital abnormalities among the eleven cases in our series. Adrenocortical tumors have been reported in siblings¹⁸ and in families with strong history of malignancy.¹⁹ Of additional interest has been the occurrence of adrenal tumors in children with congenital adrenal hyperplasia, suggesting that chronic ACTH stimulation might lead to adenomatous and neoplastic changes.^{20,21}

The dramatic clinical presentation due to steroid overproduction makes adrenocortical neoplasms unique diagnostic entity. Signs of virilization are the most commonly expressed functional syndrome seen in children with adrenocortical tumors. Signs of virilization include increased muscle mass, hirsutism, rapid growth, facial and pubic hair, acne and clitoral or

phallic hypertrophy. Signs and symptoms of Cushing's syndrome are the second most common manifestation in children with adrenocortical tumors. The classic features of hypercortisolism include moonfacies, truncal obesity, buffalo hump, hypertension, impaired glucose metabolism, and growth arrest. Some of the patients with virilization will exhibit stigmata of Cushing's syndrome.

Nonfunctional tumors of adrenal cortical origin are rare and usually are detected late, because of absence of frank virilization and/or Cushing's syndrome. It has been stated that nonfunctional tumors occur more commonly in males and, in general, carry a grave prognosis.^{13,22}

Posterior labial fusion has not been associated with adrenocortical tumors and we did not encounter this phenomenon in any of our female patients, which suggests that excessive androgen exposure in early uterine life, like that of congenital adrenal hyperplasia, is not a usual feature of this disorder.

Regarding paraclinical diagnostic investigations, IVP and sonography of the adrenal glands were used in the majority of our cases with a relatively satisfactory index of accuracy.

graph may reveal a soft tissue mass or may demonstrate calcification in the area of the adrenal gland. Plain radiographs also serve to detect pulmonary or bone metastases. With improved technology, CT has demonstrated unequivocal diagnostic superiority over ultrasound in imaging the adrenal gland.²³ On the other hand the body of information concerning the role of MRI in imaging adrenal lesions is quickly increasing. Early reports indicate that MRI has accuracy comparable to that of CT in detecting adrenal masses larger than 1 to 2 cm.²⁴

to characterize adrenal tissue, differentiating between nonfunctioning adenomas and malignant adrenal lesions.²⁴ Experience in children is limited, but MRI has considerable promise, potentially replacing CT as the diagnostic choice in localizing adrenal lesions and assessing the extent of lesion.

Adrenal scintigraphy utilizing various iodocholesterol-labeled analogues has shown to be of diagnostic value.²⁶ Differential uptake makes it possible to distinguish between hyperplasia, adenomas, and carcinoma because the latter does not concentrate the radio nuclide as well as does normal tissue.

documented glucocorticoid excess, bilateral symmetrical images are indicative of adrenal hyperplasia. Unilateral uptake suggests an adenoma, and bilateral non-visualization are suggestive of carcinoma. However, experience in children has been very limited because of concerns about radiation exposure.

case No.1, this modality was used with a satisfactory index of accuracy.

scintigraphy is that imaging is accomplished in 4-7 days, and this could be an unacceptably long delay.

Recent reports suggest that serum DHEA, DHEA-S, cortisol, and testosterone assays may be useful alternatives with obvious advantages over the 24-hr urine collections in children.⁶ Levels of adrenal 21-steroid precursors, such as urinary pregnanetriol and serum 17-hydroxypregnenolone are minimally elevated in patients with adrenocortical tumors and measurement of the precursors may be useful in excluding adrenal hyperplasia. Elevated levels of DHEA, DHEA-S, testosterone, and cortisol makes the diagnosis of adrenocortical tumor with near certainty.

According to Neblett, et al,¹³ tumors producing 17-KS in excess of 40 mg/24-hr and large sized tumors have a high malignant potential. We did not have similar results and level of urinary 17-KS did not correlate with behavior of the tumors or prognosis of the patients in our series.

The definitive treatment for adrenocortical neoplasms is surgical resection. We prefer transabdominal approach by a large supraumbilical transverse incision starting from the bed of 12th rib and extending up to the lateral aspect of the contralateral rectus abdominis muscle.

In order to avoid stress of anesthesia and operation, the child should be supported by administration of stress doses of steroid, as the contralateral adrenal is usually atrophic. Many mortalities in the older literature seem to be due to postoperative complications and inadequate steroid replacement.

weaned from steroid support over a period of weeks to months as the normal endogenous steroid function returns.

Surgery should be aggressive, and if extensive local disease is present, wide en bloc resection of the tumor, nodes and perirenal fat and contiguous structures is advocated.

Chemotherapeutic agents used have been O, P'-DDD (mitotane), which causes adrenal destruction and fibrosis, leading to symptomatic relief but with quite equivocal and unproven effects upon longevity.^{3,22,27,28}

We do not recommend either radiotherapy or chemotherapy as a constant therapeutic adjuvant to surgery. These modalities could be advocated with caution in those cases with persistence of signs and symptoms and hormonal elevation post surgery and whenever there is radiographic or other evidence of metastasis.

The data on prognosis is conflicting and it appears that prediction of biologic behavior for adrenocortical neoplasms is even more difficult in children than adults.

this disease.³ However more recent reports have shown an unbelievably good prognosis.^{2,3,7,8,9} According to Cagle, et al¹⁰ and Neblett, et al,¹³ when metastasis or death from tumor are used as the criteria of malignancy, size appears to be the only reliable predictor of biologic behavior in adrenocortical neoplasms in children.

Of seven morphologic criteria used by Cagle, et al,¹⁰ including abnormal mitoses, necrosis, vascular and capsular invasion, broad fibrous bands, cellular pleomorphism, and size, only the latter (tumor size) was a reliable predictor of the tumors' behavior. All pediatric tumors weighing more than 500 gr were malignant and all but one weighing less than 500 gr were benign.

In a similar conclusion derived by Neblett, et al,¹³ tumors in excess of 500 gr are highly likely to behave in a malignant fashion, tumors less than 100 gr are very likely to exhibit benign behavior, and tumors between 100 gr and 500 gr are indeterminate.

In our series only case No. 10, a 6 year old girl with a tumor weight of 1180 gr, succumbed to therapy.

Therefore we also conclude that in contradiction to previous concensus, pediatric adrenocortical tumors are more likely to be benign, and that size and weight are the only morphologic predictors of their biologic behavior.

REFERENCES

- 1- Young JL JR, Miller RW: Incidence of malignant tumors in U. S. children. *J Pediatr* 86: 254-258, 1975.
- 2- Stewart DR, Jones PH, Jolleys A: Carcinoma of the adrenal gland in children. *J Pediatr Surg* 9: 59-67, 1974.
- 3- Hayles AB, Hahn HB, Sprague RG, et al: Hormone- secreting tumors of the adrenal cortex in children. *Pediatrics* 37: 19-25, 1966.
- 4- Bacon GE, Lowery GH: Feminizing adrenal tumor in a 6 year-old boy. *J Clin Endocrinol* 25: 1403, 1965.
- 5- Hutter AM, Kayhoe DE: Adrenal cortical carcinoma-clinical features of 138 patients. *Am J Med* 41: 572, 1976.
- 6- Lee PDK, Winter RJ, Green OC: Virilizing adrenocortical tumors in childhood: eight cases and a review of the literature. *Pediatrics* 76: 437-444, 1985.
- 7- Bulgur AR, Correa RJ: Experience with adrenal cortical carcinoma. *Urology* 10: 12, 1977.
- 8- Burrington JD, Stephen CA: Virilizing tumors of the adrenal gland in childhood: Report of eight cases. *J Pediatr Surg* 4: 291, 1969.
- 9- Zaitoon MM, Mackie GG: Adrenal cortical tumors in children. *Urology* 12: 645, 1978.
- 10- Cagle PT, Hough AJ, Pysner TJ, et al: Comparison of adrenal cortical tumors in children and adults. *Cancer* 57: 2235-2237, 1986.
- 11- Chudler RM, Kay R: Adrenal carcinoma in children. *Urol Clin North Am* 16: 469, 1989.
- 12- Cohn K, Gottsman L, Brennan M: Adrenocortical carcinoma. *Surgery* 100: 1170, 1986.
- 13- Neblett WW, Frexes- Steed M, Scott HWJ: Experience with adrenocortical neoplasms in childhood. *The American Surgeon*. 53: 117, 1987.
- 14- Didolkar MS, Bescher RA, Elias EG, et al : Natural history of adrenal cortical carcinoma: a clinico-pathologic study of 42 patients. *Cancer* 35: 549, 1981.
- 15- Artigas JR, Niclewicz ED, Silva APG, et al: Congenital adrenal cortical carcinoma. *J Pediatr Surg* 11: 247, 1976.
- 16- Fraumeni JF JR, Miller RW: Adrenocortical neoplasms with hemihypertrophy, brain tumors, and other disorders. *J Pediatr* 70: 129, 1967.
- 17- Tand ES, Kay R: Neoplasms associated with hemihypertrophy, Beckwith-Wiedemann Syndrome and aniridia. *J Urol* 124: 266, 1980.
- 18- Mahloudji M, Ronaghy H, Dutz W: Virilizing adrenal carcinoma in two siblings. *J Med Genet* 8: 160, 1971.
- 19- Kenny FM, Hashida Y, Askari HA, et al: Virilizing tumors of the adrenal cortex. *Am J Dis Child* 115: 445, 1968.
- 20- Bauman A, Bauman CG: Virilizing adrenocortical carcinoma. Development in a patient with salt-losing congenital adrenal hyperplasia. *JAMA* 248: 3140, 1982.
- 21- Pang S, Becker D, Cotellingam J, et al: Adrenocortical tumor in a patient with congenital adrenal hyperplasia due to 21-hydroxylase deficiency. *Pediatrics* 68: 242, 1981.
- 22- Richie JP, Gittes RF: Carcinoma of the adrenal cortex. *Cancer* 45: 1957, 1980.
- 23- Abrams HL, Siegelman SS, Adams PF, et al: Computed tomography versus ultrasound of adrenal gland: a prospective study. *Radiology* 143: 121, 1982.
- 24- Glazer GM, Woolsey EJ, Borello J, et al: Adrenal tissue characterization using MRI imaging. *Radiology* 158: 73, 1986.
- 25- Schultz CL, Haaga JR, Fletcher BD, et al : Magnetic resonance imaging of the adrenal gland: a comparison with computed tomography. *AJR* 143: 1235, 1984.
- 26- Thrall JH, Freitas JE, Beierwaltes WH: Adrenal scintigraphy. *Semin Nucl Med* 8: 23, 1978.
- 27- Berqenstal DM, Hertz R, Lipsett MB, et al: Chemotherapy of adrenocortical cancer with O, P'-DDD. *Arch Intern Med* 53: 72, 1960.
- 28- Hutter AM, Kayhoe DE: Adrenal cortical carcinoma: results of treatment with O, P'-DDD in 138 patients. *Am J Med* 41: 581, 1966.
- 29- Hoffman DL, Mattox VR: Treatment of adrenocortical carcinoma with O, P'-DDD. *Med Clin North Am* 56: 999, 1972.