

MASSIVE GASTROINTESTINAL HEMORRHAGE IN COMBAT CASUALTIES AND TRAUMA VICTIMS SECONDARY TO ARTERIO-VISCERAL FISTULAS

IRADJ FAZEL, M.D., F.A.C.S.

From the Department of Surgery, Taleghani Medical Center, Shahid Beheshti University of Medical Sciences, Tehran, Islamic Republic of Iran.

ABSTRACT

Massive upper gastrointestinal bleeding is a known complication of advanced sepsis in trauma patients and carries a grave prognosis. However, to our knowledge, an important cause of massive gastrointestinal bleeding, arterio-visceral fistula, has not been discussed in the literature. The most common cause of this unique clinical entity is penetrating high velocity abdominal injuries, although blunt trauma may also be responsible. Due to partial injury of the major intraabdominal vessels, a false aneurysm is formed. The intraabdominal false aneurysm, causing pressure necrosis in the intestinal wall, perforates into the gut with massive hemorrhage. Characteristics of this hemorrhage include its massive and bright red nature, recurrence, and curability with correct diagnosis and appropriate treatment. Our experience with sixteen cases, clinical presentation, diagnostic features and surgical treatment is discussed in this paper.

MJIRI, Vol. 4, No. 3, 165-172, 1990

INTRODUCTION

Massive gastrointestinal bleeding is not a rare complication following trauma or war injuries. The complexity as well as the variation of the extent of these injuries and high incidence of general and intraabdominal sepsis may lead to massive gastrointestinal hemorrhage, which most commonly originates from the upper gastrointestinal system. Although under these circumstances a preexisting duodenal ulcer may become active and cause severe hemorrhage, the most common cause seen in practice is diffuse gastritis which complicates the septic course of these critically ill patients. Due to uncontrolled sepsis, multi-organ fai-

lure and grave general condition of these victims, the hemorrhagic episodes carry a grim prognosis and high mortality.^{12,19,20}

A less frequent but extremely important cause of massive gastrointestinal bleeding in combat casualties and trauma victims is arterio-visceral fistula. This is a relatively new finding for which we found no major discussion in the literature.

To express the importance of this form of gastrointestinal bleeding, two factors are worth mentioning:

1- Gastrointestinal bleeding secondary to arterio-visceral fistulas is massive, causing profound hypovolemic shock, and of repetitive nature resulting in death of the victim if not correctly diagnosed and managed.

2- Unlike other forms of gastrointestinal bleeding in war and trauma victims, arterio-visceral fistulas carry an excellent prognosis, provided that correct and timely diagnosis and treatment is offered.

Address for correspondence:

Iradj Fazel, M.D., F.A.C.S.

Professor of surgery
Shahid Beheshti University of Medical Sciences, Tehran, Islamic
Republic of Iran.

A concise and objective discussion concerning the clinical presentation, diagnostic features and surgical treatment of these lesions is presented in this paper.

MATERIAL AND METHOD

Case No. 1

A 21 year old man, with history of high velocity abdominal trauma and repair of perforation of anterior and posterior wall of the antrum of the stomach, was readmitted to a military hospital three weeks later because of epigastric abdominal pain and nausea and occasional vomiting. During hospitalization, he had three episodes of massive upper G.I. bleeding accompanied by profound hypovolemic shock. Endoscopy report following the first episode indicated mucosal irritation and superficial ulceration in the distal posterior wall of the stomach.

Following the second episode six days after the first one, he underwent emergency laparotomy, and reported mucosal lesions were suture ligated through a gastrotomy incision, in addition to vagotomy and pyloroplasty. Four days later, he developed the third episode of massive bleeding and was reexplored. No active bleeding was found and several more mucosal sutures were inserted. Six days later, following another episode of massive hematemesis, the patient was typical of arterio-visceral fistula, and prior to any further investigation, the patient underwent emergency laparotomy because of recurrent massive hematemesis following his resuscitation. A firm mass, 6cm in diameter, was palpable behind the antrum of the stomach. The previous gastrotomy incision was opened and clots were evacuated. The mucosa of posterior antral area was severely congested, with some superficial necrosis and multiple silk sutures in an area of 5×5 cm which was elevated by the mass. There was no active bleeding. The abdominal aorta was controlled under the diaphragm and the false aneurysm was opened through an incision in the posterior wall of the stomach. Following evacuation of the clots, a partial defect was found in the wall of the artery with active pulsatile bleeding. This was easily controlled by a transfixing suture, ligating the injured artery. After debridement the posterior and anterior antral area were repaired in two layers. Patient's recovery was rapid with no further bleeding episode.

Case No. 2

A 20 year old male patient was admitted to our service because of an abdominal mass and pain. He had a history of exploratory laprotomy because of missile injury two months prior to admission but no operative report was available. The patient had been dismissed two weeks post-operatively with satisfactory general condition, however, he continued to have vague abdo-

minal pain, and found a mass in his abdomen, which had been progressively enlarging. Physical examination revealed a young patient with good general condition, who walked normally into the clinic. There was a prominent mass visible in the right paraumbilical area. Subcutaneous veins were augmented indicating active venous collaterals. There was mild edema in the lower extremities bilaterally. On palpation, a 20×20 cm, firm, fixed mass was palpable. An obvious machinery murmur was audible over the mass. Intravenous pyelogram showed a normal left kidney with no function on the right side. Patient was admitted with the diagnosis of false aneurysm with arteriovenous fistula originating from the retroperitoneal vessels. Abdominal angiography was ordered. On the second hospital day at midnight the patient suddenly vomited large amounts of bright red blood accompanied with profound shock. Considering the grave condition of the patient, unavailability of sufficient amount of blood and obvious clinical diagnosis of arterio-visceral fistula, the patient was explored as an emergency. A very large, firm, fixed retroperitoneal mass occupied the central and right side of the abdominal cavity. The severely displaced aorta was palpable, coursing the left wall of the mass. The aorta was freed up beneath the diaphragm and cross clamped. The aneurysmal cavity was opened directly via an incision in the anterior wall. Despite the presence of the proximal aortic clamp, active bleeding was noticed from a defect in the wall of the abdominal aorta which was controlled immediately with finger pressure.

was repaired easily with lateral suture technique and the aortic clamp was released. On the opposite wall, a similar hole in the vena cava was repaired. The vena cava which was completely collapsed due to the pressure of the false aneurysm, was found to be patent, and active circulation resumed.

The forceful expansion of the aneurysm, displacing and stretching the third portion of the duodenum, resulted in perforation of the bowel due to pressure necrosis and massive bleeding into the gut. The duodenum was repaired in two layers after proper debridement. The patient's post-operative recovery was rapid and uneventful. Right kidney function was normal in I.V.P. one week post operatively and signs of venous stasis disappeared completely.

Wounds of major arteries, especially the abdominal aorta, cause immediate death due to rapid exsanguination and rarely do such victims reach hospital facilities alive. In this case, the passage of a missile between the aorta and vena cava created an instant arteriovenous fistula and autotransfusion of the hemorrhage from the aorta. The expansion of the hematoma gradually displaced the aorta and vena cava, obstructed the right ureter and vena cava and finally perforated into the duodenum.

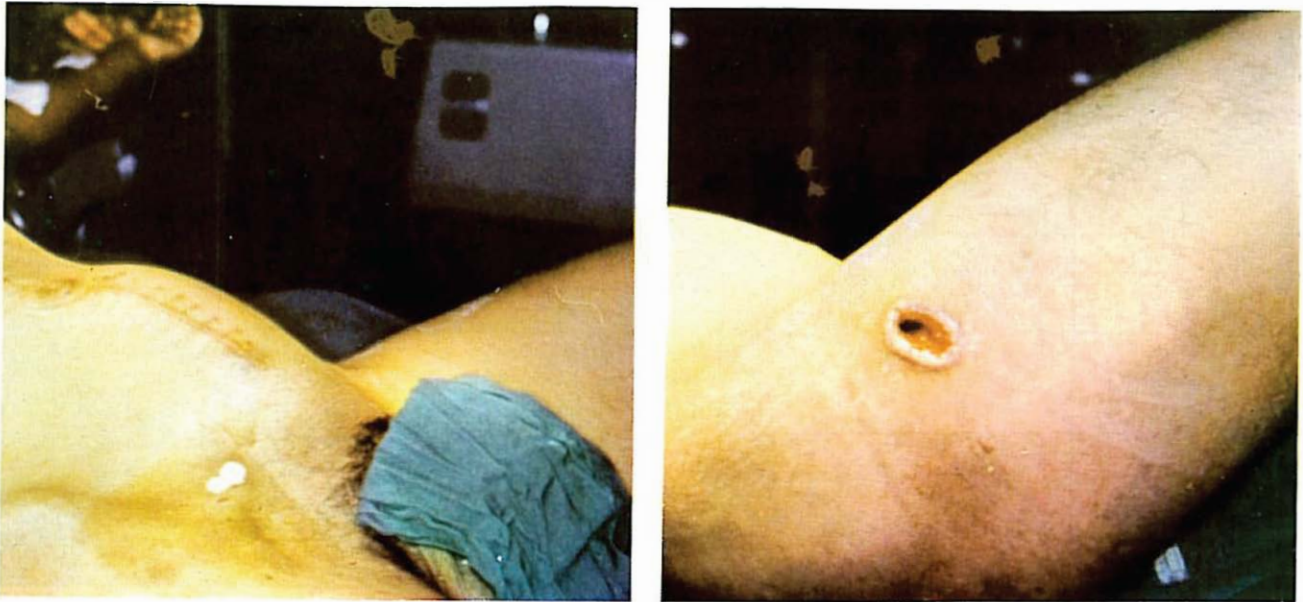


Fig. 1. A,B. A large mass in the left lower abdomen.

Case No. 3

A 19 year old war casualty with missile injury of the abdomen underwent emergency laparotomy and repair of multiple small bowel perforation in one of the front hospitals. While receiving post-operative care in the army hospital in Tehran, on the 16th post-operative day, he developed massive rectal bleeding accompanied with profound shock. He responded well to emergency treatment. After two more similar episodes, on the 22nd and 24th post-operative days, he was transferred to the author's service as an emergency consultation. He was found to be a grossly anemic, pale, afebrile apprehensive young man, blood-pressure was 100/60 and pulse rate was 110. He had no active bleeding. There was tenderness and fullness in the left quadrant of the abdomen, and fresh blood in the rectum with a tender firm mass in the left pelvic area. Due to the obvious clinical picture, impending recurrent bleeding and lack of angiographic facilities at the time due to technical difficulties, the patient was explored following adequate transfusion and volume replacement. A false aneurysm, measuring 10 cm in diameter was found in the left hypogastric artery which was adherent to a segment of terminal ileum, the site of previous repair of bowel perforation, and perforated into the bowel. The artery was ligated and resection-anastomosis of the small bowel carried out. The patient was dismissed in good general condition after a normal recovery period.

Cases No. 4,5,6

Three other combat casualties were treated subsequently due to arterio-visceral fistula in the pelvic

region.

One of these cases, a 22 year old man, was admitted with a large, firm, pulsatile mass in the left lower quadrant of the abdomen. This patient received a large shell fragment in the upper left thigh area, coursing toward the pelvis. Emergency laparotomy in the front-line hospital was reported negative except for a pelvic wall hematoma. Two weeks later, the patient started to have left lower quadrant abdominal pain radiating to the left lower extremity. Pain was of an increasing nature and made the patient unable to walk. On the 22nd post-operative day, while still in hospital, he developed massive bright red rectal bleeding resulting in severe hypovolemic shock and cardiac arrest. The patient was resuscitated and emergency consultation was requested from the author's service. He was found to be an athletic young man with extremely severe pain of the abdomen and left thigh. A large obvious mass was visible in left lower abdomen measuring 20×20 cm (Fig. 1, A, B). The left hip was fixed in the flexed position. Rectal examination was painful, with bright red clots present in the rectum. A firm mass was palpable in the left pelvic area with the tip of the finger. Left leg circumference was 4 cm larger than the right. The left femoral and pedal pulses were absent but the leg was warm and viable. A mild bruit was audible over the mass. Considering the obvious clinical diagnosis and possibility of recurrent bleeding, the patient was explored following volume replacement. A huge mass occupied the entire left pelvic area, displacing the rectosigmoid colon anteriorly and to the right. Operative angiography (Fig. 2, A, B) revealed a large false aneurysm in the distal left common iliac artery. Prior to

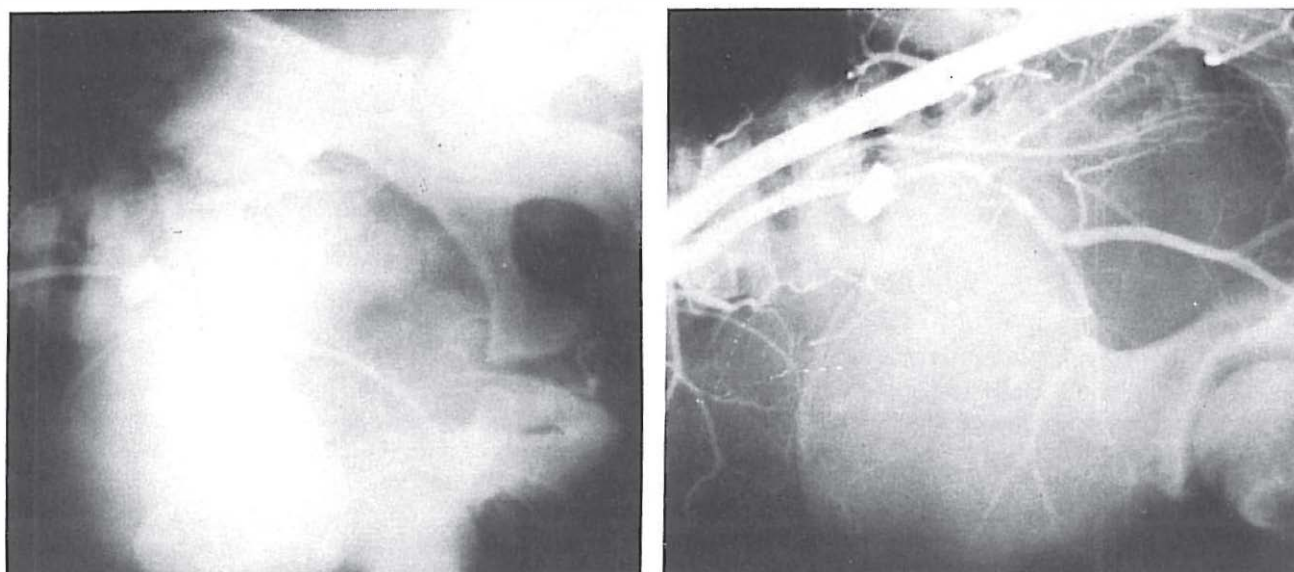


Fig. 2. A, B. Operative angiogram reveals a large false aneurysm in the distal left common iliac artery.

exploration of the aneurysm, an extra-anatomical ilio-femoral bypass was carried out with dacron graft passing through a healthy channel around the aneurysm (Fig. 3). The graft was completely covered proximally and distally. With proximal and distal control, the aneurysm was opened and clots evacuated. A 5×4 mm hole was present in the distal common iliac artery. This was completely controlled with 2-0 silk suture ligatures. A small defect in the wall of the colon was repaired after debridement and proximal colostomy was carried out. The patient's post-operative

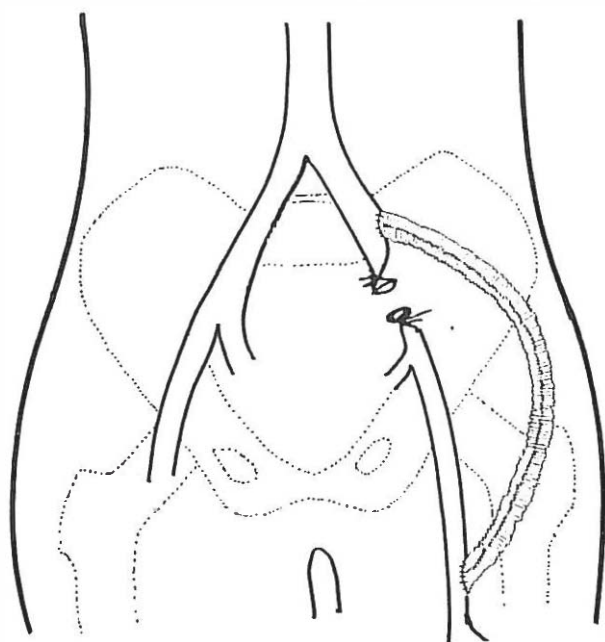


Fig. 3. Extra-anatomical ilio-femoral bypass with dacron graft is demonstrated.

course was uneventful. Pain was completely relieved and he was walking on the 3rd post-operative day.

Eight cases of major hemobilia secondary to arterio-biliary fistula have been encountered which are reported separately.⁴

As is shown in Table I, despite the multiple episodes of massive bleeding, all cases were salvaged mainly due to their young age and excellent healthy background.

Time elapse between the initial trauma and first bleeding episode ranges between eleven to fifty-eight days. Except in cases of major vessels, the involved artery can be safely ligated proximal and distal to the lesion.

Pathophysiology

False aneurysms have long been recognized in combat casualties and trauma victims, and surgeons involved with trauma cases have been familiar with their notorious nature since old times.^{18, 22, 30, 31, 38}

These lesions result from laceration of the arterial wall by sharp penetrating objects or missiles.^{34, 35} Due to high arterial pressure, especially in larger vessels, the immediate bleeding is violent, commonly causing profound hypovolemic shock. Tamponade of the sizeable resultant hematoma and concomitant drop in arterial blood pressure will seal the breach in the wall of the artery with fresh clots and result in cessation of the hemorrhage.

After ten to fifteen days, the hematoma will begin to liquefy due to fibrinolytic activity and the resulting cavity will communicate actively with the high pressure arterial lumen. This communication creates a dangerous lesion known by various terms, including pulsating hematoma, pseudo-aneurysm or false aneurysm,

Table I. Summary of seven cases of arteriovisceral fistulae.

| No | Age | Primary insult | Period between initial trauma and first bleeding | Kind of Hemorrhage | Bruit | Mass | No of Bleeding episodes | anatomic site of fistula | operation on the vessel |
|----|-----|------------------------|--|--------------------|-------|------|-------------------------|------------------------------|---------------------------------|
| 1 | 21 | shell fragment to abd, | 29 Days | Hematemesis | - | - | 6 | R+ Art. to stomach | Ligation |
| 2 | 20 | " | 58 " | " | + | + | 1 | Aorto-duodenal | Lateral Repair |
| 3 | 19 | " | 16 " | Rectal Bleeding | + | + | 3 | Hypogastric Art. to jejunum | Ligation |
| 4 | 17 | bullet wound | 19 " | " | - | - | 3 | Hypogastric Art. to colon | Ligation |
| 5 | 24 | " | 18 " | " | + | + | 1 | " | Ligation |
| 6 | 22 | shell fragment | 22 " | " | + | + | 1 | Common iliac Art. to sigmoid | Liga. + extra-anatomical bypass |
| 7 | 19 | " | 11 " | " | - | - | 2 | Branch of Mesenteric Art. | intestinal resection |

which continues to grow rapidly. As a result of this abnormal communication, the high arterial pressure is transmitted to the central cavity of the hematoma via the arterial defect, exerting a crushing effect on the surrounding tissues, causing pressure necrosis in these structures.³

aneurysm is one of constant enlargement along with progressive destruction of the surrounding muscles, nerves and soft tissue structures and final perforation with massive and occasionally fatal hemorrhage.³

In the extremities, these lesions are easily recognised and external bleeding due to perforation would attract immediate attention to the neglected ones.

intra-or retroperitoneal arteries is injured by a penetrating object or passing missile, the same lesion may develop in the abdominal cavity. Most of such injured patients undergo laparotomy within a short interval from the initial trauma, but such lesions may be easily overlooked by even competent surgeons because of temporary silence of the existing hematoma and lack of active bleeding. The victim will continue to have an apparently uneventful recovery with no detectable symptoms suggesting the presence of a vascular lesion and may well be dismissed from the hospital.

meantime, the vascular lesion undergoes the above-mentioned changes, and after activation of the hematoma will cause mild to severe abdominal pain which is of

constant and increasing nature. A firm mass representing the false aneurysm may become palpable in the abdomen. Occasionally the mass is obviously pulsatile. The presence of a systolic bruit or machinery murmur is a valuable but not common finding. Following activation of the hematoma the aneurysm begins to expand and exert a crushing effect on the surrounding structures. The fixed portions of the gastrointestinal tract, mainly the duodenum and colon, become adherent to the compressed tissue which forms the wall of the aneurysm. Two factors seem to play the most important role in the pathophysiologic sequence involved in the formation of the arterio-visceral fistula: (1) pressure necrosis of surrounding tissues, and (2) the histolytic activity of gastrointestinal secretions.

the false aneurysm, or in other words, the forcefully compressed surrounding normal tissues and structures, lacks the ability to withstand arterial pressure. As a result, the compressed tissues and segment of the bowel undergo pressure necrosis. The breakage in the mucosal barrier and digestive effect of potent gastrointestinal enzymes from outside the aneurysm, compounded by the constant pulsatile pressure of the false aneurysm from inside will finally result in perforation of the aneurysm into the gastrointestinal system with formation of an arterio-visceral fistula and massive hemorrhage, which has the following characteristics: 1- The hemorrhage is of arterial nature, presenting as

Traumatic Massive Gastrointestinal Hemorrhage

bright red hematemesis or rectorrhagia, 2- Bleeding is of sudden onset with no prodromal symptoms, 3- Bleeding is massive resulting in profound hypovolemic shock, 4- Bleeding is always of recurring nature, with intervals varying from several hours to several days, and 5- Unlike other forms of gastrointestinal bleeding, it is accompanied by abdominal pain which is occasionally relieved to some extent following each hemorrhagic episode.

Diagnosis

The characteristic clinical findings in arterio-visceral fistula are usually clear enough for the clinician to make a correct and timely diagnosis. In general, any war casualty or trauma victim with abdominal injury who develops massive bright red gastrointestinal bleeding must be suspected of having an arterio-visceral fistula.

Bleeding duodenal ulcer and hemorrhagic gastritis as well as conditions causing bleeding from the colon can be easily ruled out by endoscopy.¹⁹

absence of such lesions, recurrent massive gastrointestinal bleeding with the aforementioned characteristics, must lead to the preliminary diagnosis of arterio-visceral fistula and performance of selective abdominal angiography. In cases in which perforation occurs into the stomach (case no. 1) the unwariness of the endoscopist to the possibility of such lesions may lead to the erroneous diagnosis of acute gastritis. However, unlike gastritis which is diffuse, these lesions cause well-localised ischemic changes. If a pulsatile mass has been identified previously, occurrence of massive gastrointestinal bleeding of sudden onset is the key to the diagnosis and is an indication for immediate laparotomy (case nos. 2-6), since any delay for angiographic procedures may lead to the death of the victim due to rapid exsanguination.

penetrating abdominal trauma who develop massive recurrent upper or lower gastrointestinal bleeding, the strong possibility of an arterio-visceral fistula or hemobilia must be considered and angiography or abdominal CT scan carried out.

uniformly suggested as the best diagnostic tool for the diagnosis of hemobilia.^{34,39} Our past experience with eight cases of major hemobilia leads us to believe that CT scan is much preferred to angiography due to the following reasons:

1- CT scan is never false-negative, while due to temporary clotting of the intrahepatic false aneurysm, angiography may become false-negative.

2- CT scan shows the actual size of the lesion, while angiography only reveals the small central cavity, usually in one plane.

3- CT scan shows the precise anatomic location of the lesion, therefore it is of value in selecting a correct surgical approach.

4- CT scan is noninvasive, safer and requires less time.

It must be mentioned that in cases of civilian hemobilia in which much smaller lesions are encountered, most of the lesions can be treated by embolization through the angiography catheter.^{5,29,30} Obviously, in such cases, angiography is still the procedure of choice.

Treatment

A correct and timely diagnosis followed by appropriate surgical procedure and control of the damaged artery as well as repair of the gastrointestinal tract is the only way to save the life of patients suffering from arterio-visceral fistulas. When a major artery such as the aorta or iliac artery is involved, (case no. 2 and 6) proximal and distal control is necessary to prevent excessive bleeding while opening the false aneurysm. In the case of aortic involvement (case no. 2) control of the aorta at the level of the diaphragm was necessary.

When the smaller arterial branches are injured, the false aneurysm is opened directly and the arterial defect which becomes evident instantly with active bleeding is controlled easily with the tip of the finger. In the majority of the cases, the damaged artery is small and may be easily controlled by a suture ligature. In the case of major arteries, the defect is usually small, since the larger defects would cause exsanguination and immediate death of the victim at the scene. These defects must be repaired with either lateral suture or patch graft depending on the size of the defect.

Due to contamination of the surgical field, use of synthetic grafts must be avoided unless the graft is placed in an extra-anatomical position without danger of contamination (case no. 6).¹ After debridement, the intestinal wall is repaired using routine technique.

DISCUSSION

One of the known complications of true abdominal aortic aneurysm is massive gastrointestinal bleeding which results from the development of an aorto-duodenal gastrointestinal bleeding which results from the development of an aorto-duodenal fistula.^{2,4,11,15,24} Due to dense adhesions between the wall of the aneurysm and the fourth portion of the duodenum, part of the wall of the bowel is destroyed and the aneurysm becomes directly exposed to the lumen of the bowel. The earliest symptom is gastrointestinal bleeding of minor to mild degree which presents as tarry stools.^{4,15,24,3} In our opinion, this mild gradual hemorrhage which may continue for days or weeks originates from the margin of the defect in the wall of the bowel and is not related to the impending aortoduodenal fistula. The effect of potent digestive

enzymes on the exposed aneurysm wall and increasing weakness would result in final rupture of the aneurysms into the gut, causing exsanguinating hemorrhage which is commonly and immediately fatal.^{2,3,11,15} Other than major hemorrhage, old age, generalized atherosclerosis, and common history of coronary artery disease are among the major contributing factors to the mortality of this catastrophe. Awareness of the importance of melena in the presence of aortic aneurysm or history of aortic bypass procedures and use of endoscopy for correct and reliable diagnosis are the key factors to save these patients before the fatal hemorrhage occurs.^{2,3,11,24,38}

Massive gastrointestinal bleeding in combat casualties or trauma victims which originates from an intra-abdominal false aneurysm has some differences with classic spontaneous aorto-duodenal fistula. All cases reported in this paper have been transferred to our unit following one or multiple episodes of massive gastrointestinal bleeding. No patient gave a history of passing tarry stools, so we are not aware of prodromal gastrointestinal bleeding in traumatic false aneurysm. Another point is that unlike classic aortoduodenal fistulas which commonly result in the patient's death, the traumatic arterio-visceral fistulas are rarely lethal during the first bleeding episode. One of the characteristics of these patients' bleeding is its recurrent and massive nature, which usually responds to volume replacement. This is in contrast with atherosclerotic aortoduodenal fistula. Several factors are worth considering in this regard. The trauma patients and combat casualties are usually young and healthy and are able to tolerate severe hypovolemic shock. In contrast, the atherosclerotic fistulas usually occur in older patients with generalized atherosclerosis and coronary artery disease, in whom hypovolemic shock is poorly tolerated.

The second point is the source of bleeding in aorto-duodenal fistulas, which is usually from a small branch. Not only is bleeding less severe from a smaller artery, but it also has the ability to undergo severe spasm following hypotensive shock, resulting in cessation of bleeding.

In case no. 2 despite the origin of the bleeding from the abdominal aorta, the young age of the patient and immediate operative procedure on the basis of clinical diagnosis, saved the patient's life.

REFERENCES

- 1- Baker MS, Fisher JH, et al.: The endoscopic diagnosis of aorto-duodenal fistula. *Arch Surg* 111:304, 1976.
- 2- Bunt TJ: Synthetic vascular graft infections, graft enteric erosion and fistulas. *Surgery*, 94:1, 1983.
- 3- Daughtery M, Shearer GR, Ernst CB: Primary aorto-duodenal fistula. *Surgery* 86:399, 1979.
- 4- Fazel, I: Hemobilia, A surgical curiosity. *Iranian Surg Assoc*,

- Shiraz, May 14, 1985.
- 5- Feliciano DV, Burch JM, Graham JM: *Abdominal Vascular Surgery: Trauma*. Norwalk, Appleton&Lange, p.518-536, 1988.
- 6- Feliciano SV: Abdominal Vascular Injuries. *Surg Clin North Am* 68(4): 741-757, 1988.
- 7- Feliciano DV, Accola KD, Matto KL.: Management of injuries to the supra-renal aorta. *Am J Surg* 26:313, 1986.
- 8- Floyd WN: Traumatic hemobilia, coordination of roentgenographic, scintigraphic and angiographic findings. *South Med J* 27:420, 1979.
- 9- Goldblat M, Rad FF: Percutaneous embolization for the management of hepatic artery aneurysms. *Gastroenterology* 73:1142, 1977.
- 10- Goodnight JE, Blaisdell FW: Hemobilia. *Surg Clin North Am* 61:973, 1981.
- 11- Hardy JD, Timmis HH: Abdominal aortic aneurysms, special problems. *Ann Surg* 173:946, 1971.
- 12- Green WL, Bollinger RR: Stress ulcer prophylaxis. *Crit Care Med* 12: 571-575, 1981.
- 13- Hughes CW: Acute vascular trauma in Korean casualties: an analysis of 180 cases. *Surg Gynecol Obstet* 89-91, 1945.
- 14- Hunter J: A treatise on the blood vessels, inflammation and gunshot wounds. George Nicol, London, 1794.
- 15- Javid H, Julivan DC, Dye JA: Complication of abdominal aortic grafts. *Arch Surg* 85:142-54, 1962.
- 16- Kashuk JL, Moore EE, Millikan JS, et al: Major abdominal vascular trauma. A unified approach. *J Trauma* 22:672, 1982.
- 17- Kleinman HL, Towne JB, Bernhard WM: A diagnostic and therapeutic approach to aorto-enteric fistulas. 33rd Ann Meet Soc for Vas Surgeons. Nashville, TN, June 30, 1979.
- 18- Lexer E: The operation of the arteriovenous aneurysms. *Arch Klin Chir*, 83: 459, 1907.
- 19- Lucas CE, Sugawa C, Friend W, Walt AL: Therapeutic indications of disturbed gastric physiology in patients with stress ulcerations. *Am J Surg* 123: 25-34, 1972.
- 20- Lucas CE, Sagawa C, Riddle J, Rector F, Rosenburg B, Walt AJ: The natural history of surgical dilemma of «stress» gastric bleeding. *Arch Surg* 102:226, 1971.
- 21- Manlove GH, Quattlebaum FW, Flom RS, La Fave JW.: Gunshot wounds of abdominal aorta. *Am J Surg* 99, 941, 1960.
- 22- Matas R: Traumatic aneurysm of left brachial artery, incision and partial excision of the sac. *Recovery*, *Phila Med News* 53:463, 1888.
- 23- Millikan JS, Moore EE: Critical factors in determining mortality from abdominal aortic trauma. *Surg Gynecol Obstet* 130:313, 1985.
- 24- Mir Majlesi SH, et al: Endoscopic diagnosis of aortoduodenal fistula. *Gastrointestinal Endoscopy* 19:187-8, 1973.
- 25- Murray G: Surgical repair of injuries of main arteries. *Am J Surg* 83:480, 1982.
- 26- Ngu VA, Konstam PG: Traumatic dissecting aneurysm of the abdominal aorta. *Br J Surg* 52:981, 1965.
- 27- Nielson MC, Mygind T: Selective arterial embolization in traumatic hemobilia. *World J Surg* 4: 357, 1980.
- 28- Nielson MC, Mygind T, Miskowiak J: Blood pool scintigraphy and arterial embolization in traumatic hemobilia. *Eur J Nuc Med* 7:389-9, 1982.
- 29- Nolan B: Vascular injuries. *J Roy Coll Surg* 13:72, 1968.
- 30- Peck IA: A clinical lecture of a case of arteriovenous aneurysm. *Med Times Gaz* 2:677, 1883.
- 31- Pick TP: On partial rupture of arteries from external violence. *St. George Hospital Rep (Lond)* 6:161, 1873.
- 32- Ranninger K, Menguy R, Kittle CF, Abrams E: Angiographic diagnosis of hemobilia. *90:507-509, 1968.*
- 33- Reilly LM, Altman, et al.: Late results following surgical management of vascular graft infections. *J Vas Surg* 1:36, 1984.
- 34- Rich NM, Hobson RW, Collins GJJr: Traumatic arteriovenous fistulas and false aneurysms, a review of 558 lesions. *Surgery* 78:

Traumatic Massive Gastrointestinal Hemorrhage

- 817, 1975.
- 35- Rich NM, Spencer FC: *Vascular Trauma*: Philadelphia, W.B.Saunders, p. 241-54, 1978.
- 36- Salam AA, Stewart MT: New approach to wounds of the aortic bifurcation and inferior vena cava. *Surgery* 98:105, 1985.
- 37- Sandblom P : Traumatic hemobilia. *Surgery*42:571, 1984.
- 38- Schwartz AM: The historical development of methods of hemostasis. *Surgery* 44:604, 1958.
- 39- Shumacker HB Jr, Carter KL: Arteriovenous fistulas and false aneurysms in military personnel. *Surgery*, 20:9, 1984.
- 40- Tracy GD, Reeve TS: Mortality in ruptured abdominal aortic aneurysm. *J Surg* 35:85, 1965.
- 41- Walter JF, Passo BT, Cannon WB: Successful transcatheter embolic control of massive hemobilia. *Am J Roentgen* 127:847-9, 1976.