

THYROID FOLLICULAR ADENOMA: BENIGN OR MALIGNANT?

HOSSEIN GHARIB, M.D.

From the Division of Endocrinology and Internal Medicine, Mayo Clinic and Mayo Foundation, Rochester, Minnesota, U.S.A.

ABSTRACT

Four patients are described in whom a follicular carcinoma developed following thyroidectomy for a benign follicular neoplasm. It is possible that the initial thyroid neoplasm was a well-differentiated follicular carcinoma which was microscopically indistinguishable from a benign adenoma. Realizing this pathologic pitfall in thyroid diagnosis, the need for meticulous examination of the pathologic specimen is emphasized. Long-term postoperative reassessment is recommended.

MJIRI, Vol. 4, No. 3, 173-176, 1990

INTRODUCTION

Follicular adenoma is the most common type of cellular thyroid adenomas.¹ There is considerable debate whether follicular adenoma of the thyroid, a benign neoplasm, is a precancerous lesion which occasionally may be mistaken for a carcinoma.^{2,3} On the other hand, several published reports indicate that a follicular adenoma which appears benign by conventional histologic criteria, may demonstrate malignant behavior.⁴⁻⁶

This report describes four patients whose thyroid lesions had been classified histopathologically as benign follicular adenomas and who subsequently exhibited a malignant clinical course.

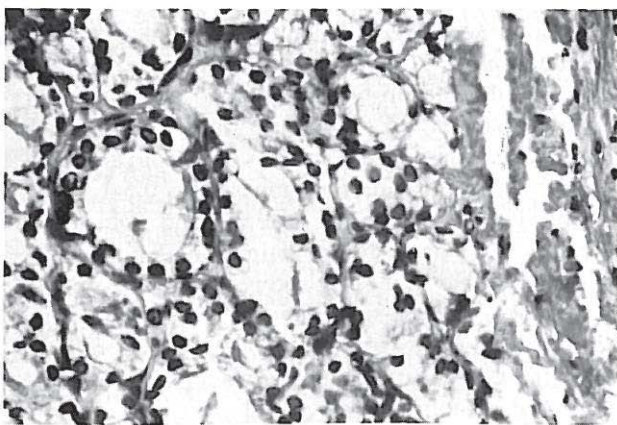


Fig. 1. Specimen showing «benign» follicular cells from the initial thyroidectomy in case 1 ($\times 400$).

CASE REPORTS

Case 1

A 49-year-old woman was referred for evaluation of metastatic thyroid carcinoma. She was in good health until six months earlier when she complained of insomnia and nervousness. Two months before admission a routine chest x-ray revealed metastatic nodules in both lungs. Extensive laboratory tests and radiographic studies were negative. A diagnostic left thoracotomy showed «low grade thyroid cancer» and she was referred for further examination. Her past medical history was significant in that a «benign» right thyroid nodule was removed 16 years earlier. The patient received no further therapy.

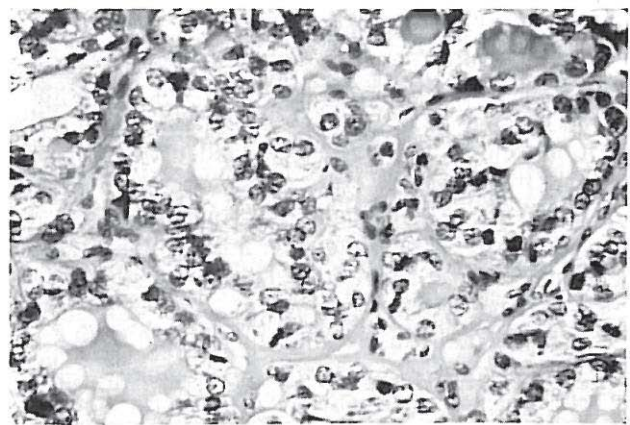


Fig. 2. Well-differentiated follicular carcinoma in case 1 ($\times 250$).

Thyroid Follicular Adenoma

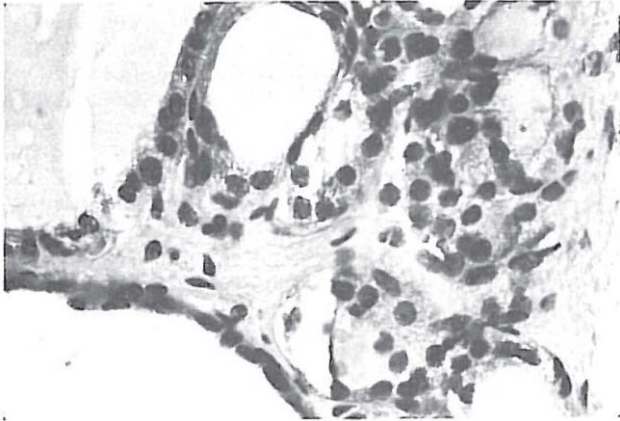


Fig. 3. Microscopic appearance of the primary follicular tumor in case 3 ($\times 400$).

On examination, she was euthyroid, a 2 cm firm nodule was present in the right lobe of the thyroid. Total T4 was 6.4 $\mu\text{g}/\text{dl}$. A thyroid scan showed uptake in a small right and normal left lobe. An ^{131}I total body scan disclosed a diffuse and confluent uptake over both lungs with focal spots of uptake in the right and left shoulders, left lower humerus, lumbar spine, and in the left sacroiliac joint and left maxilla. A chest x-ray showed multiple nodules throughout both lungs with right hilar adenopathy.

A review of slides from her first thyroid operation showed a benign and well differentiated microfollicular process (Figure 1). The review of slides from her recent thoracotomy disclosed a small nodule of well differentiated thyroid follicular tissue embedded in pulmonary parenchyma. Total thyroidectomy was performed and revealed a 2.5 cm well differentiated grade 1 follicular carcinoma well encapsulated and situated intrathyroidally in the right lobe (Figure 2). Multiple small microfollicular adenomas were also present in the left lobe. After ablative radioiodine therapy, she was dismissed on suppressive L-thyroxine therapy.

Case 2

A 69-year-old woman presented in 1963 with gradual enlargement of her goiter. Twenty years earlier she was found to have a left lobe solitary nodule at this institution and surgery was recommended, but she had declined thyroidectomy. On examination, she was euthyroid and the thyroid gland was multinodular and diffusely enlarged. Subtotal thyroidectomy revealed multiple degenerating micro and macrofollicular adenomata in a colloid thyroid (Figure 3). Ten years later (1972), a subcutaneous nodule had appeared beneath the thyroidectomy scar and excisional biopsy and pathologic examination at her local hospital disclosed a follicular carcinoma. A review of available slides confirmed grade 1 follicular thyroid carcinoma. She was

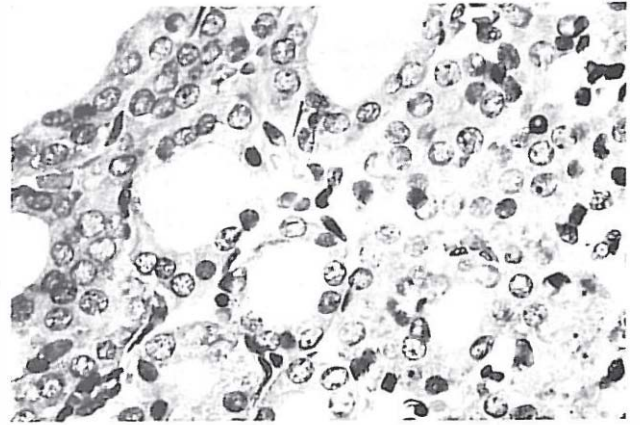


Fig. 4. Microscopic appearance suggesting a well-differentiated follicular carcinoma in a metastatic subcutaneous nodule in case 3 ($\times 400$).

not placed on thyroid hormone treatment. In 1974, at age 81, she was clinically euthyroid with a total T4 of 6.9 $\mu\text{g}/\text{dl}$. On examination, a non-tender 1.5 cm movable nodule was present in the right neck; a 3 cm nodule was easily palpable in the suprasternal area; and some residual thyroid tissue was palpable in the neck bilaterally. Chest x-ray showed a left hilar mass. A whole body ^{131}I scan demonstrated isotope activity in the region of the anterior neck and in the left hilar mass. Cervical exploration and total thyroidectomy showed grade 1 metastatic follicular carcinoma in the left lobe of the thyroid, right neck node and suprasternal notch mass (Figure 4). postoperatively, she was treated with ^{131}I and has been maintained on thyroid hormone suppressive therapy since then. She is clinically well with stable metastatic carcinoma seven years later.

Case 3

A 54-year-old woman was referred for evaluation of neck nodes in 1974. Fourteen years earlier, a right neck lump was noted and she underwent a right subtotal lobectomy. Pathologic examination showed a follicular adenoma with no evidence of malignancy and she received no postoperative treatment. She had no further neck or thyroid problems until shortly before her visit when she noted the appearance of right neck nodules. On examination, she was euthyroid and multiple subcutaneous nodules, measuring 0.5-1.5 cm, were easily palpated in the anterior and right neck. Thyroid gland was normal to palpation. Total T4 was 6.8 $\mu\text{g}/\text{dl}$. A thyroid scan showed uniform uptake throughout a normal-sized thyroid and there was no radioactivity in the palpable subcutaneous nodules. The patient underwent total thyroidectomy and the pathologic examination revealed a normal thyroid gland weighing 35 grams and with no microscopic evidence of malignancy. The neck nodes, however,

showed grade 1 metastatic follicular carcinoma situated in subcutaneous fat. Postoperatively, she was ablated with radioiodine and placed on L-thyroxine. She remains well on suppressive therapy and in a 1981 physical examination a ^{131}I total body scan showed no recurrence of thyroid cancer.

Case 4

A 57-year-old housewife was found to have a left thyroid adenoma during a routine medical examination in 1959. One year later, she underwent a partial left lobectomy and a diagnosis of a follicular adenoma of the thyroid was made. Postoperatively, because of keloid formation, she received several courses of radiation treatment to the left neck area. Twenty years later in 1980, she presented with a nontender and firm 3 cm nodule in the left lobe of the thyroid. A thyroid scan revealed uniform activity in the right lobe and no uptake by the left lobe adenoma. Fine-needle aspiration biopsy of this nodule showed hypercellularity suggestive of a neoplasm. Thyroidectomy disclosed a 4 cm thyroid adenoma in the left lobe of the thyroid containing a grade 1 follicular carcinoma which appeared to be well encapsulated with minimal capsular invasion. The remainder of the thyroid gland was unremarkable. She remains well and free of thyroid cancer on suppressive therapy.

DISCUSSION

Morphologically, follicular adenomas have been classified into six subgroups and are usually successfully differentiated from follicular carcinomas.² Histopathologic criteria used to separate the benign from the malignant lesion include capsular penetration and/or vascular invasion together with cytologic atypia. However, these criteria are far from being perfect since encapsulated angio-invasive follicular carcinoma may not be distinguishable from follicular adenoma and cytologic examination sometimes fails to provide unequivocal evidence of malignancy.

According to Lang and associates,⁷ 30% of all thyroid lesions in patients undergoing surgery are follicular tumors, benign and malignant. In this study of 1,394 follicular neoplasms, 83% were benign, 98% were atypical adenomas, and 3.9% were encapsulated which another 3.9% were widely invasive follicular carcinomas. Lang, et al proposed diagnostic criteria to distinguish encapsulated carcinomas from atypical adenomas.

In the patients presented in this report, the primary tumor in the thyroid was morphologically a benign follicular neoplasm and there was no initial evidence of local spread. In all four patients, pathologic data and

the subsequent clinical presentation of the thyroid malignancy was strongly suggestive of the primary thyroid lesion being an extremely well-differentiated follicular carcinoma impossible to distinguish from an adenoma.

Cases presented here point to the fact that occasionally a well-differentiated follicular thyroid carcinoma cannot be reliably separated from a benign follicular adenoma. The subsequent appearance of a malignant thyroid lesion on the same side of the neck where an original follicular neoplasm was resected and the fact that in all four patients subsequent carcinomas prove to be follicular cancers, lend support to this hypothesis. Even with the apparent malignant behavior of the subsequent lesion, e.g. case 1, a review of the initial thyroid slides failed to exhibit malignant changes. Obviously, there is no reason to conclude that the adenoma is a premalignant lesion, as has been recently suggested.⁷

On the other hand, it may be argued that some subtle evidence of malignancy in the original tissue had escaped detection at the time of the initial pathologic examination. Furthermore, the interval between the initial thyroid surgery and the subsequent appearance of metastatic follicular cancer, 16 years in case 1, may be considered too long for the growth of a well-differentiated thyroid carcinoma.⁸ And finally, it may also be questioned whether the subsequent appearance of cancer represented the spread of the primary neoplasm or indicated the development of a second follicular lesion.

The differentiation of benign from malignant follicular neoplasms may occasionally be very difficult and this represents an infrequent but important pathologic pitfall in thyroid diagnosis. The fact that a review of initial slides in two cases (patient 1 and 2), by experienced pathologists, were interpreted as benign follicular lesions supports this statement. In fact, in case 1, a diagnosis of malignant follicular neoplasm was made by virtue of its metastatic nature rather than microscopic appearance.

In a recent report, Blum, et al⁶ citing the inadequacy of available pathologic criteria for identifying well-differentiated follicular carcinoma, have described four cases similar to the present report. In these patients an erroneous diagnosis of a thyroid adenoma was made. In all patients a review of the initial tumor suggested benign follicular neoplasms. In three patients who later presented with metastatic disease, microscopic appearance of the tumor was identical to the primary tumor but because of the location of the follicular neoplasm, they had to be called carcinoma rather than adenoma.

In conclusion, the need for meticulous gross and microscopic examination of all follicular adenomas

Thyroid Follicular Adenoma

should be emphasized. In the postoperative care of these patients, emphasis must be placed on regular and periodic reassessment. Whether or not life-long postoperative thyroid hormone suppressive therapy, as recommended by Blum, et al⁶ is warranted is difficult to determine at this time. However, since this problem, i.e. differentiation of a benign from malignant follicular neoplasm, is encountered infrequently, there is no justification in performing a total or near-total thyroidectomy in cases where a benign follicular lesion is resected.

REFERENCES

- 1- Meissner WA: Pathology of the Thyroid. In: The Thyroid. Werner SC, Ingbar SH, (Ed.), Harper & Row, Pages 343-463, 1971.
- 2- Meissner WA, Shields W: Tumor of the Thyroid Gland, Atlas of Tumor Pathology, Second Series, Fascicle #4, 1969.
- 3- Ida F: The fate and surgical significance of the thyroid gland. Surg Gynecol Obstet 136:536-540, 1973.
- 4- Outerbridge RE: Malignant adenoma of the thyroid with secondary metastases to bone. Ann Surg 125:282-291, 1947.
- 5- Silverberg SG, Vidone RA: Adenoma and carcinoma of the thyroid. Cancer 19:1053-1062, 1966.
- 6- Blum M, Feiner HD, Worth MH, King LW: Clinical implication of the rare thyroid carcinoma which is indistinguishable from a follicular adenoma. Am J Med Sci 276:99-104, 1978.
- 7- Lang W, Georgii A, Stanch G, Kienzle E. The differentiation of atypical adenomas and encapsulated follicular carcinomas in the thyroid. Virchows Arch 2:125-14, 1980.
8. Young RL, Mazzaferri EL, Rahe AJ, Porfman SG: Pure follicular thyroid carcinoma: Impact of therapy in 214 patients. J Nucl Med 21:733-737, 1980.