

# RENAL INJURIES IN MASHHAD UNIVERSITY DURING THE IRAN-IRAQ WAR. A COMPARISON WITH WORLD WARS I AND II, AND VIETNAM

A. SHAMSA, M.D.

*From the Ghaem Medical Center, Mashhad University of Medical Sciences, Mashhad, Islamic Republic of Iran.*

## ABSTRACT

Missile injuries of the kidney are rare even in wartime. Of 4500 patients admitted to the Ghaem Medical Center in the first two years of the Iran-Iraq war, only 96 had injuries of the genitourinary tract (2.1%) and only 35 involved the kidney usually with multiple injuries to other viscera. The mortality for those with urogenital injuries was 8.3% (compared with World War I, 60% and World War II, 8.3%). The advantage of early helicopter evacuation and prompt forward surgery is once more emphasized. The mean time between wounding and surgery was 48 minutes in this series (compared with 60 minutes in Vietnam and 16 hours in World War II).

*MJIRI, Vol. 4, No.2, 97-101, 1990*

## INTRODUCTION

Penetrating gun-shot injuries of the urinary tract are rare in times of peace, and even in wartime it is seldom that the kidney is injured. This account of experience in a central hospital to which most of the casualties from the fronts in the recent Iran-Iraq war were evacuated may therefore be of interest.

## PATIENTS AND METHODS

During the first 28 months of the Iran-Iraq war, 4500 injured patients were admitted to Mashhad. They had been evacuated from the combat zone by ambulance or helicopter to military or civilian hospitals in the forward area, and were later evacuated by air to Mashhad, where the Ghaem Medical Center offered a full range of medical and surgical departments.

### Early Management

In the forward areas, the management of the injured patient was primarily directed toward saving life. Care of the airway, control of bleeding and resuscitation were the first priorities. Subsequently a more careful history was taken, including details of the site of injury,

the probable type of weapon and the direction taken by the missile. The examination would take into account the presence of injury to the chest wall, a suprapubic

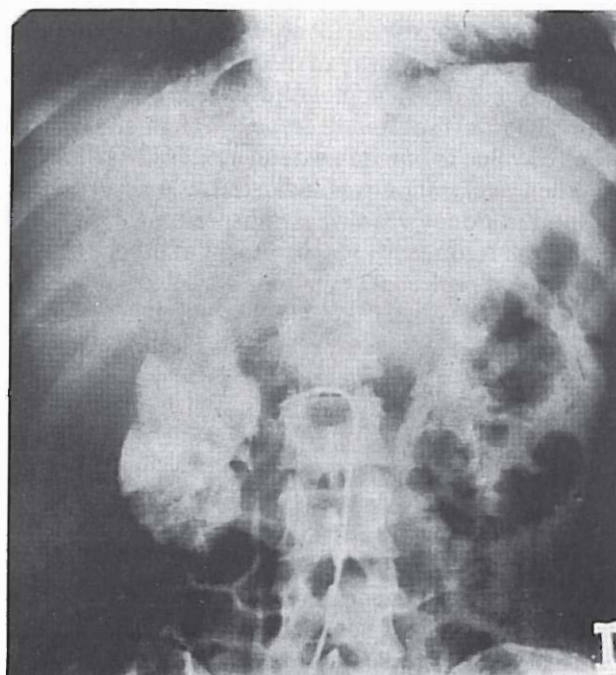


Fig. 1. Angiography in right renal

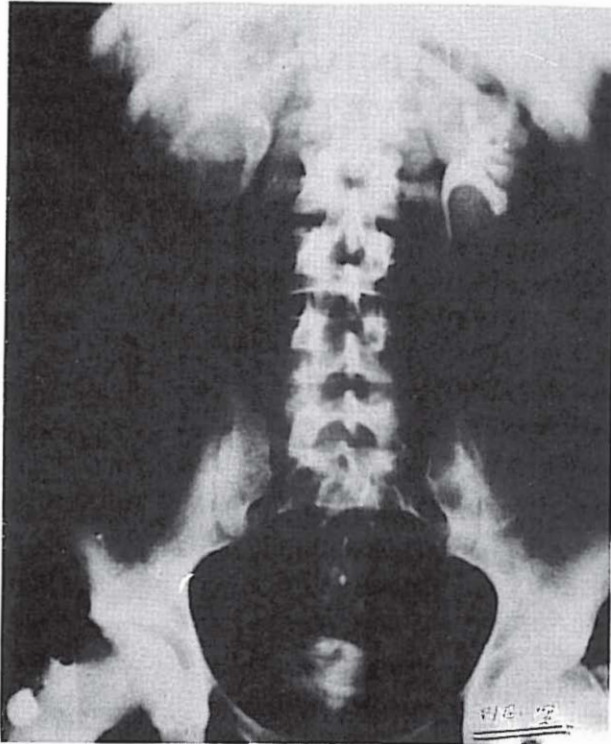


Fig. 2. Shell Fragment and Clot in Left Kidney.

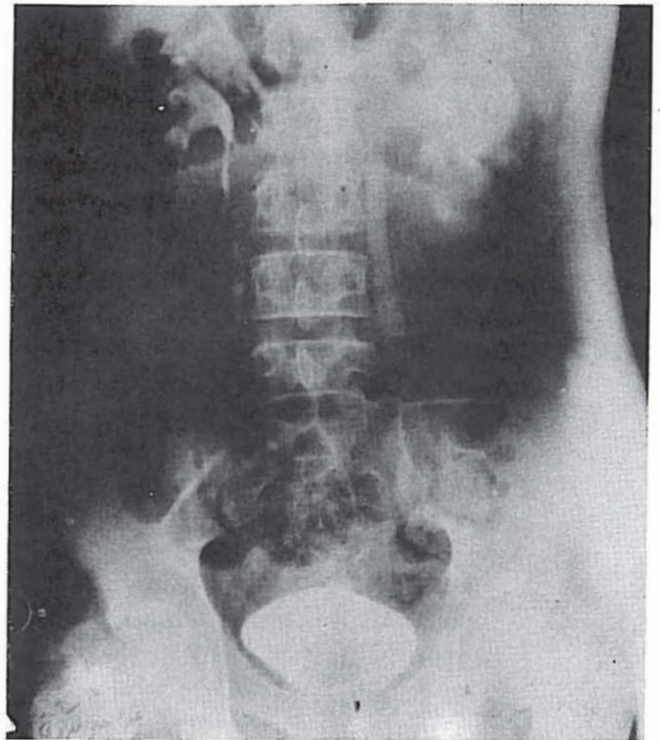


Fig. 3. Extravasation From Left renal area and Hydronephrosis Ureter.

mass, and any swelling in the loin.

In penetrating lower chest and abdominal injuries, a Foley catheter was passed, and if blood was present in the urine, a high dose IVU was obtained as well as chest and plain abdominal radiographs, the priority being to preserve as much renal parenchyma as possible, and in this the first step was to attempt to establish the anatomy and the severity of the injury.

Ultrasonography, angiography (Fig.1) and CT were not available in the forward areas, but angiography was found of value in one stab wound at the base hospital.

When exploration was indicated, the approach to the injured kidney was always transperitoneal, because of the high frequency of involvement of other viscera. Whenever a perirenal hematoma was discovered, the renal artery was first occluded by a vascular clamp or digital pressure before any attempt was made to evacuate the hematoma. Thereafter every attempt was made to preserve as much of the renal parenchyma as possible.

Since all these wounds were contaminated, antibiotics were always given before and after operation: in this series we used gentamicin in combination with ampicillin or cephalothin. After every abdominal exploration the retroperitoneal tissues were always drained. Since there is a high incidence of complications, both early and late, a very careful follow up was instituted.

## RESULTS

Of the 4500 casualties who survived long enough for safe evacuation to our center only 96 (2.1%) had injuries involving the genitourinary tract (Table I). Of these there were only 35 with renal injuries (36%), or 0.7% of all the casualties referred to our department.

### Mortality

There were eight deaths in the 96 patients with urogenital trauma (8.3%) which were confined to those with renal injuries, death being due to the severe associated visceral injuries and renal failure. The mortality among those with renal injuries was eight in 35 (23%).

### Type of missile

Of those with renal injuries due to penetrating wounds from stab or missile injury, the largest number

Table I. Incidence of wounds involving the genitourinary tract.

World War II	Marshall, et.al., 1946	0.67%
	Selikowitz, 1977	2.4%
Vietnam	Busch, et.al., 1967	10%
	Ochsner, et.al., 1969	7%
	Salvatierra, et.al., 1969	4.2%
Civilian	Selikowitz, 1977	3%
	Waterhouse & Gross, 1969	2.5%

**Table II. Incidence of renal injury among all war injuries.**

World War I	Young, 1942	129 in 179,401	0.07 %
World War II	Marshall, 1946		0.7 %
Vietnam	Ochsner, et.al., 1969	27 in 1096	2.4 %
Iran-Iraq war	Shamsa, (present study)	35 in 4500	0.7 %

in this study were caused by shell fragments. This was of clinical importance since if there was a renal injury, there were nearly always multiple injuries to other viscera (Table II). In one patient the contralateral kidney was also injured.

**Complications**

Early complications i.e., occurring within 6 weeks included ileus, secondary haemorrhage and deterioration of renal function ending in renal failure. Later complications included hypertension, hydronephrosis, chronic pyelonephritis, calculus formation, arteriovenous fistula, pseudocyst and renal atrophy (McDougal, 1986).

**Illustrative Case Reports**

The following case reports illustrate some of the problems which were seen during this period:

G.H. Male, aged 27. A renal abscess was diagnosed by IVU and drained successfully.

A.A. Male, aged 17. Liver laceration, perforation of gall bladder, stomach, pancreas and shattered right kidney. There was also a fracture of L2 and L3 vertebrae with paraplegia. Right nephrectomy, renal failure, dialysis, death.

A.T. Male, aged 40. Operated in the forward hospital for penetrating abdominal injury from a shell fragment (Fig. 2). Evacuated to Ghaem because of secondary haematuria. Clot colic, continued bleeding. Haematocrit 23%. Two shell fragments seen in the left renal pelvis surrounded by clot. Exploration revealed multiple lacerations of the left kidney: nephrectomy. Well two years later with normal blood pressure, urinalysis, urea and creatinine.

G.B. Male, 23. Penetrating shell fragment injury. Previous laparotomy for penetrating bullet wound. Entry wound at left lumbar region. Gross blood present in urine from catheter. High dose IVU appeared to

**Table III. Incidence of renal trauma in abdominal injuries.**

World War I	Wallace, 1917	7.5 %
	Lockwood, et.al., (1917)	9.3 %
	Frazer, et.al., 1917	9.6 %
	Walters, et.al., 1917	4.0 %
World War II	Clarke & Leadbetter 1952	5.7 %
Vietnam	Ochsner, et.al., 1969	7 %
Iran-Iraq	Shamsa, (this series)	7 %

**Table IV.**

Viscus	Vietnam	W W II	Iran-Iraq war
	Ochsner, et.al., 1969	Marshall, et.al., 1946	Shamsa 1988
Kidney	27	24	35
Ureter	4	2	5
Bladder	10	7	22
Urethra	9	9	12
Penis	17	18	10
Scrotum/testis	28		16
Total	79	60	96

be normal. After 24 hours, onset of costovertebral angle pain and vomiting. Second IVU now showed extravasation of contrast from the left renal area and hydroureter (Fig. 3). Ureteric catheter passed: fluids forced. After four days, pain relieved. Third IVU showed return of kidney and ureter to normal (Fig. 4).

R.P., Male, aged 21. Civilian, injured in air raid by missile, crush injury and penetrating injury from a shell fragment in the right upper quadrant. Shocked, pale, rigid abdomen. Catheter revealed gross haematuria. IVU showed shell fragment overlying the right kidney which was not functioning. At laparotomy there was massive haemoperitoneum, laceration of the liver and retroperitoneal bleeding. The liver was sutured. On opening the retroperitoneum the right kidney was found to be shattered. Nephrectomy was performed. Uneventful recovery.

W.S.B. age unrecorded. Multiple injuries involving the stomach, small bowel, colon, liver, spleen and both kidneys. Partial nephrectomy was performed to remove the upper pole of one kidney, the other was managed conservatively. Colostomy, resection and anastomosis of the small bowel, splenectomy and repair of the stomach and liver were performed. Uneventful recovery.

**DISCUSSION**

The young soldiers who survived their initial injury to be successfully evacuated to the base hospital represent an unknown but probably relatively small fraction of all those sustaining missile injuries, for in modern warfare it is almost axiomatic that those who survive have been hit with missiles of low velocity-e.g. ricochets and shrapnel. In this experience it was evi-

**Table V. Incidence of associated visceral injuries**

Civilian injuries	Scott, et.al., 1969	GSW	90%
		Stab	56%
Vietnam	Selikowitz, 1977		95%
Iran-Iraq war	Shamsa, (this series)		95-100%

## Renal Injuries in Mashhad University

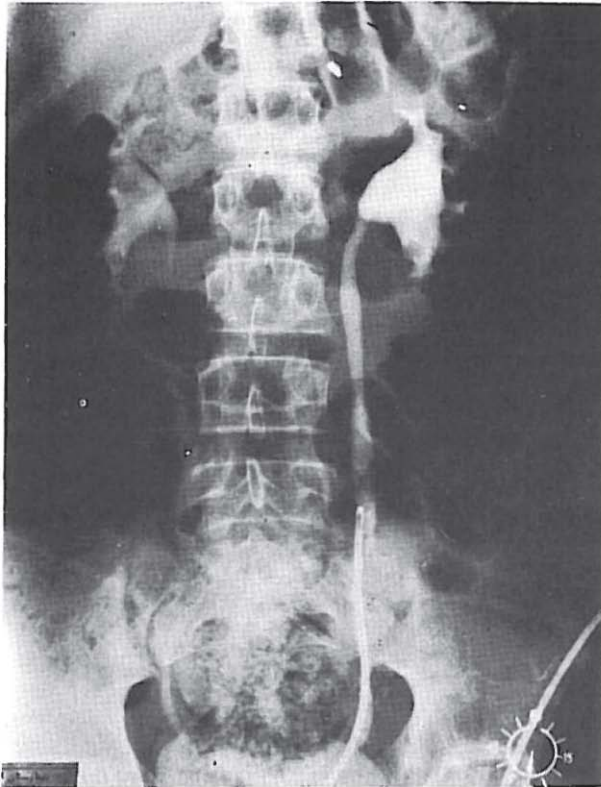


Fig. 4. L. Urterval Catheter Passed, Left Pyelogram Was Normal.

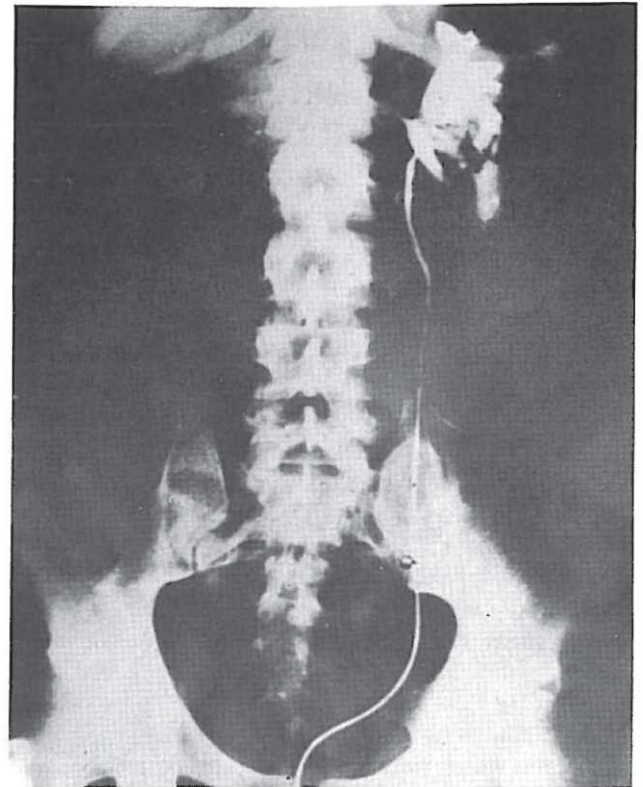


Fig. 5. Left Yetrograde Pyel. Graphy Showed Extravasation.

dent that the major hazard was from shrapnel.

There are many classifications of renal injuries but in all it is accepted that there are major and minor injuries and that minor ones are the most common (65-80%), while major injuries-pedicle injuries, shattered kidney, and perhaps injuries of the renal pelvis-represent a minority. Our experience confirms this view.

In times past the reported incidence of injuries to the genitourinary tract in warfare has varied. Previous authors have reported an incidence between 0.7 to 10% of all injuries (Table I). Among these, injuries to the kidney are relatively rare (Table II) compared with other organs. The kidney has always been relatively immune-perhaps from its well protected anatomical position in the loin. Expressed as a fraction of all abdominal injuries the incidence of renal trauma varies from 5-9.3% (Table III). Even so, the kidney is the part of the urological system which is most likely to suffer damage (Table IV).

Penetrating injuries may be caused by bullets, shrapnel, knife stabs and by iatrogenic factors such as biopsy or surgery. In the Iran-Iraq war the most common cause was shrapnel. These penetrating fragments usually also damage other viscera (Table V), which in order of frequency are liver, small bowel, stomach, colon and spleen (Table VI).

It is rare for both kidneys to be involved in closed

injury, and even more rare in penetrating trauma: three such cases have been reported previously (Escho & Cass, 1972) and one additional case was seen in the present series.

Renal or ureteric injury should always be suspected in any penetrating lower chest or abdominal wound. In the forward areas care of the airway, control of bleeding and transfusion will be the first priorities: later a more careful evaluation is made. When injury to the urinary tract is suspected we always performed urography, even when haematuria was absent, since in penetrating injury haematuria may not be evident in as many as 29% of injuries (Scott & Cariton, 1969). It was also necessary to be aware of the risk that the diuresis caused by the contrast medium may exacerbate fluid depletion and worsen an existing condition of shock (Whitfield, 1985). Impaired renal handling of the contrast medium may cause it to appear in the bowel

Table VI Associated non-renal injuries in penetrating renal injury.

Viscus	Civilian		Military
	Carlton, 1978	Esho & Cass, 1972	Shamsa, 1988
Liver	80	58	16
Small bowel	24	47	9
Stomach	41	45	?
Colon	43	43	?
Splccn	44	28	12

Table VII.

MANAGEMENT	NEPHRECTOMY	DEBRIDEMENT
Vietnam 79 cases: Ochsner, et. al., 1969	35 (55%)	28 (36.5%)
Iran-Iraq 35 cases: Shamsa (present series)	15 (43%)	20 (57%)

and give rise to confusing appearances.

The need for a large dose of contrast medium has been emphasized by Witten, et. al. (1977) who reported that only 64% of renal injuries could be detected with the standard dose in contrast to 91% when a double dose was given. The radiological findings include scoliosis concave to the affected side, absence of the psoas shadow, a foreign body, poor visualization of the affected kidney, and extravasation of contrast. In spite of the fact that the IVU is not 100% reliable in depicting the damage to the injured kidney, it is exceedingly valuable in demonstrating the existence of the contralateral kidney.

In the entire group there were 50 deaths-about 1.1% but among patients with urogenital injuries the mortality was eight in 96 patients (8.3%). Death was caused by severe renal and visceral injuries or renal failure: this mortality should be compared with that in World War I (60%), World War II (8.3%) (Marshall, 1946) and Vietnam (Table VII).

This experience from the Iran-Iraq war reinforces experience gained in previous engagements, that the more forward the provision of the surgical services, the better the results. Our results bear out the advantage of early evacuation by helicopter to field surgical hospital as near the combat zone as possible; the mean time between wounding and surgery has progressively diminished from 16 hours in World War II (Busch, et. al, 1967) and 60 minutes in Vietnam (Ochsner, et. al., 1969) to only 48 minutes in the Iran-Iraq conflict.

Table VIII. Other viscera injured at the time of renal injury

Liver	16
Small bowel	9
Spleen	12
(Some cases with injury of stomach and colon were not recorded)	
Total	37
<i>(In many cases more than one other viscus was injured)</i>	

## ACKNOWLEDGEMENTS

I wish to express my best and highest regards to my teacher, Professor John P. Blandy. This paper was written with his kind help, encouragement and editorship.

I also wish to thank all medical staff who dealt with operations and looked after the injured patients in this series.

## REFERENCES

1. Busch FM, Chenault OW, Zinner NR, Clarke BG: Urological aspects of Vietnam war injuries. *J Urol* 97: 763-5, 1967.
2. Carlton CE: Injuries of the kidney and ureter. In: Campbell's Urology. Harrison, et al (eds) 4th ed, Philadelphia, W B Saunders, Vol. 1: pp 881-905, 1978.
3. Clarke RG, Leadbetter WF: Management of wounds and injuries of genitourinary tract: a review of reported experience in World War II. *J Urol* 67: 719-739, 1952.
4. Esho JO, Cass AS: Bilateral renal injury: Case report *J Urol* 108: 955-6, 1972.
5. Frazer J, Drummond H: 300 perforating wounds of the abdomen. *Br. Med. J* 1:321-330, 1917.
6. Lockwood AL, Kennedy CM, MacFie RB, Charles S F A: Observations on treatment of gunshot wounds of abdomen with a summary of 500 cases seen in an advanced casualty clearing station. *Br Med J* 1: 317-320, 1917.
7. Marshall DF: Urogenital wounds in an evacuation. *J Urol* 55, 119-132, 1946.
8. McDougal, WS: Traumatic injuries of the kidney. In *Atlas of General Surgery*. Dudley H, Carter DC, Russell R C G, (Eds), London. Butterworth. pp 746-55, 1986.
9. Ochsner TG, Busch FM, Clarke BR: Urogenital wounds in Vietnam. *J Urol* 101: 224-5, 1969.
10. Salvatierra O, Rigdon WO, Norris DM, Brady TW: Vietnam experience with 252 urological war injuries. *J Urol* 101: 615-62, 1969.
11. Scott R, Carlton CE Jr, Goldman M: Penetrating injuries of the kidney. *J Urol* 101: 247-55, 1969.
12. Selikowitz SM: Penetrating high velocity genitourinary injuries. *Urology*. 9: 371-6, 1977.
13. Wallace C: A study of 1200 gunshot wounds in the abdomen. *Br J Surg* 4: 679-744, 1917.
14. Waterhouse K, Gross M: Trauma to the genitourinary tract. *J Urol* 101: 241-6, 1969.
15. Walters C, Rollinson HD, Jordan AR, Gray BA, with preparatory note by Sir Anthony Bowlby: series of 500 emergency operations for abdomen wounds. *Lancet* 1: 207-213, 1917.
16. Whitfield H N: Renal injuries. In: *Textbook of Genitourinary Surgery*. Whitfield H N, Hendry W F (Eds), London, Churchill-Livingstone, vol.2, pp. 843-8. 1985.
17. Witten D, Myers GH, Utz DC: Trauma to the urinary system. In: *Emmett's Clinical Urography*, 4th ed, Witten D, Myers GH, Utz DC, (eds). Philadelphia. W B Saunders Co, pp 1768-1840, 1977.
18. Young HH: Wounds of urogenital tract in modern warfare. *J Urol* 47:59-108, 1942.