

THE CLINICAL APPLICATION OF PREFABRICATED FREE FLAPS FOR NASAL RECONSTRUCTION

AHMAD MOGHARI, M.D., K.S. FOROOTAN, M.D.,
S.A. EMAMI, M.D.

*From the Department of Hand and Reconstructive Microsurgery, Hazrate Fatimah Hospital, Iran University of
Medical Sciences, Tehran, Islamic Republic of Iran.*

ABSTRACT

We have found prefabrication of hairless radial forearm free flap to be a useful technique for nasal reconstruction. Prior skin grafting and a suitable period of maturation permits safe, reliable surgery. Its use should be considered in those patients whose forehead tissue is not suitable or in whom appropriate distant flaps are not available, as is often the case with hirsute males.

MJIRI, Vol.4, No.1, 5-8, 1990

INTRODUCTION

There are instances in plastic surgery where flap tissue may not be ideally suited for its proposed reconstructive goal. In such circumstances secondary modifications may be required. Such procedures are commonly performed following a "maturation" period at the recipient site.

An alternative approach is to modify the structure of the flap prior to its transfer, a procedure referred to as prefabrication. This would have its main application in situations where secondary modification would be difficult or where the results would be generally unsatisfactory. We have found such an approach useful in nasal reconstruction where local tissues have been destroyed by the original injury and where suitable distant flaps are not available. Presented are three cases of nasal reconstruction using prefabricated modifications of the radial forearm free flap.

Address for correspondence

A. Moghari M.D.
Chairman of the Department of Hand and Reconstructive
Microsurgery, Hazrat Fatimah Hospital, Iran University of Medical
Science, Asad Abadi Ave. Tehran 14339, IRAN

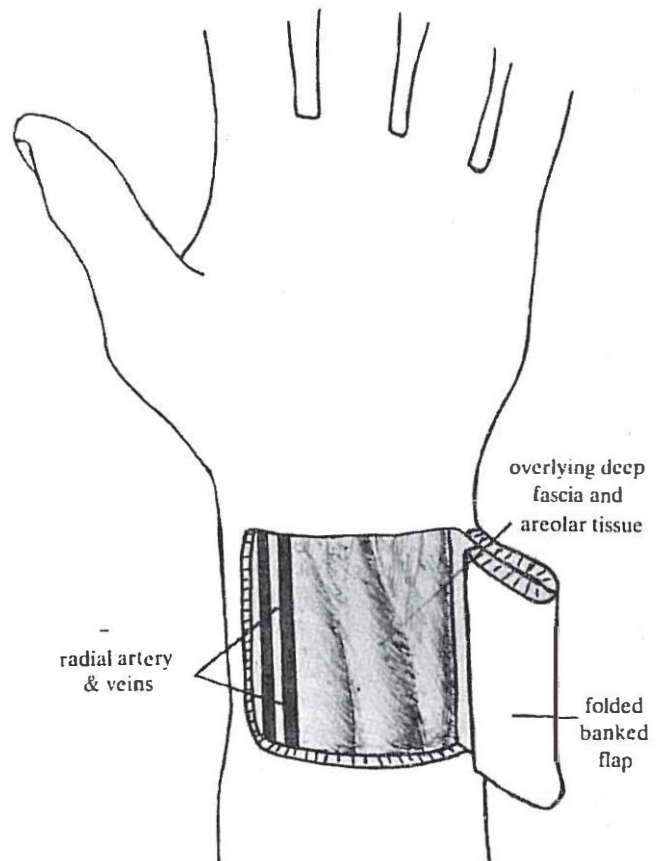


Fig. 1. The random elevated forearm leaving subcutaneous tissue.

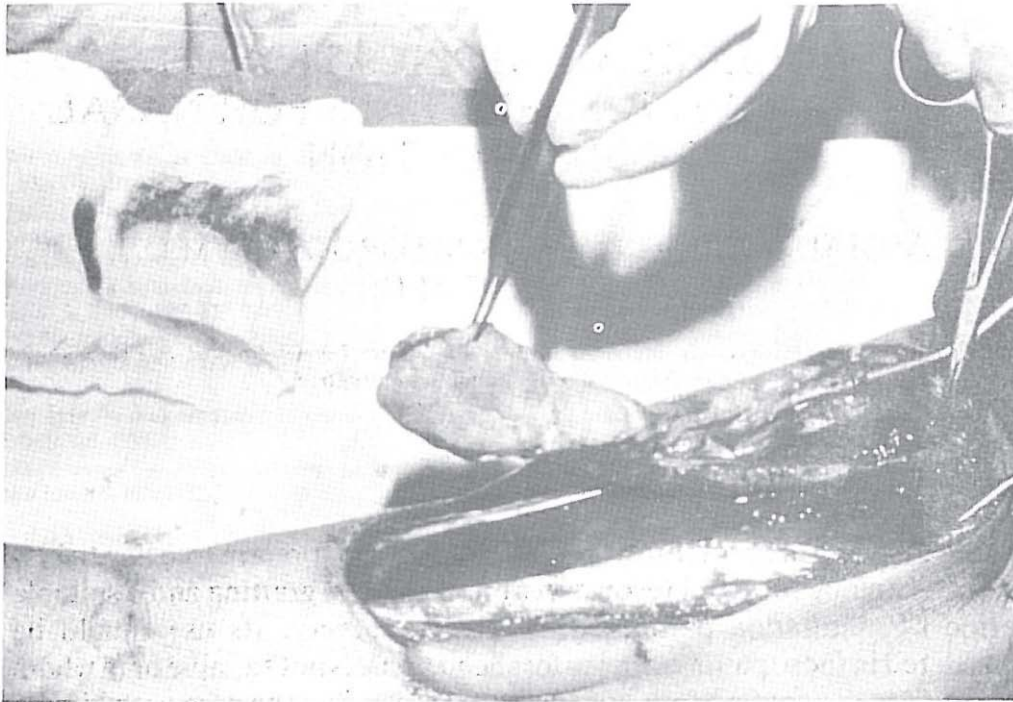


Fig. 2. Elevated fascial flap.

METHODS

Operative Technique

The operation commences with the elevation of a random pattern suprafascial flap of skin and subcutaneous tissue from the volar surface of the distal forearm based on the ulnar border.¹ Care is taken to preserve the areolar tissue overlying the deep fascia.² This flap is folded on itself and banked for future closure of the forearm (Fig.1).

Full thickness skin grafts are harvested from behind one or both ears, depending on the skin requirements. These are grafted to the exposed forearm fascia. Following an incubation period of six to 10 weeks, the radial artery free flap is elevated (Fig. 2) and transferred either as grafted fascial flaps or as grafted osteo-fascial flap incorporating a segment of radius, if bone is required in the reconstruction.

This technique has been used in three cases of nasal reconstruction in patients who have sustained concomitant injury to the forehead (Table I). In all cases the prefabricated flaps have been transferred without incident. Two patients were satisfied with the result. However, the patient who underwent total nasal reconstruction with the grafted osteo-fascial flap will require secondary thinning of the retained portion of flexor pollicis longus muscle.

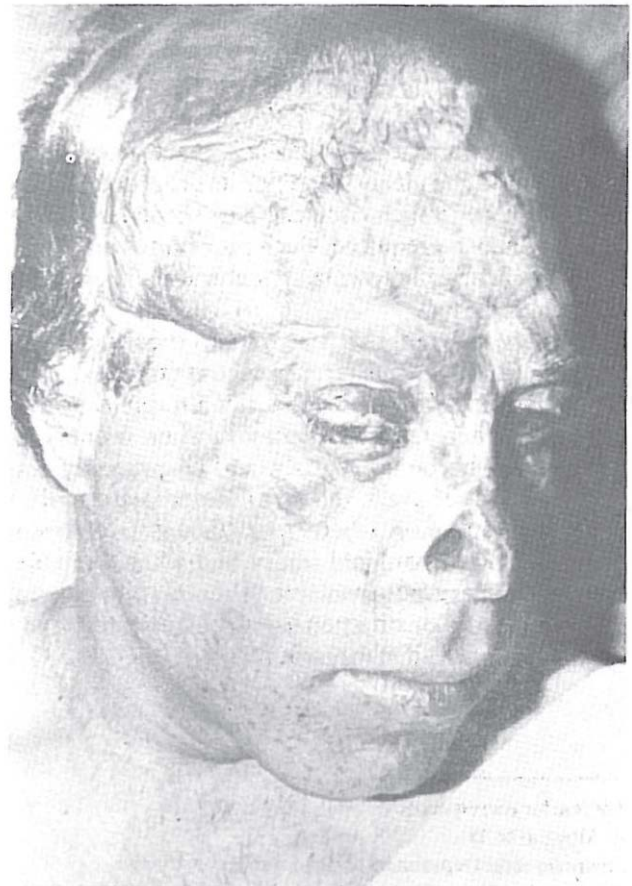

Fig. 3. Patient 1 pre-operatively.

Prefabricated Free Flaps For Nasal Reconstruction



Fig. 4. Patient 1 post-operatively. Note the hairy donor forearm.

A 37-year-old man suffering from post-craniotomy epilepsy sustained full thickness burns to his scalp, forehead, eyelids and nose. An initial attempt to resurface his scalp with a free omental flap was unsuccessful. Subsequently the scalp was reconstructed with a skin grafted latissimus dorsi free flap (Fig. 3). Two years later, reconstruction of the right heminose was performed with a prefabricated grafted radial forearm fascial free flap which was revascularised by an end-to-side anastomosis to the external carotid artery and external jugular vein. The flap was infolded at the alar margin for simultaneous reconstruction of nasal lining. At 18 months follow-up revealed that the flap remained

Table I. Summary of the Clinical Cases

Case	Etiology	Reconstruction	Flap
1	Facial burns	Heminose	Skin grafted fascial
2	Gunshot wounds	Heminose	Skin grafted fascial
3	Gunshot wounds	Whole nose	Skin grafted osteofascial

well healed (Fig. 4). However, the patient would benefit from debulking of the flap and scar revision to eliminate webbing at the alar fold (Fig.4).

DISCUSSION

These cases demonstrate the clinical feasibility of prefabricating free flaps prior of their transfer. However such a concept is not new. In 1980, Orticochea prefabricated axial pattern island flaps from the auricular conchae by transposing the superficial temporal vessels to the postauricular area.³ Following a period of maturation, these island flaps were transferred for reconstruction of the lower two-thirds of the nose. In 1985, Moore, et al. performed skin graft using a radial forearm fascial flap several weeks prior to transfer for intraoral reconstruction, thereby avoiding the introduction of hairy skin inside the mouth.⁴

In our cases an alternative method of reconstruction would have been to skin graft the forearm flaps at the recipient site, thereby completing the reconstruction in one stage. However, the flimsy fascia is awkward to work with, and it would be difficult to fold to recreate an adequate alar margin. Preliminary skin grafting imparts a degree of rigidity making sculpturing easier and it also helps counteract the effects of gravity. The mature skin graft also provides a satisfactory monitor for patency of the microvascular anastomoses. An incubation period of six to 10 weeks allows softening of the tissues prior to transfer.

ACKNOWLEDGEMENTS

The authors would like to thank Dr. D. Maleckniazi, Head of the Department of Legal Medicine of Iran, for his kind scientific cooperations.

REFERENCES

1. Chang Di Sheng: radial artery fascial flap. Presented at the Annual Meeting of the American Society of Plastic & Reconstructive Surgery, Honolulu, Hawaii October, 1982.
2. Moore: Personal discussion. How to prevent complications. Papers - 76-301-302 -1985, Jan. 15th, 1989.
3. Muhlbaur W, Hernadl E, Stock W: The forearm flap. Plastic & Reconstr Surg 70: 336-344, 1982.
4. Orticochea M: Refined technique for reconstructing the whole nose with the conchas of the ears. Brit Plastic Surg 33: 38, 1980.