

## ARTILLERY SHELL FRAGMENTS IN THE HEART: DIAGNOSIS AND MANAGEMENT

M.A. SADR-AMELI, M.D., M. MOHAJERI, M.D. AND A. MOHEBI,  
M.D.

*From the Shahid Rajai Heart Hospital, Iran University of Medical Sciences, Tehran, Islamic Republic of Iran.*

### ABSTRACT

Delayed evaluation and management of penetrating cardiac injuries especially mortar fragments were performed in 30 war victims in the Shahid Rajai Heart Hospital, Tehran. All were men with a mean age of 20.7 years. Pleuritic chest pain was the most common symptom (53.3%), while physical examination was negative in the majority of cases (66.8%). 50 percent of the cases had pericardial effusion on the echocardiogram. The right ventricle was the most frequent site of involvement (26.6%) followed by the left ventricle (16.6%), right atrium, left atrium, aorta (each 13.3%), pulmonary trunk (10%), and inferior surface of the heart (6.6%). More than half of the cases had associated hemothorax. Shell fragments were removed in all cases but two. Fragments larger than one centimeter in the vicinity of the heart structures in the pericardium are recommended to be removed.

*MJIRI, Vol.3, No.3 & 4, 109-112, 1989*

### INTRODUCTION

Penetrating injuries of the heart (pericardium and cardiac structures) have always been an unusual problem confronting the surgeons and cardiologists involved with these cases. The literature show the infrequent incidence of cardiac involvement in thoracic penetrating trauma during war with improving survival rates.<sup>1,2</sup> Delayed evaluation and management of patients with artillery shell fragments in the heart were not fully examined. We studied 30 war victims after stabilization by catheterization and angiography. Most of them underwent operation. The clinical, paraclinical, as well as surgical data are reported.

### MATERIAL AND METHODS

Thirty young men aged 17 to 34 years old (mean 20.7) were admitted to our hospital because of mortar shell fragments in the heart. The mean interval between the time of injury (in the fronts) and

their second hospitalization was five days (range three-12 days). Pleuritic chest pain was the most common symptom, occurring in 16 cases (53.3%) followed by dyspnea in 11 cases (36.7%) and no complaint in the remaining 3 (10%). On physical examination, 20 cases (66.8%) showed no abnormal cardiac findings. Pericardial friction rub was present in 8 (26.6%), mitral regurgitation (MR) in one (3.3%), and continuous murmur in supraclavicular fossa in another case (3.3%). More than half of the cases had a chest tube because of hemothorax, 11 in the left and five in the right side at the time of hospitalization. ECG was normal in 26 cases (86.6%) and the remaining four showed ST-T changes. In chest X-ray, no abnormality except increased cardiothoracic ratio in six cases (20%) was detected. Shell fragments were seen every where within the cardiac silhouette (the most common site was the anterior of the right ventricle).

Echocardiogram showed pericardial effusion in nearly half of the cases (50%) and one patient showed left ventricular volume overload (due to MR). Fluoroscopy in different views was performed

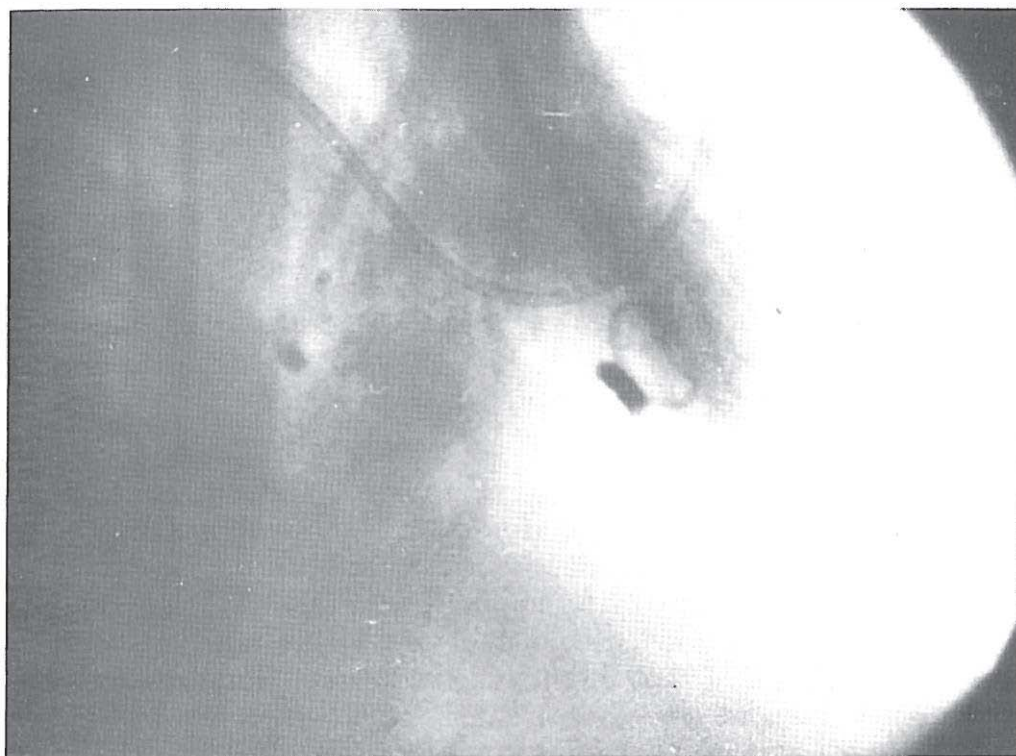

Fig. 1. Left ventricular angiography in right anterior oblique view shows the fragment in the right ventricle.

in all patients to differentiate those with fragments in the pericardium from those with a superimposed shadow on the cardiac silhouette (extracardiac). Catheterization and angiography were done on all patients. The site of shell fragments (all cases were inside the pericardium on or within cardiac structures) were anterior aspect of RV (eight cases), lateral wall of LV (three cases), posterior part of LV (two cases), right atrium (four cases), left atrium (four cases), anterior part of ascending aorta (three cases), left aspect of ascending aorta (one case), main pulmonary trunk (three cases), and inferior surface of the heart (two cases). In three cases the findings of angiography (fragment site) were different from fluoroscopy. One patient showed two plus mitral regurgitation due to chordal laceration and a subclavian arterio-venous fistula was detected in another patient. Coronary angiography was done in all patients and no abnormality was demonstrated.

Fragments in all patients except two (which were less than 1cm) were removed by open thoracotomy with no complication.

## DISCUSSION

The chest wall offers little protection to the heart from projectile wounds. These wounds may produce a variety of cardiac lesions including penetrating wounds

of the pericardium, cardiac wall, interventricular septum, perforating or lacerating wounds of the cardiac valves, chordae tendineae, or papillary muscle; and coronary vessels. During battle the wounding agents in most of the cases are shell fragments and Flechette<sup>1,2</sup> (the Flechette is a small dart like missile which has a great penetrating ability due to its light weight, shape with sharp angles, and great velocity). These wounds are most frequently associated with penetrating wounds of the pericardium, although they may also occur in patients with penetrating wounds of the chest, neck, and upper abdomen. The area of exposure of the anterior chest wall of each cardiac chamber and the intrapericardial great vessels differs markedly (55 percent of the anterior surface is comprised of RV, 20 percent LV, 10 percent RA, 10 percent great vessels, and 5 percent vena cava<sup>5</sup>). In our cases there was similar sites of involvement.<sup>5</sup> The difference between angiography and fluoroscopy data in three patients could be due to displacement of the fragment or inaccuracy of the latter in comparison to angiography. Projectile injuries carry a very serious outlook, and perhaps only 10 to 20 percent of these individuals will fall into a salvageable category. The experience in Vietnam demonstrated that only patients with relatively small wounds survive long enough to reach a hospital, while those with more serious cardiac wounds which produce exsanguination and shock rarely survive to reach a medical center and when they do, are usually

## Artillery Shell Fragments In Heart

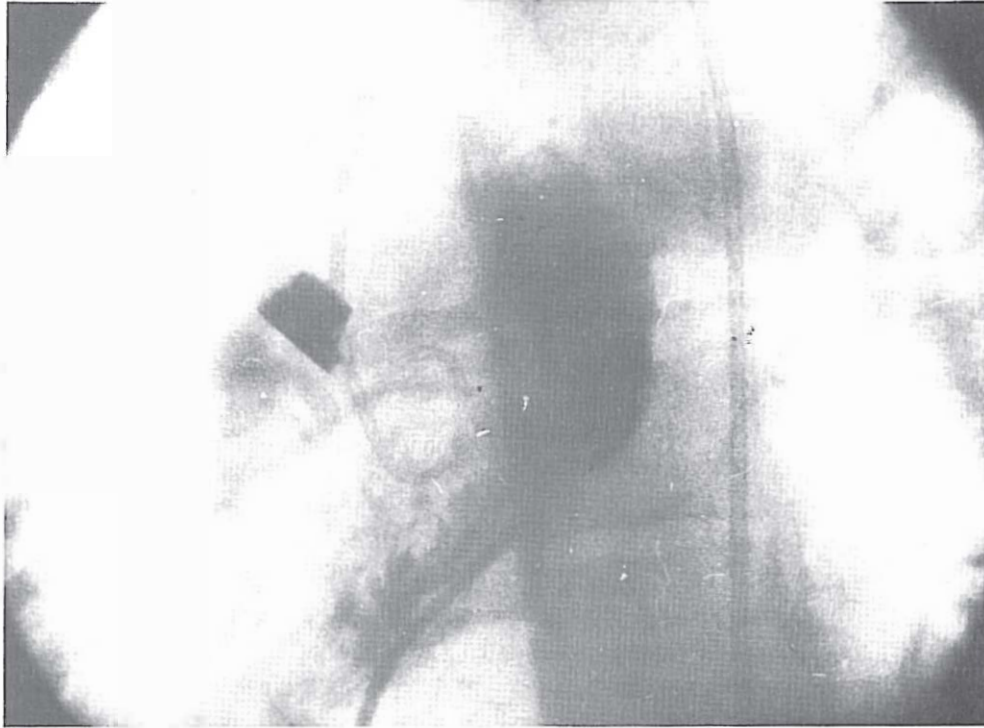


Fig. 2. Left ventricular angiography in left anterior oblique view shows a large fragment in the right atrium.

not successfully treated.<sup>4</sup> Lacerating or penetrating wounds frequently result in immediate hemorrhage of varying magnitude. The severity of the hemorrhage and whether it is intra- or extrapericardial determine the clinical picture and dictate the requirement of therapy. Where there is intrapericardial hemorrhage with a sealed pericardial wound, cardiac tamponade is the major threat;<sup>6</sup> whereas when the pericardial wound is open and bleeding occurs freely into the pleural space, loss of circulating blood volume is the major danger. All of our patients were in a relatively stable situation at the time of admittance due to an average lag interval of five days from injury at the front. That is why we call it "delayed evaluation." The treatment of these lesions, when they are manifested with massive and or continuous intrapericardial hemorrhage, is immediate surgical repair which appears to be the treatment of choice for all penetrating cardiac wounds. Pericardiocentesis should be used in patients with cardiac tamponade only to provide time for a safe operation. Pericardiocentesis as a mode of treatment is not accepted because in most cases thoracotomy reaches a pericardium filled with large clots which renders pericardiocentesis ineffective and continued bleeding is a common finding after initial pericardial aspiration.

Residual or delayed sequelae of penetrating wounds of the heart include structural defects such as a ventricular or atrial septal defect; aorta or coronary

artery to cardiac chamber fistula; aorta to pulmonary artery communications; atrioventricular defects; laceration of valve leaflets or chordae tendineae; and ventricular aneurysm.<sup>7</sup> The complications of infection, pericarditis, embolization and dysrhythmias may also occur. Recurrent post-traumatic pericarditis complicates about 20 percent of all cases of penetrating heart wounds and is similar to post-pericardiotomy syndrome. Symptomatic management is recommended unless other sequelae such as purulent or constrictive pericarditis develop which need surgical intervention. Coronary artery injuries, depending upon the size of the injured vessel, can result in cardiac tamponade and varying degrees of myocardial ischemia or myocardial infarction. Penetrating wounds may result in the retention of a projectile within the heart. Embolization of such a foreign body, or of the thrombus associated with it, has occurred.<sup>8</sup> The possibility of bacterial endocarditis is also present if the projectile is not completely embedded in the myocardium. Several patients with intracardiac projectiles have developed cardiac neurosis with an almost maniacal desire for removal of the foreign body. A penetrating wound of the great vessels may result in the formation of a false aneurysm, with possible subsequent rupture, or of an arteriovenous fistula, producing either immediate or latent signs and symptoms of congestive heart failure.<sup>9</sup> These possible complications suggest that after precise angiographic localization, elective extraction may be the preferred

management of such projectiles in the heart. Extensive military experiences suggest that any foreign body in the thorax larger than 1.5<sup>cm</sup> in size should be removed due to possible late complications. Objects even smaller than this may be removed if they lie against the heart and great vessels where they may cause major damage by erosion.<sup>4</sup> The treatment of choice is open thoracotomy which allows effective control of hemorrhage, relief of tamponade and removal of fragments where possible.<sup>2,3</sup>

In our cases all the fragments larger than one centimeter were removed. In two cases because of multiple small fragments (less than 0.5<sup>cm</sup>), operation was not carried out.

## REFERENCES

1. Gielchinsky I, Lieutenant C, Mc Namara J: Cardiac wounds at a military evacuation hospital in Vietn experience, *J Thorac Cardio-Vasc Surg* 60: 603, 1969.
2. Zakharia AT: Cardiovascular and thoracic injuries in the Lebanon war; Analysis at 3000 personal cases. *J Thorac Cardiovasc Surg* 89: 723-733, 1985.
3. Estrera A S, Schreiber J T: Management of acute cardiac trauma, *Cardiol Clin* 2: 239, 1984.
4. Webb W R: Thoracic trauma. *Surg Clin N Amer*, Philadelphia, W.B. Saunders, 54:1179, 1974.
5. Symbas P N: Trauma to the heart and great vessels. Grune and Stratton, Inc., New York, 1978.
6. Isaacs J P: Sixty penetrating wounds of the heart, *Surgery* 45: 696, 1959.
7. Symbas P N, Di Orio D A, Tyras D M, et al: Penetrating cardiac wounds: significant residual and delayed sequelae. *J Thorac Cardiovasc Surg* 66: 526, 1973.
8. Bland E F, Beebe G W: Missiles in the heart: A 20 year follow-up report of world war cases. *N Engl J Med* 274: 1039, 1966.
9. Symbas P N, Schlant R C, Logan W D, et al: Traumatic a-orticopulmonary fistula. *Ann Surg* 165: 614, 1976.