

PROGRESSIVE NEUROLOGICAL DEFICIT DUE TO NEGLECTED DURAL REPAIR IN WAR CASUALTIES

MAZIAR AZAR, M.D.

From the Department of Neurosurgery, Amirmomenin Hospital, Iran University of Medical Sciences, Tehran, Islamic Republic of Iran.

ABSTRACT

One hundred patients underwent elective cranioplasty for high velocity missile injury of the head during a 30-month-period study and investigation in Amirmomenin Hospital affiliated to Iran University of Medical Sciences.

Deep penetrating wounds were the most frequent injuries seen during this study. Three patients presented with massive bone defects and progressive neurological deficit and during the operation it was noted that dural repair had not been done. It was suggested that intermittent brain herniation was the probable cause of progressive brain damage.

MJIRI, Vol.3, No.3 & 4, 125-128, 1989

INTRODUCTION

Skull bone defects are thought to be one of the main causes of morbidity among patients with missile injury of the head.

The majority of patients are stable, and progressively gain ordinary function after the first operation.

MATERIALS AND METHODS

One hundred patients were admitted to the Amirmomenin Hospital for elective cranioplasty. The average time between the primary debridement and admission was about 10 months. Among these patients there were three cases presenting with progressive neurological deficit in whom debridement had been performed about four years previously.

CASE REPORTS

Case 1

A 39-year-old housewife was admitted for progressive neurological deficit due to bomb shell fragment injury in the left temporoparietal area which occurred on 10/6/85.

She had immediately become unconscious for 25

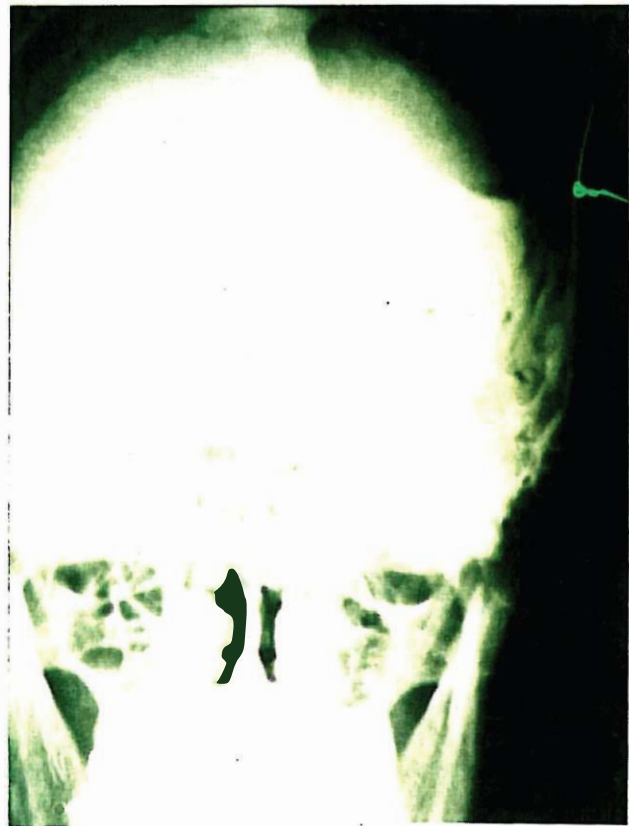


Fig. 1. Skull bone defect

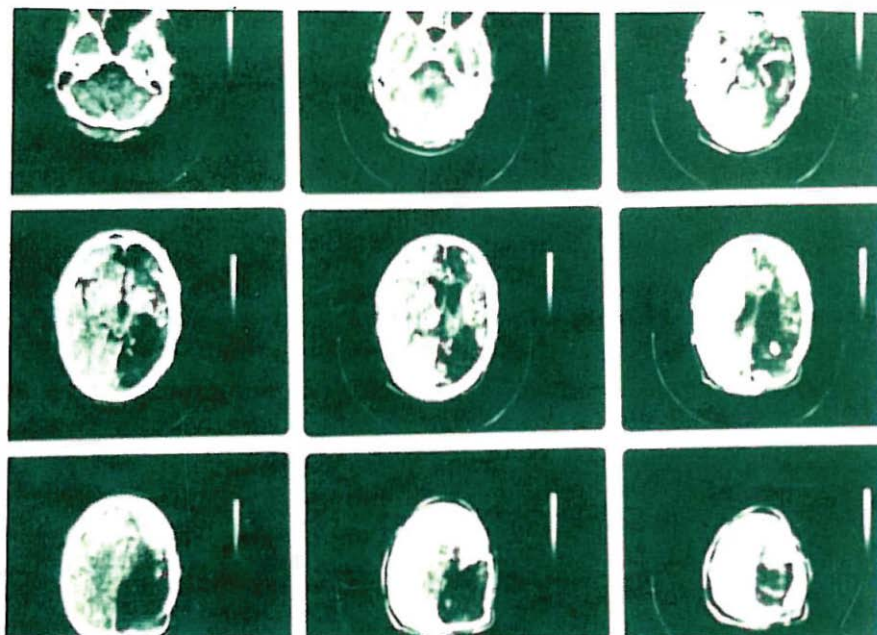


Fig. 2. C.A.T. Scan show massive brain herniation

days. According to the history given by her daughter, after the first operation she had voluntary movement for about two months in her right side, but progressively lost her motor function and became totally hemiplegic and aphasic due to intermittent brain herniation in the bone-defect area (Figs. 1 and 2). At operation it was found that the skin was adherent to the brain cortex. Dural repair was performed by using precranium, and methyl acrylic cranioplasty was done. After a four-month follow up period her condition is stable and satisfactory.

Case 2

A 28-year-old soldier was admitted for cranioplasty and progressive right side palsy and intermittent bulging on the side of previous operation. C.T. scans showed brain herniation in the left temporoparietal area and loss of left hemisphere. He had a history of direct bullet injury on 1/2/86 in the war fronts and debridement had been performed in a front line hospital. At the cranioplasty performed 4 years later we found that the dural defect had not been repaired and herniated brain could be seen in the subcutaneous area.

Case 3

A 22-year-old male had a deep penetrating injury of the right parietotemporal area due to shell fragment injury in the war fronts. At the time of admission four years after the injury he had severe left side palsy and was epileptic. According to the history that was given, his neurological status had been stable, until five months after the operation at which time his condition

progressively worsened. During the operation it was found that dural repair had not been done and brain was adherent to the subcutaneous tissue and pulsations had led to intermittent herniation (Figs. 3 and 4).

Surgical Exploration

The operation was performed in a routine fashion. None of the patients had pulped brain but in all three cases the brain could be felt under the subcutaneous tissue, and after rotating the skin flap necrotic brain tissue was exposed. To reach the normal dura we had to perform a craniectomy all around the defect. Dural graft was performed using fascia lata and temporalis fascia in a water-tight fashion and cranioplasty was performed subsequently (details of the new technique of cranioplasty with methacrylate were presented in the First Trauma Symposium at the Kerman University of Medical Sciences); Post-operative follow up for three to four months showed no more problems or complaints and the neurological status was stable.

DISCUSSION

The Korean, Vietnam, and Middle-East wartime experiences with cranial high-velocity missile fragment wounds have revealed low incidence of post-operative brain herniation, C.S.F. leakage, and infection after watertight dural repair in which pericranial or fascial grafts have been done and also by reestablishing a normal anatomical relationship.

It may be possible to reduce cortical meningeal scar

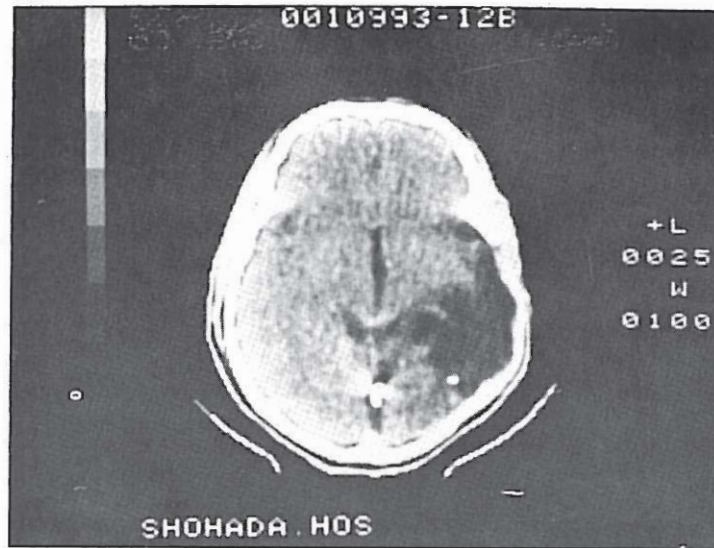


Figure 3.

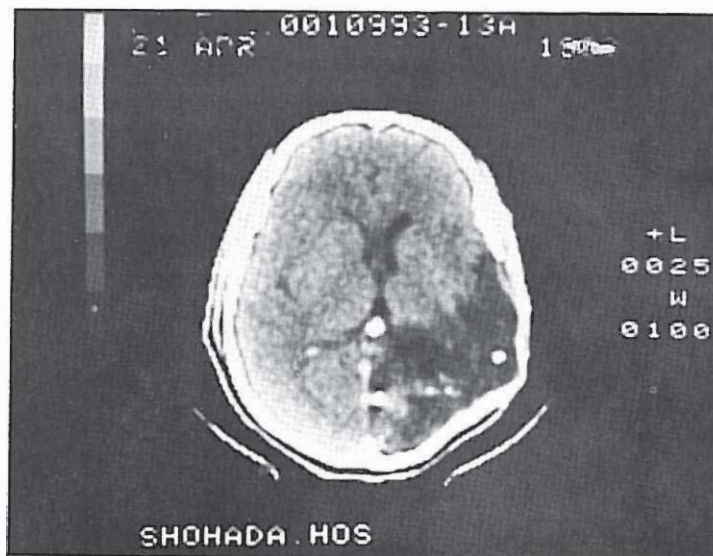


Figure 4.

Fig.3,4. Brain loss due to skull bone defect

formation and potential post traumatic epilepsy, and also further cranioplasty can be facilitated by a satisfactory plane of cleavage.

Although some neurosurgeons do not insist on complete dural closure and leave it open, in our opinion in the missile penetrating wounds, complete dural closure is strongly recommended.

REFERENCES

1. Wallace PB Meierowsky AM: The repair of dural defect by graft. *Ann Surg* Vol: 15, 1960.
2. Meierowsky AM: Harsh GR: The surgical management of cerebritis complicating penetrating wounds of the brain. *J Neurosurg* Vol: 10, 1953.
3. Jefferson A, Reilly G: Fractures of the floor of the anterior cranial fossa. The selection of patients for dural repair. *Br J. Surg* V: 59, 1972.
4. Hammon WM: Analysis of 2187 consecutive penetrating wounds of the brain from Vietnam. *J Neurosurg* V: 34-1971.
5. Hammon WM: Missile wound. *Handbook of Clinical Neurology*. V: 23, Amsterdam: Elsevier, 1975.
6. Broakman R: Depressed skull fracture: data, treatment and follow up of 255 consecutive cases. *J Neurol Neurosurg Psych* Vol: 35, 1972.
7. Fuad AA, Haddad S: Nature and management of penetrating head injuries during the civil war in Lebanon. *Can J Surg* v: 21, 1978.

8. Hagens H: Early complication of following penetrating wounds of the brain. *J Neurosurg* V: 34, 1921.
9. Aarabi B: Traumatic aneurysms of brain due to high velocity missile head wounds. *Neurosurgery* V: 22, 1988.
10. Aarabi B: Comparative study of bacteriological contamination between primary and secondary exploration of missile head wounds. *Neurosurgery* 20 (4): 610-6, 1987.
11. Koufman HH, Sadhu VK, Clifton GL, Hanel SE: Delayed intracerebral hematoma due to traumatic aneurysm caused by a shotgun wound. *Neurosurgery* V: 6, 1980.
12. Tabaddor K, LaMorgese J: Complications of a large cranial defect: case report. *J Neurosurg* 44: 506-8, 1976.