

Abdominal tuberculosis presenting with peritonitis and enteroliths: report of a rare case and literature review

Jalaluddin Khoshnevis¹, Niki Tadayon², Arash Najaf Beygi³

Department of Vascular & Trauma Surgery, Shahid Beheshti University of Medical Sciences. Tehran, Iran.

Received: 28 December 2008

Revised: 7 July 2010

Accepted: 17 July 2010

Abstract

We are presenting a case of abdominal tuberculosis who had peritonitis and two large enteroliths were removed from the small intestine during laparotomy. Following a full course of medical treatment, she developed small bowel obstruction and treated by laparotomy & enterolysis but showed no evidence of stricture. We had a diagnostic and management challenge which will be discussed along with a review of the literature.

Keywords: abdominal tuberculosis, stricture, enterolith.

Introduction

Abdominal tuberculosis may simulate various diseases and is associated with some diagnostic and therapeutic challenges [1,2,4,8,11,12,13].

It may resemble peritonitis [1,2,4], small or large bowel obstruction [1,4,6,8,11,12,13], or present as an abdominal mass [1,4,8] or ascites.

Enterolith is a rare phenomenon encountered on abdominal X-Ray and usually is not the cause of the stricture seen simultaneously. [1,3,6,9,11,12,13]. Perforation and fistulae are other complications which occur in 6-15% of cases [1,4,6].

Calcification of Lymph nodes or the omentum may be seen on X-Ray but with a lower incidence (1.5%) [1]. All of these, per se or together, can make the diagnosis and management difficult.

Case Report

A 43 year old lady was admitted with continuous pain of the lower abdomen for 15 days accompanied by anorexia, tachycardia and weight loss. She had a history of diagnostic laparotomy 20 years ago due to infertility and the only findings were adhesions and tubal stenosis.

On physical examination, she was conscious but ill, oral temperature was 38.2°C and heart rate = 120/min. There were both tenderness and rebound tenderness on abdominal palpation.

PPD was negative. WBC=12200 with 88% PMN and 11% Lymphocytes; ESR was 55 mm/h. BS= 127, BUN=17, Cr= 0.8, Na= 137, K=4.

Plain abdominal X-Ray showed scattered small calcifications and two large curvilinear ring shaped opaque shadows with translucent centers in the pelvis (Fig. 1).

Acute cholecystitis with cholecystoduodenal

1. Assistant Professor of Vascular Surgery. Email: jkhosh20012001@yahoo.com

2. **Corresponding author**, Resident of General Surgery, Department of Vascular And Trauma Surgery, Shohada-e-Tajrish Hospital, Tajrish sq. Tehran, Iran. Tel: +98912 3541355, Email: niki_td@yahoo.com

3. Resident of General Surgery. Email: a.najafbeygi@yahoo.com

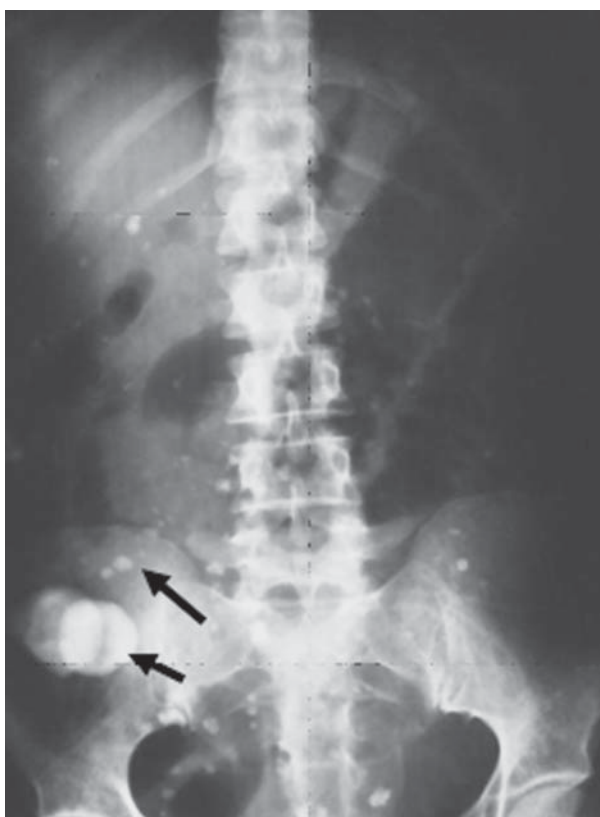

Fig. 1. plain Abdomen: Enteroliths (Black Arrow); Calcifications (Dashed Arrows).

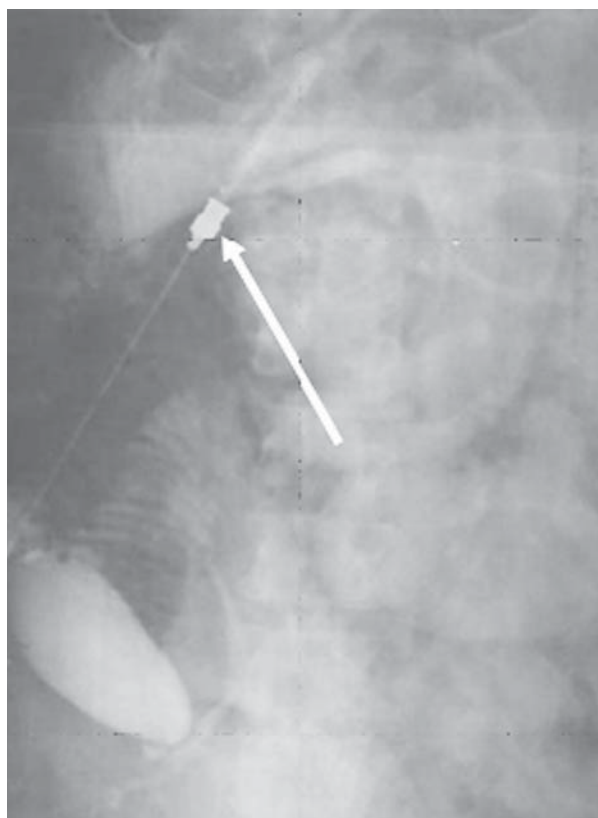


Fig. 2. Intraoperative Cholangiogram: there is no fistulous tract.

fistulae, ruptured ovarian teratoma, and bacterial peritonitis were the possible differential diagnoses. At laparotomy, a frozen pelvis, bowel adhesions, omental calcified nodules of various sizes, and two large enteroliths which could not be passed through the stenotic area were our findings.

We initially took biopsies from the calcified nodules, then performed an intraoperative cholangiogram which did not show a cholecystoduodenal fistula (Fig.2).

Enteroliths were extracted through an enterotomy performed on a normal part of small bowel.

She has been treated medically with a full course of antituberculous drugs, after pathologic confirmation of tuberculous granulomas.

Three months after discontinuation of medical therapy, she developed classic small bowel obstruction (Fig. 3).

On second Laparotomy, soft adhesion bands were seen between small bowel loops and an obstructive band was present at 30cm from the ligament of Treitz (Fig. 3). A full enterolysis was performed to relieve obstruction and no stricture was found to resect. After five years of normal life, she underwent the third laparotomy for bowel obstruction. An obstructive band from the sigmoid to the jejunum and internal herniation of the ileum was the cause, and although a 23 cm loop of jejunum was resected due to an impression of interloop fistula and stenosis, this was not confirmed by histologic examination.

Discussion

Since abdominal tuberculosis can mimic many surgical diseases, unnecessary surgery may result in mortality and morbidity [7,10].

Due to the 7.5% incidence of fistulae and per-

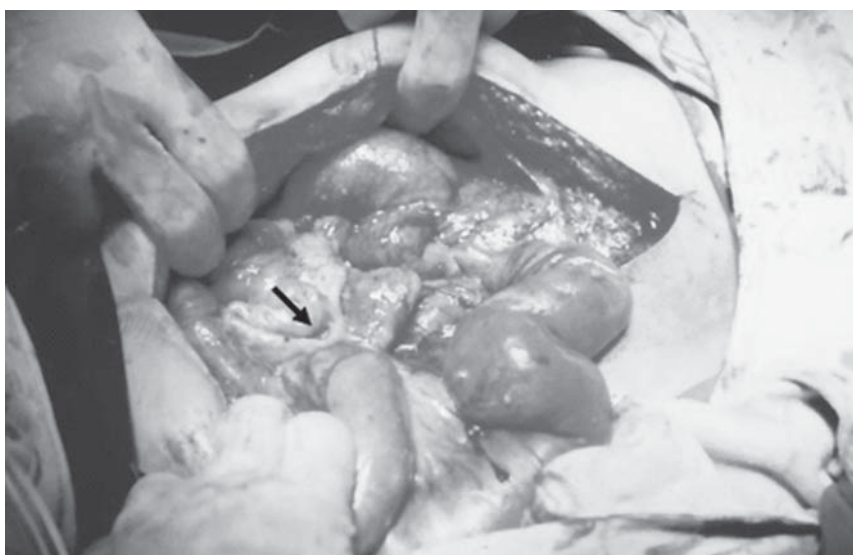

Fig. 3. Laparotomy findings; an obstructive band (black arrow), and dilated proximal loops (dashed arrows).

foration which is usually localized, free perforation and secondary bacterial peritonitis will ensue if unnecessary and additional procedures are performed [6,7,14].

Although enteroliths are associated with significant stenosis, they are not per se, an indication for surgery and all presented cases in the literature had sub acute and partial obstructions [9,11,12,13]. A large series was operated due to underlying stricture [9,11,12,13] but one case who refused surgery [9] and another who passed an enterolith by medical treatment [6] along with our case whose strictures disappeared after medical therapy, indicate that the approach to enteroliths should be medical initially.

Considering the possible complications of surgery and the absence of absolute indications for surgery due to the prevalence of partial rather than complete obstruction, this judgment seems sound.

References

1. Werbeloff L, Betal M. The radiology of tuberculosis of the gastrointestinal tract. *Br J Radiol* 1973; 43: 339-529.

2. Serhig S. Tuberculous peritonitis, A review of 100 cases. *Am Rev Respir Dis* 1967; 95: 398-401.

3. Berg K. Enterolithiasis with tuberculous intestinal strictures. *Br J Radiol* 1964; 433: 73-75.

4. Gilinsky NH, Marks IN, Kottler RE, Price SK. Abdominal tuberculosis, A 10 years review. *SA Med J* 1983; 64: 849-857

5. MC-Lauphin S. Laparoscopic diagnosis of abdominal tuberculosis. *Aust J Surg* 1998; 68(8): 599-601.

6. Nagi B, Lal A, Kochhar R. Perforations and fistulae in gastrointestinal tuberculosis. *Acta Radiol* 2002; 43(5): 501-506.

7. Watters DAK. Surgery for tuberculosis before and after HIV infection: A tropical perspective. *Br J Surg* 1997; 84(1): 8-14.

8. Kaushik SP, Bassett ML, McDonald C, Lin BP, Bokey EL. Gastrointestinal tuberculosis simulating Crohn's disease. *J Gasroenterol Hepatol* 1996; 11(6): 532-534.

9. Chawla S, Bery K, Indra KJ. Enterolithiasis complicating intestinal tuberculosis. *J Clinic Radiol* 1996; 17: 274-279.

10. Homan WP, Grafe WR, Dineen PI. A 44 years experience with tuberculous enterocolitis. *World J Surg* 1977; 1: 245-250.

11. Sheikh MY, Rizvi IH, Naeem SA, Ahmad I. Enterolithiasis secondary to intestinal tuberculosis. *J Pak Med Assoc Jul* 1991; 41(11):286-7.

12. Sood PC, Dhiman ML, Gupta KL. Calcific enterolithiasis. *Tropical Doctor* 1997; 27: 187-188.

13. Khoda J. Is enterolithiasis more frequent in desertic areas? Report of 8 cases. *J Chir* 1992; 129(2): 111-114.