

## Huge obstructive bladder diverticula and cystic dysplastic kidneys in a newborn: a challenging dilemma

Nakysa Hooman<sup>1</sup>, Farideh Hallaji<sup>2</sup>, Fariba Jahangiri<sup>3</sup>, Seyed Hassan Mostafavi<sup>4</sup>

*Department of Pediatric Nephrology, Ali-asghar Children Hospital, Iran University of Medical Sciences, Tehran, Iran.*

Received: 26 February 2010

Revised: 19 June 2010

Accepted: 23 June 2010

### Abstract

This study investigated a 63-day boy with end stage renal disease and abdominal cysts. The antenatal sonography detected anhydramnios, posterior urethral valve, and cystic dysplastic kidneys. Voiding cystourethrogram revealed two obstructive giant diverticula which at first looked like enlarged renal pelvis. The patient had persistent urinary tract infection and perforation of diverticula. The dialysis was ineffective because of leakage, immeasurable inflow and dwell volume, peritonitis and tunnel infection. As a result, the availability of automated peritoneal dialysis for infants is recommended to reduce morbidity and increasing the survival rate. Nonetheless the giant bladder diverticulae might be better managed by diverticulectomy procedure.

**Keywords:** congenital bladder diverticula, cystic renal dysplasia, end stage renal disease, anhydramnios, prenatal diagnosis, urinary tract infection.

### Introduction

The prevalence of bladder diverticula is 1.7% and usually detected accidentally but sometimes presented with urinary tract infection, urinary retention, spontaneous rupture, or neoplastic changes [1-4]. We report a complicated case with giant congenital bladder diverticula (CBD), bilateral renal dysplasia, posterior urethral valve (PUV), without hydronephrosis, but the association that has not been reported yet. The management was a great challenge.

### Case Report

This study investigated a 64 day-old boy with an antenatal sonography that revealed severe oligohydramnios in 16th week of gestation, anhydramnios afterward, hypoplastic lung, and dysplastic kidneys with dilated ureters suggestive for PUV. Moreover he suffered from fever, dehydration, status clonic seizure, and failure to thrive. He also had potter facies with systolic murmur II/VI over the sternal borders, two soft lumps on inguinal regions, BP=97/50 mmHg, WT=2.5 kg, and urine output of 2 ml/kg/h.

1. **Corresponding author**, Associate Professor, Department of Pediatric Nephrology, Ali-asghar Children Hospital, Iran University of Medical Sciences. N193, Ali- Asghar Children Hospital, Vahid-Dasgerdi St., Modarres Expressway, Tehran, Iran. Tel: +9821 23046378, Fax: +9821 22220063, email: hakiwa@iums.ac.ir.

2. Assistant Professor, Department of Radiology, Ali-Asghar Children Hospital, Iran University of Medical Sciences. Email: F\_Hallaji@yahoo.com

3. Assistant Professor, Department of Pediatric Surgery, Ali-asghar Children Hospital, Iran University of Medical Sciences. Email: f.jahangiri@yahoo.com

4. Assistant Professor, Department of Radiology, Ali-asghar Children Hospital, Iran University of Medical Sciences. Email: hmostafa1@yahoo.com

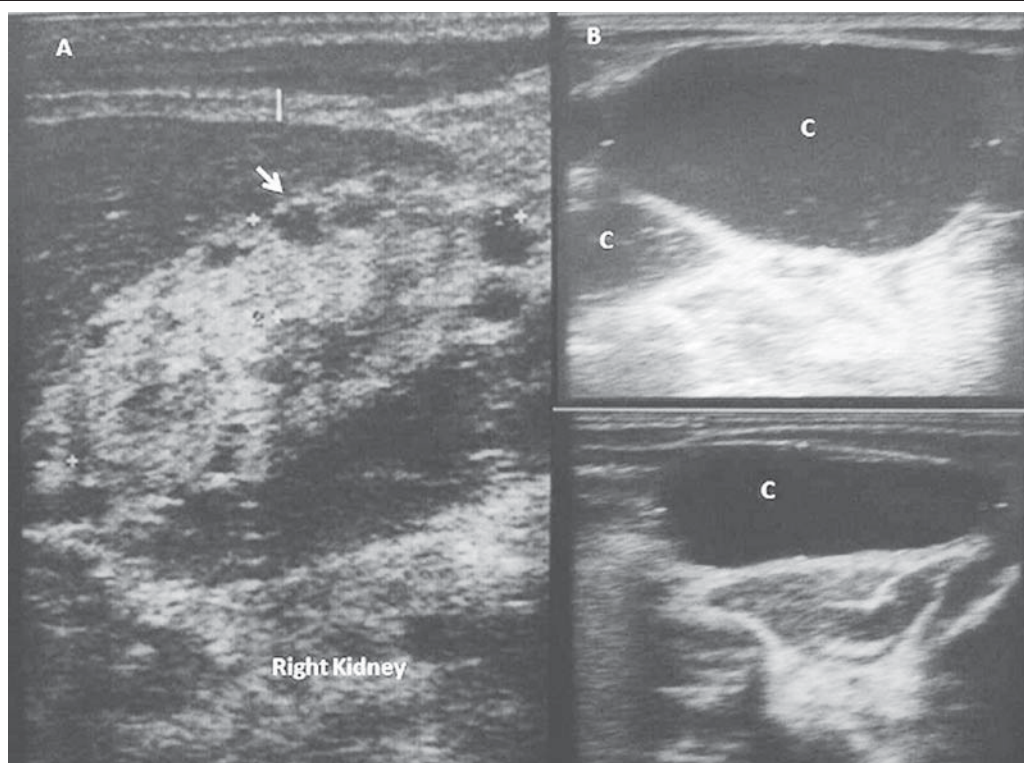


Fig 1. Abdominal sonography A. bilateral small sized echogenic kidneys with macrocysts (arrow) predominantly in subcapsular region, poorly corticomedullary differentiation without hydroureteronephrosis; B. Two debris contained cystic spaces, C. outside and adjacent to the bladder,

The Lab tests were: BUN=140 mg/dl, Cr=7.7 mg/dl, Na=130 meq/L, K= 5.3 meq/L, Ca=5 mg/dl, P=16 mg/dl, Mg=0.9 mg/dl, Alkp=235 IU, PH=7.11, PCO2=21.5 mmHg, HCO3=6.7 meq/L, WBC=13200(PMN=57%), Hb=4.3 g/dl, PLT=395000, and ESR=60 mm/H.

Abdominal sonography was suggested for cystic dysplastic kidneys and two large cysts superolateral to the urinary bladder were detected (Fig1). The cysts were filled on VCUG (Fig 2), and laparotomy for insertion of peritoneal dialysis (PD) catheter confirmed the imaging findings. The diverticula were filled with thick pus to the extent that manual drainage was a difficult task, hence vesicostomy tube inserted to facilitate drainage of the bladder. The culture of the pus grew klebsiella pneumonia. After operation the patient became gradually oliguric with distended abdomen and there was leakage of fluid from the PD catheter exit site that raised the suspicion for the bladder perforation.

The PD catheter was removed because of persistent peritonitis and tunnel infection after two weeks. The condition of the patient deteriorated and passed away after twenty days.

### Discussion

The case was interesting for continuing pregnancy despite having the stigmata of poor renal function during fetal period, the unusual VCUG images, and the current obstacles of continuous ambulatory peritoneal dialysis (CAPD) in newborns. We focused on expanding discussion over these three dilemmas.

First continuing this kind of pregnancy was very controversial, because the prognosis for fetal renal function was poor with the presence of severe oligohydramnios, echogenic cystic kidneys, fetal urine flow less than 2 ml/h with high urine electrolytes indices. However, the recent systematic review showed that none of the fetal urine analysis could accurately predict

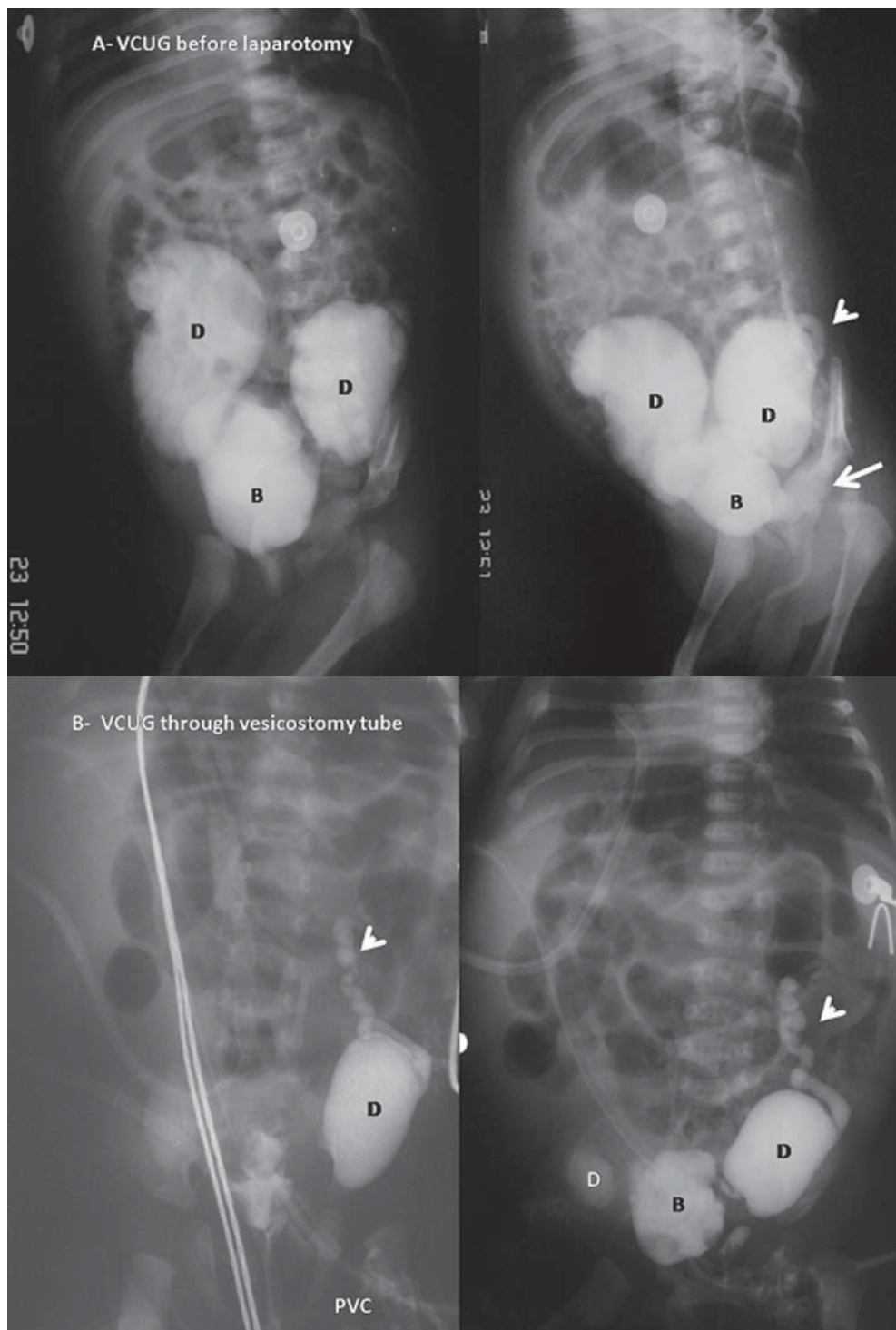


Fig 2. A. Voiding cystourethrogram revealing two large bladder out pouches (D) with narrow neck at uretrovesical junctions which were compatible with CBD (Hutch). B. accompanied by grade I vesicouretral reflux on the left side (small arrow), and dilated posterior urethra (long arrow).

the postnatal renal outcome [6].

Nevertheless, the presence of high serum creatinine, incontinency, and high vesicoureteral

reflux in newborn with PUV are associated with higher risk of renal failure and even lower urinary tract malfunction[7]. The rationale for

prenatal intervention of fetal hydronephrosis is to maximize lung and kidney function. However, the prenatal intervention might improve lung development in fetus with PUV but it could not prevent renal insufficiency. Detection of bladder diverticulum in fetus by sonographic imaging have been reported and large cystic bladder should be considered in differential diagnosis [8-10]. The fetal sonography in this case revealed a huge diverticula as dilated ureters.

The presence of two obstructive giant diverticula resembling enlarged renal pelvis was another interesting point in this study. A protrusion with diameter greater than 2 cm is considered as vesical diverticulum and it differs from pseudodiverticule inducing mucosal herniation in bladder wall. The bladder diverticula are categorized into three groups: 1- bladder outlet obstruction secondary to neurogenic bladder, ureterocele, or PUV, 2- postsurgery, and 3- primary CBD that are either paraureteral (either ureteral end in normal position or in diverticulum and associated with VUR), posterolateral (with urethral compression), or multidiverticular (associated with syndromes such as Menkes, Ehlers-Danlos, Williams, or Prune belly) [1-5,11]. Our case had normal hair, face, skin elasticity, and the abdominal wall. The posterior portion of the urethra was also dilated resembling either diverticulum or secondary to PUV. The presentation of CBD is urinary tract infection [3, 5], urosepsis [10], and urinary retention [2,5], similar to our patient who had persistent urinary tract infection secondary to urinary stasis. Nonetheless there is a tendency to develop bladder malignancy, urolithiasis, or spontaneous rupture [4].

The CAPD was initiated for treating uremic encephalopathy but the first challenge was current 2-L bag in each cycle by using current scale inspite of small fill and dwell volume (5cc/kg-40cc/kg). The patient developed Leakage, abdominal distention, and persistent peritonitis. We previously have reported that the mortality

and morbidity of infants on CAPD is high in the absence of automated peritoneal dialysis (APD) [12].

The primary cutaneous vesicostomy followed by diverticulectomy are recommended during neonatal period [5, 13]. Vesicostomy tube was ineffective to drain CBDs in this case in addition to resistant infection with ESBL microorganism which in turn made the resection of diverticula impossible. Bogandos et al. showed the advantage of diverticulectomy in 22 children with lager bladder diverticula as defined by the diverticulum's maximum diameter equal or greater than one-third of the bladder diameter[5]. Another cohort study on 21 pediatric patients with bladder diverticula showed the same advantage of early diverticulectomy and ureteral reimplantaion in the case of high vesicoureteral reflux. The recurrent of infection was totally eliminated and in half of the patients bladder dysfunction improved [13,14].

In conclusion, it is absolutely necessary to provide APD for pediatric hospitals to improve survival of small infants with renal failure. Giant CBD might be better managed by diverticulectomy procedure to eliminate the risk of resistant urinary tract infection.

## References

1. Blane CE, Zerlin JM, Bloom DA. Bladder diverticula in children. *Radiology* 1994;190:695-7.
2. Wickramasuriya NI, Muthucumar M, Hewavithana PB. A rare cause of acute urinary retention in a male infant. *J Pediatr Urol* 2008; 4: 243-4.
3. Garat JM, Angerri O, Caffaratti J, Moscatiello P, Villavicencio H. Primary congenital bladder diverticula in children. *Urology* 2007; 70:984-8.
4. Stein RJ, Matoka DJ, Noh PH, Docimo SG. Spontaneous perforation of congenital bladder diverticulum. *Urology* 2005; 66:881.
5. Bogdanos J, Paleodimos I, Korakianitis G, Stephanidis A, Androulakakis PA. The large bladder diverticulum in children. *J Pediatr Urol* 2005; 1:267-72.



6. Morris PK, Quinlan-Jones E, Kilby MD, Khan KS. Systematic review of accuracy of fetal urine analysis to predict poor postnatal renal function in cases of congenital urinary tract obstruction. *Prenat Diagn* 2007; 27: 900-11.
7. Otukesh H, Sharifiaghdas F, Hoseini R. Long-term upper and lower urinary tract functions in children with posterior urethral valves. *J Pediatr Urol* 2009; 6: 016.
8. Gaudet R, Heim N, Merviel P, Lemerrier D, Dumont A, Audry G, Uzan S. Prenatal diagnosis of congenital bladder diverticulum: case report and benefits of prenatal diagnosis. *Fetal Diagn Ther* 1999; 14: 301-5.
9. Shalev J, Itzhak Y, Blau H, Rosenman J, Ben-Refael Z, Brish M, et al. The prenatal ultrasonic diagnosis of urethral obstruction and diverticulum of the urinary bladder. *Pediatr Radiol* 1982; 12: 48-50.
10. Chen CP, Tzen CY, Wang W. Prenatal diagnosis of cystic bladder distension secondary to obstructive uropathy. *Prenat Diagn* 2000; 20: 206-63.
11. Ryoo JW, Cho JM. Multiple bladder diverticula in Menkes disease. *Pediatr Radiol* 2008; 38: 595-9.
12. Hooman N, Esfahani ST, Mohkam M, et al. The Outcome of Iranian Children on Continuous Ambulatory Peritoneal Dialysis: The First Report of Iranian National Registry. *Arch Iranian Med* 2009; 12: 24-8.
13. Evangelidis A, Castle EP, Ostlie DJ, Synder CL, Gatti JM, Murphy P. Surgical management of primary bladder diverticula in children. *J Pediatr Surg* 2005; 40: 701-3.
14. Rawat J, Abdul-Rashid K, Kanojia RP, Kureel SV, Tandon RK. Diagnosis and management of congenital bladder diverticulum in infancy and childhood: experience with nine cases at a tertiary health center in a developing country. *Int Urol Nephrol* 2009; 41: 237-42.