

An extremely large primary omental hydatid cyst: report of a rare case

Arman Aghaei¹, Alireza Khalaj², Ashkan Divanbeigi³

Shefa Neurosciences Research Center, Iran University of Medical Sciences, Tehran, Iran.

Received: 22 Oct 2012

Revised: 22 Feb 2013

Accepted: 6 March 2013

Abstract

Hydatid disease is a parasitic infection caused by *Echinococcus granulosus* (larval form) in humans with lesions most frequently encountered in the liver and lungs. It can rarely involve extra-hepatic organs. It is endemic in some regions of Iran. The omental hydatid cyst is a very rare manifestation of the disease. This report presents the interesting case of a very large omental hydatid cyst.

Keywords: Echinococcosis, Hydatid cyst, Omentum.

Introduction

Hydatid disease is a parasitic infection caused by the larval form of *Echinococcus granulosus* in humans. It produces characteristic cystic lesions most frequently localized in the liver and lungs. Extra-hepatic involvement is rare (1). The disease is endemic in several regions of Iran (2). The omental hydatid cyst represents a very rare manifestation of the disease. It is usually secondary to the rupture of a liver or splenic cyst. Primary peritoneal cyst is extremely rare and should be differentiated from a mesenteric or duplication cyst (3,4).

The following case report presents a case of an extremely large omental hydatid cyst.

Case presentation

The case was an 82-year-old woman, with a body weight of 61 kg, who was referred to the emergency room with complaints of severe abdominal distention and dyspnea.

She was admitted in the internal medicine ward with a primary diagnosis of ascites due to cirrhosis, based on the presence of the Caput medusae sign and clinical suspicion of ascites. She had a past history of eight abortions. She also mentioned an episode of abdominal distention about 40 years ago with a slow evolution. She also complained of a loss of the ability to walk during the last 10 years. During the last 2 years, her dyspnea has worsened gradually, so that she was unable to sleep in the supine position and obliged her to rest in lateral decubitus and semi-sitting positions. She had no other significant history of digestive problems during the recent years.

Abdominopelvic ultrasonography showed a heterogeneous hypoechoic lesion filling the whole abdominal and pelvic cavities. Hematologic, serologic and hepatic tests were reported to be normal. After a surgery consult, an abdominal and pelvic computed tomography scan (CT) with intra-venous

1. MD. General surgeon, Department of surgery, Shahed University, Tehran, Iran. drarman_ghaei@yahoo.com

2. MD. Associate professor of general surgery, Department of Surgery, Shahed University, Tehran, Iran. arkhalaj@yahoo.com

3. (Corresponding author) MD. Researcher, Shefa Neurosciences Research Center, Iran University of Medical Sciences, Tehran, Iran. adivanbeigi@farabi.tums.ac.ir

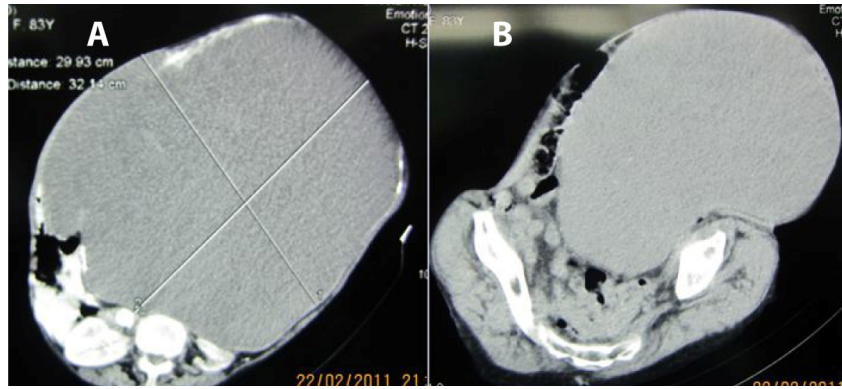


Fig. 1-A. Calcifications of the cyst wall with extension to the abdominal skin border. B. A giant hypodense cystic mass within the abdominopelvic cavity.

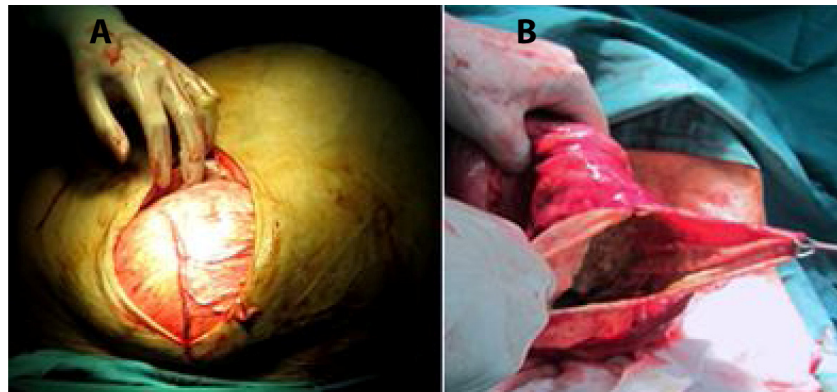


Fig. 2-A. Anterior wall of the cyst was covered by the greater omentum, with manifestations of a vascular pattern B. Hard and sticky debris of cyst after aspiration.

(IV) contrast revealed a giant hypodense cystic mass of about 30x32 x43 cm located in the entire abdominopelvic cavity. It also revealed cystic wall calcifications in several areas that were extended to the abdominal skin border (Fig.1). With the differential diagnostics of ovarian cystadenoma, mesenteric cyst and omental cyst, the medical team decided to perform laparotomy in which a large cyst was revealed that had displaced the intestines to the sides of the abdomen. There was an important cyst calcification near the left abdominal wall, of about 2x4 cm. Anterior wall of the cyst was covered by the greater omentum, with manifestations of a vascular pattern (Fig.2). Cyst aspiration was performed and the sample was sent for pathological analysis. About 20 liters of cystic contents were aspirated. After decompression of the cyst, atrophy of the uterus, ovaries, stomach and spleen were observed. The posterior wall of the cyst adhered inti-

mately and extensively to the mesentery, which prohibited the complete cyst release from the surrounding structures. The debris contained within the cyst was hard and sticky; therefore, the cyst was washed using Povidone-iodine 10% and the debris inside the cyst was removed (Fig.2). Finally, we performed a partial cystectomy and ensured external drainage. After five days, the patient was breathing normally and her weight was 44 kg (17 kg weight loss) (Fig.3). The pathology report confirmed a hydatid cyst in the sample of cystic wall, but smear and culture of cystic contents were negative.

The patient was discharged home and prescribed oral Albendazol with a dose of 15 mg/kg per day. After two weeks, the drain tubes were removed and she could walk without any help after 10 years and sleep in supine position after 2 years.

Discussion

The human is an intermediate host in the life cycle of *Echinococcus granulosus* and infection occurs after the consumption of foods contaminated by canidae feces (5,6). Our case had a high probability of having hydatid disease, because she was a farmer working in close contact with the domestic animals with poor access to proper sanitary conditions, and limited access to medical care.

Primary peritoneal hydatid cyst is a very rare entity and is usually secondary to hepatic disease. The overall frequency of peritoneal echinococcosis is approximately 13%. Most of these cases are related to previous surgery for hepatic disease (3,4,7). Hydatid cysts might be asymptomatic or without any complications, but sometimes may rupture, become infected secondarily or infect other organs. Ultrasound imaging is the investigation of choice and is diagnostic in 95% of the cases. It can also indicate Hydatid sands in competent cysts, as well as floating membranes and vesicles. The CT scan is superior to ultrasonography in detecting extrahepatic cysts, but is not superior in the detection of omental cysts. However, it might generally indicate a cyst and its structure, besides calcifications.

Pseudocysts and complex cysts are characterized by walls of different thickness in CT scan and ultrasound. Imaging findings on CT show us the origin and whether the cyst is unilocular, contains daughter vesi-

cles, contains daughter cysts, is partially calcified, or is completely calcified (dead cyst) (3,8,9).

Laboratory diagnosis is made by Enzyme-linked immunosorbent assay (ELISA) test which is positive for echinococcus in 95-97% of infected patients. Routine laboratory tests including complete blood counts and liver function tests may be abnormal, but are nonspecific and cannot make a diagnosis (8).

Most of the times, the primary omental cyst is solitary. The mechanism responsible for this situation is not clear. Parasites should pass the liver filter followed by the lung filter before reaching atypical body areas. Hydatid cyst might have lymphatic distribution as well; so that if liver, lung, and spleen are spared, the hydatid cyst might distribute elsewhere and cause muscular, retroperitoneal involvement or affect the subcutaneous space (10).

It is difficult to preoperatively define the disease and ruling out other differential diagnosis based on the lesion site in unusual cases, and missing preoperative diagnosis is possible. The diagnosis is made by a set of diagnostic methods including imaging, scanning, and laboratory and serologic diagnostic tests. Since hydatid cysts cause a wide range of symptoms, multiple abdominal lesions must always be considered in the differential diagnosis (3,6,7).

The aim of hydatid cyst treatment is to remove current cyst as well as preventing

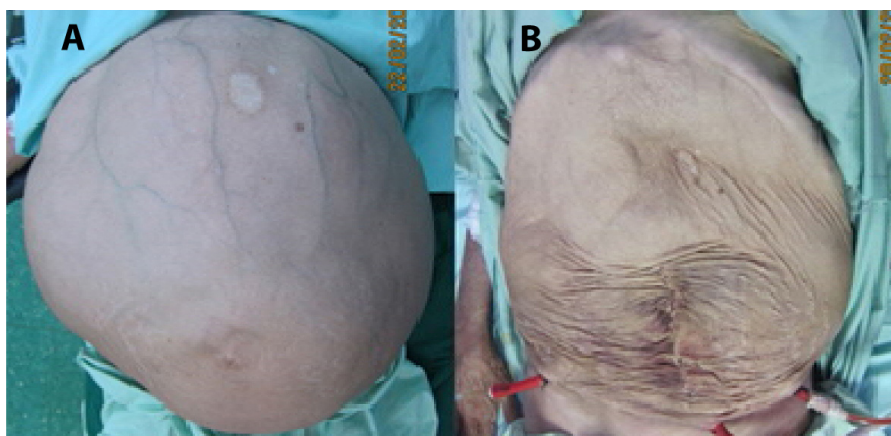


Fig. 3-A. Preoperative situation: Caput medusae sign. B. Postoperative situation.

recurrence and complications. Surgery, whether conservative or radical, is still the treatment of choice in cysts. Total cystectomy without sacrificing other organs represents the basis of surgery. When a cyst is attached to the abdominal wall, percutaneous aspiration and alcohol injection and reaspiration can be useful. When a cyst has an intra-abdominal location, complete or partial cystectomy, with or without drainage, or omentopexy are the options. The surgical method used in this case was partial cystectomy with drainage (11,12,13).

Albendazole therapy should be added to the treatment to prevent spillage and to avoid recurrence of the disease. Preoperative treatment with albendazole is effective in reducing the rate of recurrence (6,14). Overall, hydatid cyst should be considered as a differential diagnosis of omental cysts, especially in endemic areas for hydatid disease.

References

1. Yuksel M, Demirpolat G, Sever A, Bakaris s, Bulbuloglu E, Elmas N. Hydatid disease involving some rare locations in the body: a pictorial essay. *Korean J Radiol.* 2007; 8(6): 531-540.
2. Mamishi S, Sagheb S, Pourakbari B. Hydatid disease in Iranian children. *J Microbiol Immunol Infect.* 2007; 40(5): 428-431.
3. Ilica AT, Kocaoglu M, Zeybek N, Guven S, Adaletli I, Basgul A, et al. Extrahepatic abdominal hydatid disease caused by *Echinococcus granulosus*: imaging findings. *AJR Am J Roentgenol.* 2007; 189(2): 337-343.
4. Gun F, Devecioglu D, Salman T. Traumatic rupture of hydatid cyst with unusual localization without liver involvement: a case report. *Eur J Pediatr Surg.* 2007; 17(1): 59-61.
5. Khuroo MS. Hydatid disease: current status and recent advances. *Ann Saudi Med.* 2002; 22(1-2): 56-64.
6. Daali M, Hssaida R, Zoubir M, Hada A, Hajji A. Peritoneal hydatidosis: a study of 25 cases in Morocco. *Snate.* 2000; 10(4): 255-260.
7. Pedrosa I, Saiz A, Arrazola J, Ferreiros J, Pedrosa CS. Hydatid disease: radiologic and pathologic features and complications. *Radiographics.* 2000; 20(3): 795-817.
8. Sekmenli T, Koplay M, Sezgin A. Isolated omental hydatid cyst, clinical, radiologic and pathologic findings. *J Pediatr Surg.* 2009; 44(5): 1041-1043.
9. Alis H, Kapan S, Öner O, Soylu A, Dolay K, Kalayci MU, et al. Primary omental hydatid cyst. *Int Med Case Reports J.* 2009; 2: 7-10.
10. Wani RA, Malik AA, Chowdri NA, Wani KA, Naqash SH. Primary extrahepatic abdominal hydatidosis. *Int J Surg.* 2005; 3(2): 125-127.
11. Buttenschoen K, Carli Buttenschoen D. *Echinococcus granulosus* infection: the challenge of surgical treatment. *Langenbecks Arch Surg.* 2003; 388(4): 218-230.
12. Mosca F. Our experience in the surgical treatment of peritoneal hydatid disease. *G Chir.* 2004; 25(11-12): 385-389.
13. Versaci A, Scuderi G, Rosato A, Angiò LG, Oliva G, Sfuncia G, et al. Rare localizations of echinococcosis: personal experience. *ANZ J Surg.* 2005; 75(11): 986-991.
14. De U. Rare primary extrahepatic intra-abdominal hydatid cysts. *Trop Doct.* 2009; 39(3): 172-175.