

Well differentiated liposarcoma of spermatic cord: report of 3 rare cases

Maryam Abolhasani¹, Mashaallah Babashahi², Tina Shooshtarizadeh³
Mojgan Asgari⁴, Hossein Shahrokh⁵, Pejman Shadpour⁶, Maryam Emami⁷

Received: 24 Jan 2013

Accepted: 7 June 2013

Published: 22 Feb 2014

Abstract

Spermatic cord liposarcomas are very rare tumors. Patients usually present with painless growing scrotal swellings which are clinically misdiagnosed as hernia. The correct diagnosis is not common and usually they present as operative or histological surprises. To our knowledge, there are about 186 similar cases reported in the literature. Herein we report three cases of spermatic cord liposarcoma with clinical presentation of scrotal bulging, mimicking inguinal hernia in one case and resembling a testicular tumor in the other two cases. The patients were operated and all of them underwent radical orchiectomy and tumor resection.

Keywords: Spermatic cord, Liposarcoma, Hernia, Pathology.

Cite this article as: Abolhasani M, Babashahi M, Shooshtarizadeh T, Asgari M, Shahrokh H, Shadpour P, Emami M. Well differentiated liposarcoma of spermatic cord: report of 3 rare cases. *Med J Islam Repub Iran* 2014 (22 Feb). Vol. 28:10.

Introduction

Soft tissue tumors of spermatic cord including spermatic cord liposarcomas are very rare tumors (1-2). Patients usually present with painless growing scrotal swellings. Most of them are clinically misdiagnosed as hernia (2-3). Based on the literature review, there are about 186 cases of reported liposarcomas in the English literature (4). Liposarcoma of spermatic cord usually occurs in older age men and rarely in young patients (1,5). There is an increased incidence of this cancer in Japanese (nearly one fourth of all reported cases) but the cancer has a worldwide distribution (1). Benign lesions constitute about 80% of all

spermatic cord tumors in young boys and mostly originate from lipomatous tissue. Liposarcomas are the most common paratesticular tumors in adults. Despite the fact that lipomatous neoplasms are the most common paratesticular neoplasms, they play minor role in the spermatic cord malignancies, comprising only approximately 5% to 7% of all spermatic cord sarcomas (6). Most cases are well differentiated liposarcomas. Myxoid and mixed myxoid/round cell liposarcomas are rare (7). Clinical evaluation may be inaccurate and they should be differentiated from inguinal hernia, hydrocele and chronic epididymitis. The correct diagnosis is not common and usually they present as operative or histo-

1. (Corresponding author) Assistant Professor of Pathology, Oncopathology Research Center and Hasheminejad Clinical Research Developing Center (HCRDC), Iran University of Medical Sciences (IUMS), Tehran, Iran. mar.abolhasani@gmail.com
2. Resident of pathology, Iran University of Medical Sciences (IUMS), Tehran, Iran. dr.sbabashahi@yahoo.com
3. Assistant Professor of Pathology, Oncopathology Research Center and Hasheminejad Clinical Research Developing Center (HCRDC), Iran University of Medical Sciences (IUMS), Tehran, Iran. tinashooshtarizadeh@gmail.com
4. Associate Professor of Pathology, Oncopathology Research Center and Hasheminejad Clinical Research Developing Center (HCRDC), Iran University of Medical Sciences (IUMS), Tehran, Iran. mojgan_asgari@yahoo.com
5. Assistant Professor of Urology, Hasheminejad Clinical Research Developing Center (HCRDC), Iran University of Medical Sciences (IUMS), Tehran, Iran. hosseinsharokh@hotmail.com
6. Associate Professor of Urology, Hasheminejad Clinical Research Developing Center (HCRDC), Iran University of Medical Sciences (IUMS), Tehran, Iran. pejman.shadpour@hkc.ir
7. Assistant Professor of Urology, Hasheminejad Clinical Research Developing Center (HCRDC), Iran University of Medical Sciences (IUMS), Tehran, Iran. emami59658@yahoo.com

logical surprises. The findings of ultrasound examination of liposarcoma are variable and non-specific (8). In contrast to testicular masses, ultrasound examination is less informative for paratesticular sarcomas. An ultrasound examination may help in confirming the consistency of the mass and the status of testes and the cord. CT scan has been found to be useful, as liposarcomas are of low density and can be well-demarcated. There are no pathognomonic features for the differentiation of benign versus malignant masses defined in the literature (1). Use of MRI provides good information on the local situation.

Histological grade and presence or absence of metastasis are used to determine staging of these malignances (9). Spermatic cord liposarcomas are treated by surgery in the form of radical high orchiectomy from as close to the deep ring as possible (1, 10). Adjunctive radiotherapy is recommended in cases with positive margin, relapse, lymphatic invasion and high grade tumors (11-12). The role of chemotherapy is not definite and most of the recommendations are for high grade tumors (1, 13-15). No distant metastasis but common local recurrences have been reported (16-17).

Case Report

The first case was a 63 year old man who complained of progressive scrotal swelling aggravated by physical activity since one year prior to admission. General physical exams and laboratory tests were normal. Clinically on genital examination, there was a very soft nontender left hemiscrotal enlargement resembling an indirect inguinal hernia. Ultrasound study revealed a 50x100 mm heterogenous soft tissue content in the left hemiscrotum with limited motility during Valsalva maneuver suggestive of an incarcerated omental hernia or lipoma. At the time of surgery, the cord and left hemiscrotum were occupied by a soft tissue mass with grossly abnormal heterogenous adipose containing appearance which gradually tapered into normal spermatic

cord at the proximal 3 centimeters of the inguinal canal leading into the internal ring. There was no palpable adenopathy or adherence to local tissue planes outside the spermatic fascia. Left radical orchiectomy was hence performed. Macroscopic examination showed a large encapsulated soft mass measuring 10x10x5 cm which surrounded the left spermatic cord and was inseparable from it. On cutting, it was yellow soft with areas of fish fleshy consistency. Adequate sampling from each centimeter of mass was performed. The histological examination of H&E slides revealed a neoplastic tissue, composed of adipocytes including some atypical ones and scant lipoblasts showing peripherally or haphazardly arranged nuclei and vacuolated cytoplasm (Fig. 1). Mitotic activity was mild and necrosis was absent. Immuno-histochemical stainings for MDM2 and S-100 protein were focally positive. The diagnosis was well differentiated liposarcoma of spermatic cord.

The second patient was a 37 year old man who presented with left hemiscrotal swell-

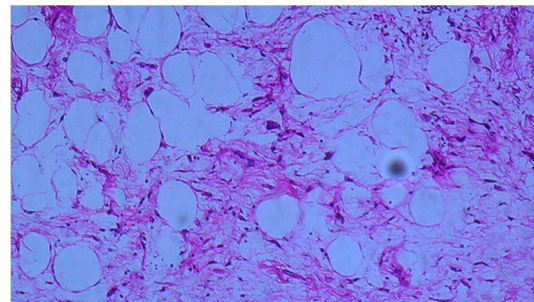


Fig. 1. Microscopic examination of case no.1 shows adipocytes including atypical ones and scant lipoblasts (x20 objective).

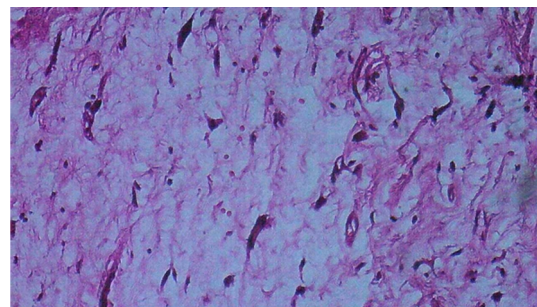


Fig. 2. Microscopic examination of case no.2 reveals atypical adipocytes and lipoblasts (x20 objective).

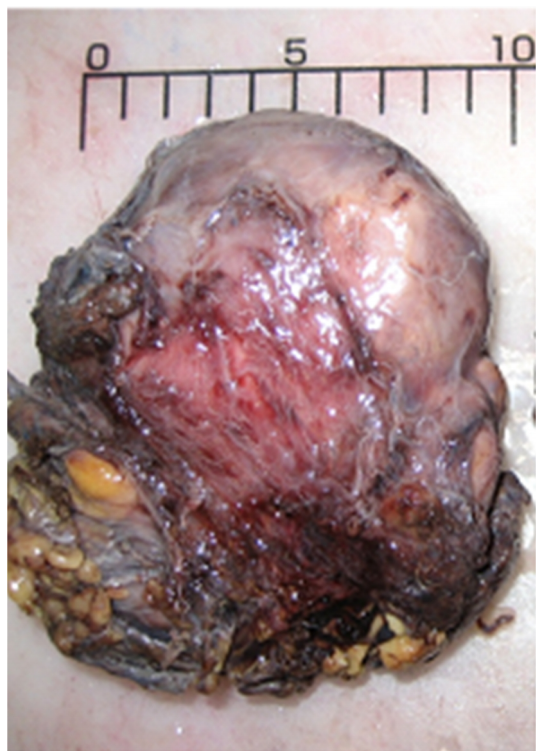

Fig. 3. External surface of hemiscrotal mass of case no.2.

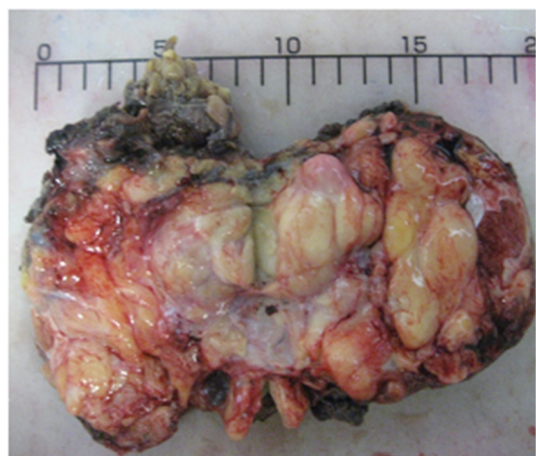

Fig. 4. Cut surface of case no.2 that is creamy yellow soft with areas of fish fleshy consistency. Cut surface of testis is also noted adjacent to it.

ing for a period of 7 months without any pain or lymphadenopathy. Physical examination showed an irregular and firm mass in superior portion of left testis. Clinical impression was testicular tumor. Laboratory tests including serum tumor markers were within normal limits. Ultrasound study revealed an echogeneous mass measuring 6.8x3.2 cm adjacent to left testis. MRI study, displayed two masses approximately 8x7 and 8x6 cm. The former was

heterogeneous and suspicious for malignancy and the latter displayed fat density. This patient also underwent left radical orchiectomy and tumor resection. Gross examination revealed two lobulated ovaloid masses measuring 9x7x6 (Figs. 2 and 3) and 8x6x6 cm which compressed the spermatic cord but did not invade into testis or epididymis. Cut sections of both masses were similar and creamy yellow soft to fish fleshy. Microscopic examination of both samples detected well differentiated liposarcomas of spermatic cord with the above mentioned histology (Fig. 4).

The third case was a 75 year old man who presented with a left scrotal mass for several months without pain or lymphadenopathy. He had history of inguinal hernia in the same side and previously had undergone herniorrhaphy. Laboratory tests including serum tumor markers were within normal limits. Ultrasound study revealed an echogeneous mass measuring 16x.8x6cm, adjacent to left testis. This patient also underwent left radical orchiectomy. Gross examination revealed a large lobulated soft mass 16.5x.8.5x6cm, surrounded by a thin capsule. Cut sections of the mass in most areas were yellowish soft but creamy irregular areas were also present. The tumor was grossly 3 cm away from spermatic cord margin. Microscopic examination of the mass was also well differentiated liposarcoma.

The margin of resection was free from tumor in all patients and subsequent abdominopelvic CT scan for assessment of retroperitoneal involvement was also negative. Therefore no adjuvant radiotherapy or chemotherapy was administrated for them. Two of the patients remained disease free over a three years' follow up period leading to the time of this report. The third one was also disease free for nine months up to the time of this report.

Discussion

Liposarcoma of the spermatic cord mostly presents in elderly patients (1, 5). Two of our cases were also presented in age of old-

er than 60 years.

Well differentiated liposarcoma is the most common histologic subtype of this malignancy that was found in all three of our cases (7). All of the three presented patients were clinically misdiagnosed at the time of presentation, one of them as an inguinal hernia and the two others as scrotal masses. Diagnostic procedures are not so specific for evaluation of spermatic cord liposarcoma (1). Ultrasound study was not helpful in our cases. Histological examination often gives an end to this diagnostic dilemma. Our cases were also finally diagnosed with the help of histological evaluation. Wide resection was performed for our cases that is the primary treatment. Local recurrence has been reported that may occur several years following surgical operation, so the patients should be followed up for a long period of time (16-17). None of our cases received adjunctive radiotherapy as they did not have positive margin, relapse, lymphatic invasion or high grade tumors.

References

1. Coleman J, Brennan MF, Alektiar K, Russo P. Adult spermatic cord sarcomas: management and results. *Ann Surg Oncol* 2003 Jul; 10(6): 669-75.
2. Vázquez-Lavista LG, Pérez-Pruna C, Flores-Balcázar CH, Guzmán-Valdivia G, Romero-Arredondo E, Ortiz-López JB. Spermatic cord liposarcoma: a diagnostic challenge. *Hernia*. 2006 Apr; 10(2):195-7. Epub 2005 Nov 10.
3. Müller Arteaga C, Egea Camacho J, Alvarez Gago T, Cortiñas González JR, Gonzalo Rodríguez V, Fernández del Busto E. Spermatic cord liposarcoma. Association with prostate cancer. Report of a case and review of literature. *Actas Urol Esp* 2005 Jul-Aug; 29(7):700-3.
4. Papageorgiou MS, Dadakas G, Donev K. Liposarcoma of the spermatic cord: a case report. *Case Report Med* 2011; 2011:197584. Epub 2011 Sep 25.
5. Montgomery E, Fisher C. Paratesticular liposarcoma: a clinicopathologic study. *Am J Surg Pathol* 2003 Jan; 27(1):40-7.
6. Ballo MT, Zagars GK, Pisters PW, Feig BW, Patel SR, von Eschenbach AC. Spermatic cord sarcoma: outcome, patterns of failure and management. *J Urol* 2001 Oct; 166(4):1306-10.
7. Domşa I, Olinici CD, Crişan D. Spermatic cord mixed liposarcoma. Case report and review of the literature. *Rom J Morphol Embryol* 2008; 49(1):105-9.
8. Yang DM, Kim HC, Lim JW, Jin W, Ryu CW, Kim GY, et al. Sonographic findings of groin masses. *J Ultrasound Med*. 2007 May; 26(5):605-14.
9. Logan JE, Williams MB, Shaves ME, McCammon KA. Liposarcoma of the Spermatic Cord: A Case Report and Review of Management. *UroToday Int J* 2010 Aug; 3(4).
10. Demirci U, Buyukberber S, Cakir A, Ozturk B, Akyurek N, Unver B, et al. Synchronous testicular liposarcoma and prostate adenocarcinoma: a case report. *Cases J* 2010 Jan 14; 3:27.
11. Hassan JM, Quisling SV, Melvin WV, Sharp KW. Liposarcoma of the spermatic cord masquerading as an incarcerated inguinal hernia. *Am Surg* 2003 Feb; 69(2):163-5.
12. May M, Seehafer M, Helke C, Gunia S, Hoschke B. Liposarcoma of the spermatic cord--report of one new case and review of the Literature. *Aktuelle Urol* 2004 Apr; 35(2):130-3.
13. Malizia M, Brunocilla E, Bertaccini A, Palmieri F, Vitullo G, Martorana G. Liposarcoma of the spermatic-cord: description of two clinical cases and review of the literature. *Arch Ital Urol Androl* 2005 Jun; 77(2):115-7.
14. Peyrí Rey E, Urban Ramón A, Martínez Fernández M, Sanmarti Da Silva B. Dedifferentiated liposarcoma of spermatic cord: degeneration of lipoma previously resected. *Actas Urol Esp* 2003 May; 27(5):383-6.
15. Bestman TJ, Populaire J, Lauwers K, Moldevez C. Liposarcoma of the spermatic cord: report of 2 cases. *Acta Chir Belg* 2007 Jan-Feb; 107(1):58-9.
16. Yoshida T, Saito J, Ichimaru N, Miyagawa Y, Nishimura K, Okuyama A, et al. Local recurrence of spermatic cord liposarcoma: a case report. *Hinyokika Kyo* 2006 Jul; 52(7):581-4.
17. Hagiwara N, Nishida Y, Fujimoto Y, Isogai K, Fujihira S, Deguchi T. Local recurrence of liposarcoma of the spermatic cord 6 years after orchiectomy: a case report. *Hinyokika Kyo* 2002 Jul; 48(7):443-6.