

Lymphoma of larynx presented with hoarseness: Case report

Farzad Izadi¹, Ehsan Parvas², Vita Derakhshandeh³

Received: 18 May 2012

Accepted: 6 July 2013

Published: 3 Mar 2014

Abstract

Primary non-Hodgkin lymphoma of the larynx is rare, accounting for less than 1% of all laryngeal neoplasms. Fewer than 100 cases have been reported in the literature and to our knowledge this may be the first reported case of laryngeal non Hodgkin lymphoma presented with hoarseness, aortic aneurysm, hepatitis B and skin rashes.

Keywords: Lymphoma, Larynx, Subglottic mass, Hepatitis B.

Cite this article as: Izadi F, Parvas E, Derakhshandeh V. Lymphoma of larynx presented with hoarseness: Case report. *Med J Islam Repub Iran* 2014 (3 Mar). Vol. 28:21.

Introduction

Primary non-Hodgkin lymphoma of the larynx is rare, accounting for less than 1% of all laryngeal neoplasms. Fewer than 100 cases have been reported in the literature (1).

Case report

A 26-year-old man, with a known case of hepatitis B, was referred to our hospital from the ENT clinic after a severe respiratory distress and hoarseness, which had occurred after an episode of upper respiratory tract infection (URTI). The condition was started 2 weeks earlier. His symptoms were started and exacerbated following URTI. He was treated with Cefixime, Theophylline and Salbutamule (inhaler) but the symptoms did not resolve. He did not have dysphagia or odynophagia, nor did carry any history of asthma, allergy, smoking or illegal substance abuse. His father had died of end stage stomach cancer about a year ago and his brother had vasculitis (who is under the treatment with corticosteroids).

Physical examination revealed fever

(38.5°C). Examination of his mouth and oropharynx showed erythema and tonsillar hypertrophy without exudates in his oropharynx. He had an obvious inspiratory and expiratory stridor and overt respiratory distress. Auscultation of lung revealed diffused wheezing in his lungs with a 3/6 systolic murmur in his left sternal border and pulmonar area. There was no evidence of peripheral edema. Indirect laryngoscopic examination showed papillomatose lesion in the 1/3 posterior portion of true vocal cords. There were maculopopular rashes on his chest wall, upper back, neck, face and extremities (Fig.1).

Chest x-ray showed an increase in bronchovascular markings in middle and upper lobes of right lung. Lateral head and neck radiography revealed a mass in his subglottic area (Fig. 2-4). Chest CT-scan showed tubular bronchectatic changes at right lobe associated with pulmonary inflammation. Fibrotic band was seen at basal portion of both lungs with no pleural effusion. There was an aneurismal dilatation of aorta with maximum diameter of 50×48 mm in the

1. MD., Associate Professor (AP) at Iran University Of Medical Science, Fellowship of Laryngology, Department of Otolaryngology, Head and neck surgery, University of Minnesota School of Medicine, U.S.A. izadimd@yahoo.com

2. (Corresponding author) MD., General Practitioner, Iran University Of Medical Science, Tehran, Iran. Ehsan_parvas@yahoo.com

3. MD., Fellowship of Laryngology, Department of Otolaryngology, Head and Neck Surgery, Iran University Of Medical Science, Tehran, Iran. derakhshandevita@gmail.com

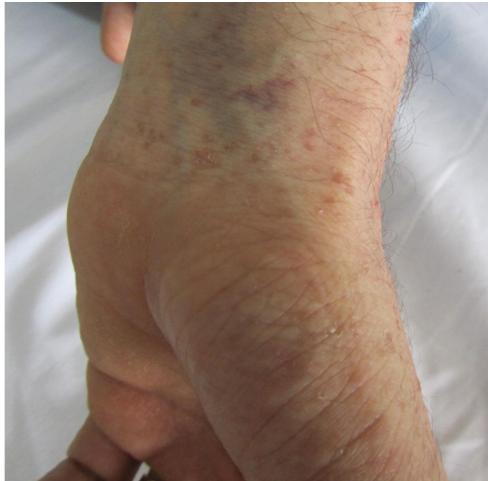

Fig.1. Maculo popular rashes on volar area of the pateint

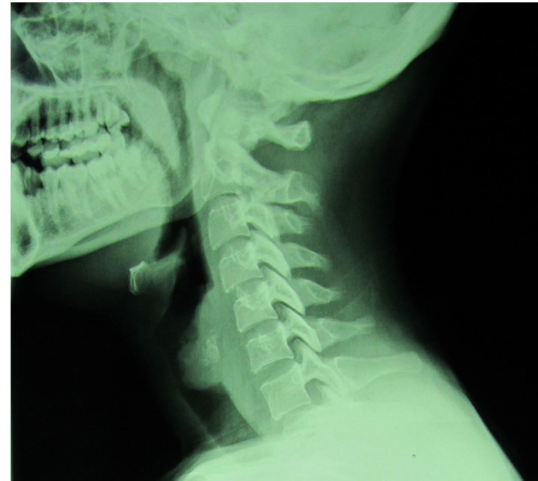


Fig.3. The patient's lateral neck X-ray

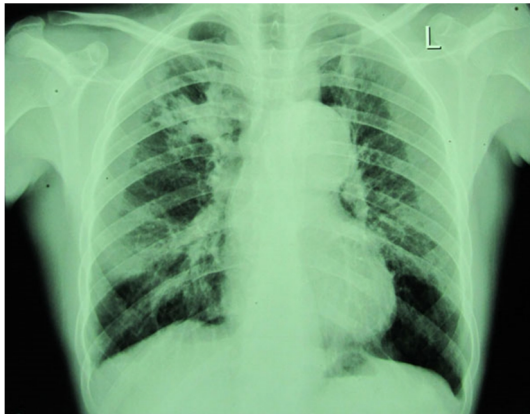

Fig.2. patient's chest X-ray

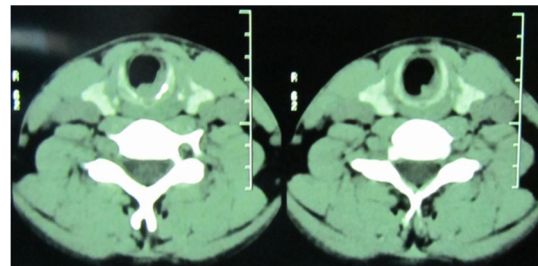


Fig.4. The patient's CT-scan which shows a subglottic mass

ascending part and about 49×45 mm in the descending part. The ultrasound echocardiography confirmed the aortic aneurysm. Venereal disease research laboratory (VDRL), fluorescent treponemal antibody-absorption test (FT-ABS), antinuclear antibody (ANA), Cytoplasmic antineutrophil cytoplasmic antibodies (C-ANCA) and Perinuclear Anti-Neutrophil Cytoplasmic Antibodies (P-ANCA) were negative and angiotensin-converting enzyme (ACE) levels fallen within normal range. His rheumatoid factor was 3+ and C reactive protein 1+. His ESR level in the first hour was 54 mm/hr. Emergency tracheostomy and mass debulking was done for emergency air way management. Direct laryngoscopy showed a 1.5 cm mass in subglottic area. Specimens were taken for culture and pathologic diagnosis. The throat cultures were negative for Mycobacterium tuberculosis and

fungus. The specimen also contained multiple pieces of creamy-brownish soft tissue. The microscopic evaluation showed tissue composed of large cells with hyperchromatic round to ovaloid nuclei, prominent nuclei and irregular border and eosinophilic cytoplasm arranged as sheets. The immunohistochemistry report was positive for leukocyte common antigen (LCA), antigen KI-67 (60% of tumoral nuclei) and negative for CD3, CD20, CD43, CD30. The pathologic diagnosis was diffuse large cell lymphoma (High grade) and immunohistochemistry test for CD79 was positive which determined the B cell type. He had no symptom afterward.

Discussion

Primary non-Hodgkin's lymphoma (NHL) of the larynx is rare. Fewer than 100 cases were reported in the literature. More commonly, the larynx is involved secondarily after the lymphoma of regional lymph nodes¹. Laryngeal lymphomas are usually sub mucosal masses, without mucosal ulceration and are most commonly found in

supraglottis especially in the aryepiglottic folds. Invasion of the subglottic larynx and trachea by lymphoma is an uncommon problem which can cause severe airway obstruction and requires multidisciplinary approach (2).

Our patient presented with an ulcerative mass of the subglottic region that is an unusual primary site for laryngeal lymphoma. Hence the site of the lesion cannot definitely rule out the diagnosis. The relationship between the aortic aneurism, lymphoma and hepatitis (in the same patient) has not been shown. There may be an increased risk of aortic aneurism in some vasculitis disorders (3). Some studies showed higher incidence of hepatitis B virus in B-cell non-Hodgkin lymphoma (NHL) patients (4,5), but we did not find any evidence of vasculitis in our patient despite his positive family history (7). Also there is an increased risk of lymphoma in the hepatitis patients (4,5), but there has not been a report of B cell lymphoma, hepatitis B, and aortic aneurism in the same patient in the literature. Opposed to the common treatment regimen in such patients, our patient responded well to a single chemotherapeutic regimen and did not need another laryngoscopic intervention.

Conclusion

There are not any characteristic findings to distinguish laryngeal lymphoma from other neoplasms without pathologic study; but when there are some systemic findings in a patient that physician should consider them as rare conditions of differential

diagnosis. However after establishing the diagnosis, treatment of these patients must be started with standard regimens, good prognosis and complete remission of the symptoms (7). The only specific treatment we performed on our patient was tracheotomy due to respiratory difficulty in the first presentation of the patient, which improved after chemotherapy. The patient was symptom free after one year of follow up.

References

1. Andriychuk A, Kristensen BW. Non-Hodgkin lymphoma of the larynx; *Ugeskr Laeger*. 2010; 172(42):2901-2.
2. Cobzeanu MD, Costinescu V, Rusu CD, Mihailovici S, Grigoras M, Miron L, Paduraru D. Arama A Laryngotracheal non-Hodgkin's lymphoma; *Chirurgia (Bucur)*. 2010; 105(1):131-6.
3. Unlü C, Willems M, Ten Berge IJ, Legemate DA. Aortitis with aneurysm formation as a rare complication of Wegener's granulomatosis. *J Vasc Surg*. 2011 Nov; 54(5):1485-7.
4. Wang F, Yuan S, Teng KY, Garcia-Prieto C, Luo HY, Zeng MS, Rao HL, Xia Y, Jiang WQ, Huang HQ, Xia ZJ, Sun XF, Xu RH. High hepatitis B virus infection in B-cell lymphoma tissue and its potential clinical relevance, *Eur J Cancer Prev*. 2012; 21(3):261-7.
5. Liu WP, Zheng W, Wang XP, Song YQ, Xie Y, Tu MF, Lin NJ, Ping LY, Ying ZT, Deng LJ, Zhang C, Zhu J. An analysis of hepatitis B virus infection rate in 405 cases of non-Hodgkin lymphoma, *Zhonghua Xue Ye Xue Za Zhi*. 2011; 32(8):521-4.
6. Miller DV, Maleszewski JJ. The pathology of large-vessel vasculitides; *Clin Exp Rheumatol*. 2011; 29 (1 Suppl 64): S92-8.
7. Cabanillas F. Non-Hodgkin's Lymphoma: The Old and the New; *Clin Lymphoma Myeloma Leuk*. 2011; 11 Suppl 1:S87-90.