

Retroperitoneal bronchogenic cyst: a case report

Ali Mirsadeghi¹, Farid Farrokhi², Azadeh Fazli-Shahri³, Bahareh Gholipour⁴

Received: 4 August 2013

Accepted: 7 December 2013

Published: 13 July 2014

Abstract

Bronchogenic cysts are among developmental disorders of the primitive foregut which are typically found above the diaphragm. Bronchial cysts discovered in the abdominal cavity or retroperitoneum are extremely rare. We present a rare case of a retroperitoneal bronchogenic cyst which was incidentally detected after a wrestling injury in a 23-year-old man who had a negative medical history. Although initial imaging studies suggested an adrenal tumor, histopathological analysis provided a definite diagnosis of bronchogenic cyst. Though rare, bronchogenic cysts must be considered in the differential diagnosis of retroperitoneal cystic lesions. This is the first case of a retroperitoneal bronchogenic cyst reported in Iran.

Keywords: bronchogenic cyst, retroperitoneum, adrenal.

Cite this article as: Mirsadeghi A, Farrokhi F, Fazli-Shahri A, Gholipour B. Retroperitoneal bronchogenic cyst: a case report. *Med J Islam Repub Iran* 2014 (13 July). Vol. 28:56.

Introduction

Bronchogenic cysts are benign cystic congenital aberrations resulting from an abnormal budding of the tracheobronchial tree between 26 and 40 days of embryogenesis. They are usually discovered in the thorax, especially in the mediastinum. Rarely, they can develop below the diaphragm, and a retroperitoneal position is exceptionally unusual (1-3). To our knowledge, only 66 cases have been indexed in the Pubmed among the English literature (1-4, 7, 8), and there has been no report in Iran.

Herein, we present a case of bronchogenic cyst occurred in the retroperitoneum in a 23-year-old man with a review of relevant literature.

Case report

A 23-year-old man, who had been injured

during a wrestling competition, was referred to our hospital with an abdominal pain. He had no significant past medical history. On physical examination, he was a thin young patient with stable vital signs. He had pain and mild tenderness in left upper quadrant region. Laboratory tests including complete blood counts, liver function test (LFT) and blood chemistry were normal. Anti-hydatid cyst antibody test was negative. Erythrocyte sedimentation rate (ESR) was high (62 mm/h) and culture for enterococcus was positive. Abdominal computed tomography scan revealed a complicated cystic lesion with dimensions of 118 x 130 mm between spleen and the left kidney and a compression effect into the kidney. The mass had septa and calcification in its inferior part. Using contrast enhancement, no abnormal vessel or enhancement was noted (Fig. 1). Thus the pa-

1. MD, Assistant Professor of Surgery, Department of Surgery Medicine, 22 Bahman Hospital, Mashhad Islamic Azad University, Mashhad, Iran. a.mirsadeghi@yahoo.com

2. MD, Pathologist, Department of Pathology, Razavi Hospital, Mashhad, Iran. farid.farrokhi@gmail.com

3. (Corresponding author) Medical Student, Student Research Committee, Faculty of Medicine, Mashhad Islamic Azad University, Mashhad, Iran. azadehfazli@yahoo.com

4. Medical Student, Student Research Committee, Faculty of Medicine, Mashhad Islamic Azad University, Mashhad, Iran. bahareh.gholipour1@yahoo.com

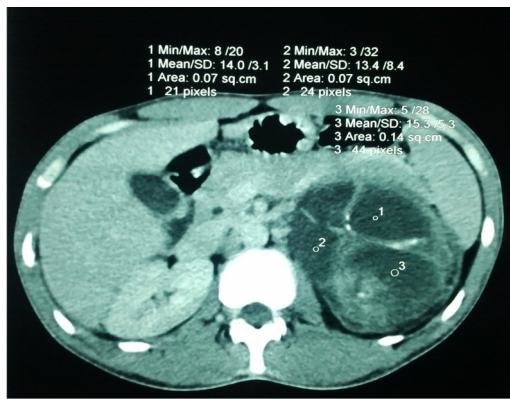


Fig. 1. Computed tomographic scan demonstrating a sharply marginated mass with septa and calcification between spleen and the left kidney with compression effect into the kidney.

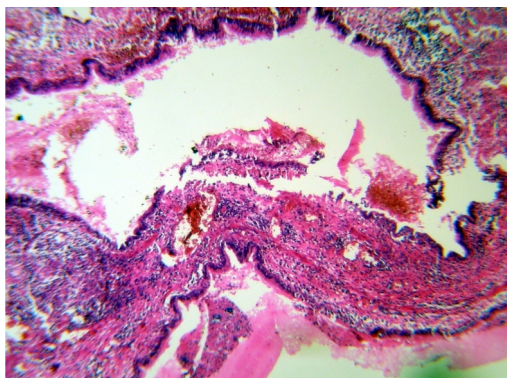


Fig. 2. Microscopic section of the bronchogenic cyst showing cystic cavities lined by pseudostratified cylindrical epithelium on a thick fibrous wall containing cartilage, seromucous glands, smooth muscle fascicles and extensive foci of mononuclear inflammatory cells aggregates (H&E, x 40).

tient underwent a semi-elective operation. During the operation, a huge cystic structure was discovered filled with thick, brownish secretions in retroperitoneal area. The cyst was about 20 x 20 x 20 cm in diameter and adjacent to spleen, adrenal gland and kidney. Postoperative course was uneventful; the patient was discharged on day 3, and had remained asymptomatic during the follow-up period of 4 years.

On gross examination, the specimen consisted of an opened creamy brown ovoid cystic lesion, measuring 10 x 8 x 7 cm with irregular surface. On opening internal surface was brownish and irregular, wall thickness from 0.2 cm to 1.5 cm. The cyst was submitted for microscopic examination.

Histological sections showed fragments of cystic wall, lined by bronchial type pseudostratified cylindrical epithelium resting on fibrovascular connective tissue containing extensive foci of mononuclear inflammatory cells aggregates and presence of smooth muscle fascicles. There were foci of non-neoplastic adrenal tissue attached to external surface of the cystic lesion. A subsequent cytological examination were negative for malignancy and acute inflammatory fluid. These findings were consistent with a bronchogenic cyst (Fig. 2).

Discussion

Bronchogenic cysts are rare primitive foregut-derived developmental anomalies with bronchial type pseudostratified cylindrical epithelium which are usually discovered above the diaphragm. Subdiaphragmatic cysts are extremely rare. Studies have shown that retroperitoneal bronchogenic cysts usually occur in both sexes in equal ratio and a wide age range (1, 3, 4, 8).

Although the exact pathogenesis is still unknown, in 1985, this hypothesis was put forward by Sumiyoshi et al. (1, 3, 8) that a retroperitoneal bronchial cyst can be resulted from pinching off and trapping of the abnormal buds of the tracheobronchial tree after migration in to the abdomen before fusion of the diaphragm components. There is another alternative theory which seems less reliable and described intraabdominal aberrant budding from the primitive foregut (4).

In most instances, retroperitoneal bronchogenic cysts have occurred in the left adrenal gland or the superior body of the pancreas region; and they were asymptomatic and were discovered incidentally during an imaging of the chest (1, 3, 8). There is an increasing tendency between size of the cyst and age of the patient (5).

There are some differential diagnosis for a retroperitoneal cyst lined by pseudostratified ciliated cylindrical epithelium, such as intra-abdominal cystic teratoma, bronchopulmonary sequestration, cyst of urogenital and mullerian origin, and other

foregut cysts, in addition to a bronchogenic cyst. Present of secretory respiratory lining epithelium (cuboid or cylindrical ciliated epithelium) surrounding by smooth muscle similar to those in normal bronchi, as in this case, along with presence of cartilage, elastic tissues and seromucous glands, clarifies a definite pathological diagnosis of bronchogenic cyst (1, 4, 8).

Regardless of being disputable, surgical resection even in asymptomatic cases is recommended to obtain definitive histological diagnosis and avoid future probable development of symptoms and complications, such as infection, hemorrhage, or neoplasia within the cyst (1, 6, 7, 8).

Despite the fact that the occurrence of bronchogenic cysts in the retroperitoneum is extremely rare, and also their preoperative diagnosis is so difficult, they must be considered in the differential diagnosis of retroperitoneal cystic lesions.

References

1. Govaerts K, Eyken PV, Verswijvel G, Speeten KV. A bronchogenic cyst, presenting as a retroperitoneal cystic mass. *Rare Tumors*. 2012 January 2; 4(1): e13.
2. Chu P, Hwang TI, Teng T, Lee C. A retroperitoneal bronchogenic cyst successfully treated by laparoscopic surgery. *Ann Saudi Med* 2007; 27: 199-200.
3. Sohn K, Kim K, Maeng E. Retroperitoneal Bronchogenic Cyst: A Case Report. *J Korean Radiol Soc* 2007; 57: 451-453.
4. Hsieh S, Tseng H, Huang J. Retroperitoneal Bronchogenic Cyst: A Case Report. *Chin Med J (Taipei)* 1997; 59: 311-4.
5. Kim KH, Kim JI, Ahn CH, Kim JS, Ku YM, Shin OR, Lee EJ, Lim KW. The First Case of Intra-peritoneal Bronchogenic Cyst in Korea Mimicking a Gallbladder Tumor. *J Korean Med Sci* 2004 June; 19(3): 470-473.
6. Jo W, Shin JS, Lee IS. Supradiaphragmatic Bronchogenic Cyst Extending Into the Retroperitoneum. *Ann Thorac Surg* 2006; 81: 369-370.
7. Manz M, Schmeer T, Horcic M, Meier R, Maurer CA. Bronchogenic cyst: a rare cause of a retroperitoneal mass. *Zentralbl Chir* 2009 Dec; 134(6): 570-2.
8. Haddadin WJ, Reid R, Jindal RM. A retroperitoneal bronchogenic cyst: a rare cause of a mass in the adrenal region. *J Clin Pathol* 2001 October; 54(10): 801-802.