

Cervical and ocular vestibular evoked myogenic potentials in multiple sclerosis participants

Maryam Sadat Parsa¹, Ghassem Mohammadkhani², Fahimeh Hajabolhassani³
Shohreh Jalaei⁴, Hassanali Zakeri⁵

Received: 22 April 2014

Accepted: 15 September 2014

Published: 26 January 2015

Abstract

Background: Multiple sclerosis (MS) is a chronic neurological disease that affects brain and spinal cord. The infratentorial region contains the cerebellum and brainstem. Vestibular evoked myogenic potentials (VEMPs) are short-latency myogenic responses. Cervical vestibular evoked myogenic potential (cVEMP) is a manifestation of vestibulocolic reflex and ocular vestibular evoked myogenic potential (oVEMP) contributes to the linear vestibular-ocular reflex. The aim of this study was to evaluate cVEMP and oVEMP in MS patients with and without infratentorial plaques and compare the findings with normal controls.

Methods: In this cross-sectional study, latency and amplitude of cVEMP and oVEMP were recorded in 15 healthy females with mean age of 31.13±9.27 years, 17 female MS patients with infratentorial plaque(s) and mean age of 29.88±8.93 years, and 17 female MS patients without infratentorial plaque(s) and mean age of 30.58±8.02 years. All patients underwent a complete clinical neurological evaluation and brain MRI scanning. Simple random sampling method was used in this study and data were analyzed using one way ANOVA through SPSS v22.

Results: The latency of N1-P1 and P13 in MS participants with and without infratentorial plaques were significantly prolonged compared to normal controls ($p<0.001$). Additionally latency of P13-N23-N1 and P1 in MS patients with infratentorial plaques were significantly prolonged compared to patients without infratentorial plaques subjects ($p<0.001$).

Conclusion: Abnormality of both cVEMP and oVEMP in MS patient with infratentorial plaque are more than that of MS patient without infratentorial plaque. Recording both ocular and cervical VEMPs are appropriate electrophysiologic methods assessing the function of both ascending and descending central vestibular pathways.

Keywords: Multiple sclerosis, Cervical, ocular, Vestibular evoked myogenic potential, Infratentorial plaque.

Cite this article as: Parsa M.S, Mohammadkhani Gh, Hajabolhassani F, Jalaei Sh, Zakeri H. Cervical and ocular vestibular evoked myogenic potentials in multiple sclerosis participants. *Med J Islam Repub Iran* 2014 (26 January). Vol. 29:164.

Introduction

Multiple sclerosis (MS) is a chronic neurological disease that affects brain and spinal cord. Most people are diagnosed between the ages of 20-40. It is estimated that women are affected three times more than men (1).

MS damages the myelin sheath involving the white matters of central nervous system. Tentorial incisure (also known as the tentorial notch or incisura tentorii) refers to an extension of one of the membranes covering the cerebrum which, with the transverse fissure, separates the cerebrum from

1. MSc in Audiology, Department of Audiology, Faculty of rehabilitation, Tehran University of medical sciences, Tehran, Iran. m.parsa1989@gmail.com

2. (Corresponding author) Assistant Professor, PhD in Audiology, Department of Audiology, Faculty of rehabilitation, Tehran University of Medical Sciences, Tehran, Iran. mohammadkhani@tums.ac.ir

3. Lecturer of Audiology, Faculty of rehabilitation, Tehran University of Medical Sciences, Tehran, Iran. abolhassani@tums.ac.ir

4. Assistant Professor, PhD in Biostatistics, Department of physiotherapy, Faculty of rehabilitation, Tehran University of Medical Sciences, Tehran, Iran. jalaeish@sina.tums.ac.ir

5. Neurologist, Tehran University Medical Sciences, Tehran, Iran. gm_khani@yahoo.com.

the cerebellum. The infratentorial region of the brain is the area located below the tentorium cerebelli. The infratentorial region contains the cerebellum and brainstem (2, 3).

Evoked potentials play an important role in the diagnosis and follow up of MS. They can detect subclinical lesions and provide information on the function of different parts of the nervous system (4).

Vestibular evoked myogenic potentials (VEMPs) are short-latency myogenic responses which are evoked by brief pulses of air conducted (AC) acoustic signals, bone conducted (BC) vibration or electrical stimulus. VEMPs are recorded via surface electrodes over surface of muscles such as sternocleidomastoid (SCM) (5). Cervical vestibular evoked myogenic potential (cVEMP) was first described by Colebatch et al (1992), and now has become an accepted test of vestibular functions. The cVEMPs are recorded from the SCM or trapezius muscles (5). It is a manifestation of vestibulocolic reflex. An auditory tone burst stimulation leads to activation of the saccular vestibular neurons, which in turn cause a modulation of tonic muscle activity of the SCM muscle. The measurement of the VEMPs requires tonic contraction of ipsilateral SCM muscle (6). The cVEMP response has two main peaks, labeled P13 and N23 (7).

In recent decade VEMPs have been recorded from the extraocular muscles (ocular or oVEMP) (8, 9). In this test loud acoustical stimuli produce vestibular dependent responses in the extraocular muscles. The responses are believed to be originated from the otoliths and they contributed to the linear vestibular-ocular reflex (10). The primary oVEMP projection appears to be crossed and the initial negative peak occurred at about 10 ms.

Studies have shown infratentorial plays an important role in the transition, perception and interpretation of vestibular information and also both the vestibule-ocular and vestibulocolic pathways pass from this area. Therefore, the lesions in this region

can significantly impact on the balance and cVEMP and oVEMP. Since the impact of plaque(s) in the infratentorial on the cVEMP and oVEMP is not investigated, the aim of this study was to compare cervical and ocular vestibular evoked myogenic potentials in multiple sclerosis patients with and without infratentorial plaque(s) and compare the findings with normal controls.

Methods

In this cross-sectional study cVEMP and oVEMP were performed on 15 healthy female subjects with mean age of 31.13 ± 9.27 years, 17 female patients with definite MS according to the MC Donald criteria 2005, with infratentorial plaque(s) with mean age of 29.88 ± 8.93 years and 17 female MS patients with definite MS without infratentorial plaque(s) with mean age of 30.58 ± 8.02 years.

MC Donald criteria 2005 incorporated magnetic resonance imaging (MRI) into the well-established diagnostic workup that focuses on detailed neurological history and examination and a variety of paraclinical laboratory examinations such as cerebrospinal fluid analysis (11, 12).

All tests of the present study did from October to December 2013 in Tehran University of Medical Science.

All participants were evaluated using otoscopy and audiometric testing before study. Subjects with abnormal audiometric results (hearing thresholds worse than 20 dB HL)(13), with a history of seizures, depression, and head trauma and neck or eye movement limitation like strabismus and cervical arthritis were excluded. All patients underwent a complete clinical neurological evaluation and brain MRI scanning within three weeks. Then patients were divided into two groups consisting of patients with and without infratentorial plaque(s).

To record cVEMPs, subjects were sat on a comfortable chair, turned their head opposite to the side of the stimulated ear in order to flex the SCM muscle. Contraction of SCM muscle was monitored with manometer. In this way subjects pushing with

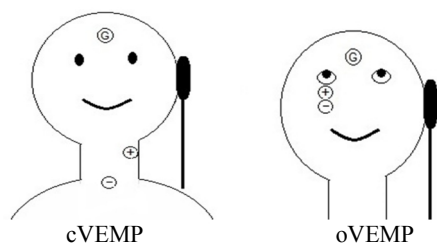


Fig. 1. Electrodes in cVEMP and oVEMP

their jaw against the hand-held inflated cuff to generate a 40 millimeter of mercury cuff pressure (14). After cleaning the skin active surface electrode was placed on the upper half of each SCM muscle with a reference electrode over the upper sternum and a ground electrode over central forehead(15) (Figure1). Cervical VEMPs were recorded from ipsilateral SCM muscle (from the stimulated side) in response to AC 500 Hz short tone burst delivered via insert ear-phones at 95 dB nHL.

For recording of oVEMP, subjects were in a sitting position. For each eye the active recording electrode was placed on the infraorbital ridge 1 cm below the center of each lower eyelid and the reference was positioned about 1-2 cm below the active one and ground electrode was placed on the sternum (16) (Fig.1). During recording, the subjects were instructed to look upward at a small fixed target >2m from the eyes, with a vertical visual angle of approximately 30-

35 degrees above the horizontal plane (17). Contraction of contralateral extraocular muscle was monitored with degree of visual angle (18).

Ocular VEMPs were recorded over the contralateral extraocular muscle (from the stimulated side) in response to AC 500 Hz short tone burst delivered via insert ear-phones at 95 dB nHL. Both cVEMP & oVEMP were performed using GN Otometric- ICS CHARTER EP.

Data were analyzed using one way ANOVA and paired t-test because the distribution of data was normal according to the Kolmogorov-Smirnov test and $p < 0.05$ was considered statistically significant. SPSS software version 22 was used in this study. Tehran University of Medical Sciences Ethical Committee approved this study, and informal consent was obtained from each subjects.

Results

The mean latency and amplitude of P13, N23, N1 and P1 in all participants have been showed in Table 1. Sample of cVEMPs and oVEMPs in three groups are shown in Fig. 2.

In the control group cVEMPs and oVEMP were recorded from both sides of all participants. Analysis showed no significant differences between the mean latency and amplitude of P13, N23, N1 and P1 in

Table1. Descriptive statistics of oVEMP and cVEMP in all groups

Group	Tests	Peaks	Latency (ms)		Amplitude(μ V)		
			Mean \pm (SD)		Mean \pm (SD)		
			Right	Left	Right	Left	
Normal	cVEMP	P13	15/25 \pm 0/90	15/31 \pm 0/93	180/00 \pm 44/97	175/66 \pm 57/59	
		oVEMP	N23	24/55 \pm 1/07	24/48 \pm 1/18		
			N1	10/19 \pm 0/48	10/29 \pm 0/51	12/77 \pm 4/12	12/60 \pm 4/04
MS without infra tentorial plaque	cVEMP	P1	15/07 \pm 0/87	14/86 \pm 0/84			
		P13	17/44 \pm 1/03	17/21 \pm 1/05	135/83 \pm 20/31	133/78 \pm 22/89	
		N23	26/89 \pm 1/87	26/87 \pm 1/36			
MS with infra tentorial plaque	oVEMP	N1	12/21 \pm 1/00	11/78 \pm 0.89	6/61 \pm 0/60	6/82 \pm 0/75	
		P1	16/9 \pm 1/32	16/92 \pm 0/82			
		P13	18/75 \pm 1/81	19/11 \pm 1/72	118/82 \pm 29/79	119/65 \pm 26/02	
	cVEMP	N23	28/15 \pm 1/43	28/88 \pm 2/27			
		oVEMP	N1	15/67 \pm 1/32	15/74 \pm 1/66	6/61 \pm 0.88	6/48 \pm 0/68
			P1	20/59 \pm 1/65	21/40 \pm 2/88		

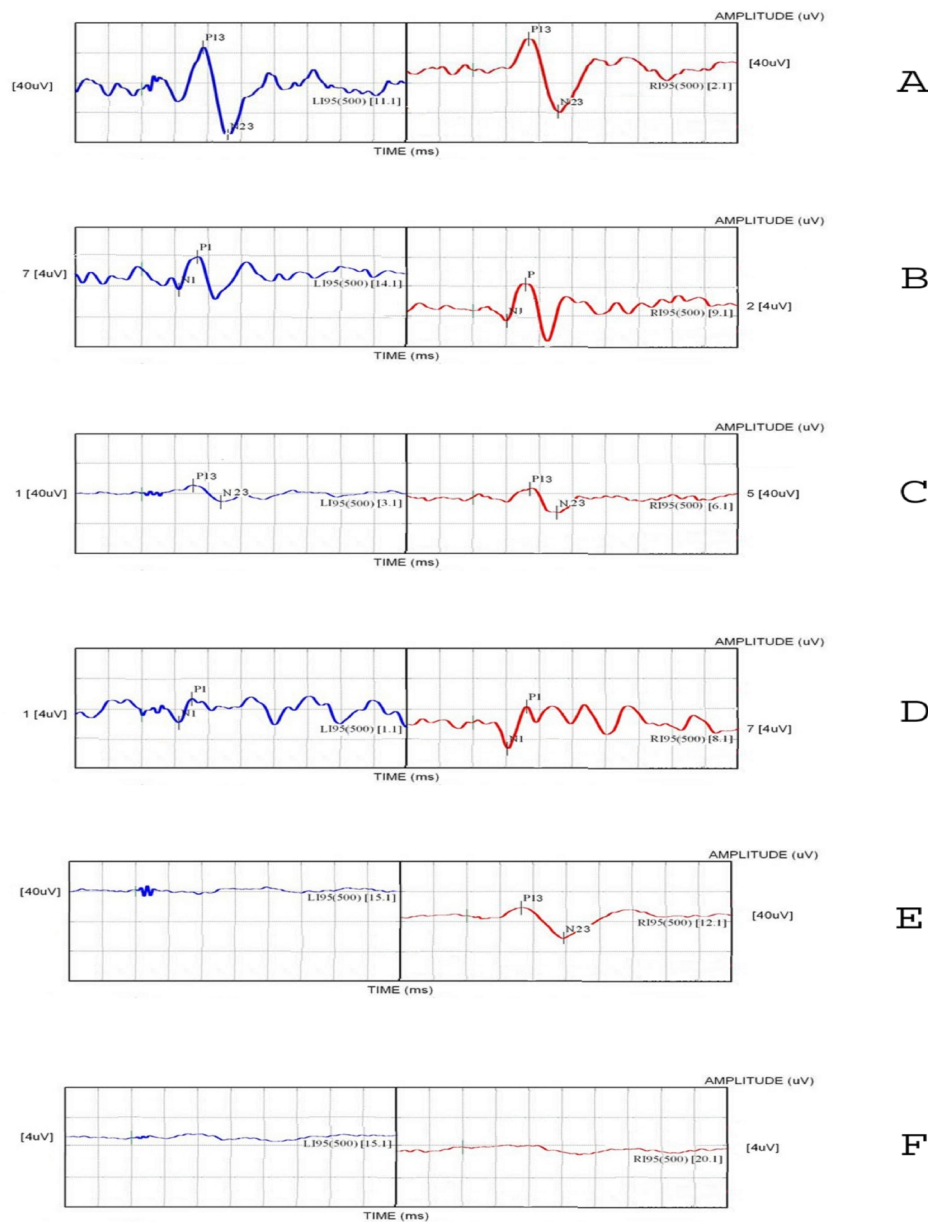


Fig. 2. Sample of cVEMPs and oVEMPs in control group (A&B), in MS patients without infratentorial plaques (C&D) and in MS patients with infratentorial plaques (E&F)

right and left side ($p>0.05$).

In multiple sclerosis patients without infratentorial plaques cVEMPs were recorded from both sides of all patients but oVEMP were recorded from both sides in 64.7% ($n=11$) patients and recorded from one side in 11% ($n=2$) patients and not recorded bilaterally in 23.5% patients ($n=4$). Statistical analysis showed no significant differences between the mean latency and amplitude of

P13, N23, N1 and P1 in right and left side ($p>0.05$).

In multiple sclerosis patients with infratentorial plaques cVEMPs were recorded from both sides in 59.0% ($n=10$) of patients and from one side in 17% ($n=3$) of patients and not recorded in 23.5% ($n=4$) of patients. Ocular VEMPs were recorded from both sides in 23.5% ($n=4$) of patients and recorded from one side in 23.5% ($n=4$) of

patients and not recorded in 52.59% (n=9) of patients. Analysis showed no significant differences between the mean latency and amplitude of P13, N23, N1 and P1 in right and left side ($p>0.05$).

Statistical analysis showed the latency of N1, P1 and P13 in multiple sclerosis with and without infratentorial plaques were significantly prolonged compared to normal controls ($p<0.001$). Also latency of P13, N23, N1 and P1 in MS patients with infratentorial plaques were significantly prolonged compared to patients without infratentorial plaques subjects ($p<0.001$). There was no significant difference in the mean amplitude of both oVEMP & cVEMP between MS patients with infratentorial plaque(s) and MS patients without infratentorial plaque(s) ($p>0.05$).

Discussion

The aim of the present study was to evaluate cVEMP & oVEMP in MS patients with and without infratentorial plaques and compare the findings with normal controls.

The latency of N1-P1-P13 were significantly longer in MS patients with and without infratentorial plaque(s) compared to control subjects and latency of P13-N23-N1&P1 in MS patients with infratentorial plaques were significantly prolonged compared to patients without infratentorial plaques. Prolonged latency of VEMPs in MS patients has been reported in previous studies (18-21). Only latency of N23 peak of MS patient without infratentorial plaque(s) was not significantly different compared to normal controls probably because of larger normal limits which has been reported in previous studies (21). Prolonged latency of VEMPs are not specific for MS and cannot help distinguish MS from other etiologies (18, 22, 23). Delays of latency in VEMPs have been seen in other neurological disease that affecting brainstem such as stroke and tumors(24).

Overall in the present study 64.25% had some form of cVEMP abnormality and 85.66% had some form of oVEMP abnormality in MS patients with infratentorial

plaque(s). In MS patients without infratentorial plaque(s) abnormality of cVEMP & oVEMP were seen in 18.26% and 45.28% of patients, respectively. Data showed ocular VEMPs are often abnormal in patients with infratentorial plaques, because ocular VEMP pathway passes through the brainstem which is in the infratentorial zone. The abnormality percentage of oVEMPs was higher than that of the cVEMPs in our study in both MS patient groups. Our results showed that oVEMPs is more sensitive than cVEMPs in MS(18, 20).

VEMPs are capable to demonstrate sub-clinical dysfunctions or silent lesions. In MS patients without infratentorial plaque(s) 43.23% of cVEMP and 61.48% oVEMP were abnormal. Clinically silent lesions can explain physiologic changes that are not accompanied by physical signs or symptoms. Perhaps small demyelinating lesions not detected by MRI can produce slow nerve conduction velocity (18, 19, 21, 23). VEMPs can also demonstrate clinical dysfunction. In this study cVEMP abnormalities were seen in 73.43% and oVEMP abnormalities were seen in 94.11% of MS patients with infratentorial plaque(s). Most common abnormality found in MS patients with infratentorial plaque(s) was absent response and the other abnormality was latency prolongation. Demyelination can cause speed reduction which can result in slow nerve conduction velocity. However severe demyelinating lesions can cause conduction block or desynchronized conduction (19, 21).

There were no statistically significant differences between the mean amplitude of cVEMP and oVEMP of both MS groups with normal subjects. This VEMP parameter in MS patient is not a proper diagnostic criteria because other variables such as muscle contraction and stimulus intensity can affect it (18, 23, 25). Amplitudes of VEMPs responses should not be used alone and should be interpreted together with latency values in MS patients (23).

Conclusion

Findings of the current study showed that abnormality of both cVEMP and oVEMP in MS patient with infratentorial plaque are more than that of MS patient without infratentorial plaque. Recording both ocular and cervical VEMPs are appropriate electrophysiological methods assessing the function of both ascending and descending central vestibular pathways in diagnosis, monitoring disease progression and rehabilitation in MS patients.

Acknowledgements

This research was supported by Tehran University of Medical Sciences, grant number: 92/d/260/1760.

References

1. MacAlpine D, Compston A. *MacAlpine's Multiple Sclerosis*: Elsevier Health Sciences; 2005.
2. Lang J. *Anatomy of the tentorial margin. Extra-Intracranial Vascular Anastomoses Microsurgery at the Edge of the Tentorium*: Springer; 1985;173-82.
3. Ono M, Ono M, Rhoton Jr AL, Barry M. Microsurgical anatomy of the region of the tentorial incisura. *Journal of neurosurgery*. 1984;60(2):365-99.
4. Alpini D, Pugnetti L, Caputo D, Cornelio F, Capobianco S, Cesarani A. Vestibular evoked myogenic potentials in multiple sclerosis: clinical and imaging correlations. *Multiple sclerosis*. 2004; 10(3):316-21.
5. Rosengren S, Welgampola M, Colebatch J. Vestibular evoked myogenic potentials: past, present and future. *Clinical neurophysiology*. 2010; 121(5):636-51.
6. Murofushi T, Iwasaki S, Ozeki H, Ushio M, Chihara Y. Tone burst-galvanic ratio of vestibular evoked myogenic potential amplitudes: A new parameter of vestibular evoked myogenic potential? *Clinical neurophysiology*. 2007;118(8):1685-90.
7. Halmagyi G, Colebatch J, Curthoys I. New tests of vestibular function. *Bailliere's clinical neurology*. 1994; 3(3):485-500.
8. Rosengren S, McAngus Todd N, Colebatch J. Vestibular-evoked extraocular potentials produced by stimulation with bone-conducted sound. *Clinical neurophysiology*. 2005;116(8):1938-48.
9. Todd NPMA, Rosengren SM, Aw ST, Colebatch JG. Ocular vestibular evoked myogenic potentials (OVEMPs) produced by air-and bone-conducted sound. *Clinical neurophysiology*. 2007; 118(2):381-90.
10. Angelaki DE. Eyes on target: what neurons must do for the vestibuloocular reflex during linear motion. *Journal of neurophysiology*. 2004;92(1):20-35.
11. Polman CH, Reingold SC, Edan G, Filippi M, Hartung HP, Kappos L, et al. Diagnostic criteria for multiple sclerosis: 2005 revisions to the "McDonald Criteria". *Annals of neurology*. 2005;58(6):840-6.
12. Polman CH, Reingold SC, Banwell B, Clanet M, Cohen JA, Filippi M, et al. Diagnostic criteria for multiple sclerosis: 2010 revisions to the McDonald criteria. *Annals of neurology*. 2011; 69(2): 292-302.
13. Gelfand SA. *Essentials of audiology*: Thieme; 2009.
14. Vanspauwen R, Wuyts FL, Van de Heyning PH. Improving vestibular evoked myogenic potential reliability by using a blood pressure manometer. *The Laryngoscope*. 2006;116(1):131-5.
15. Chiarovano E, Zamith F, Vidal PP, de Waele C. Ocular and cervical VEMPs: A study of 74 patients suffering from peripheral vestibular disorders. *Clinical neurophysiology*. 2011.
16. Iwasaki S, Smulders Y, Burgess A, McGarvie L, MacDougall H, Halmagyi G, et al. Ocular vestibular evoked myogenic potentials to bone conducted vibration of the midline forehead at Fz in healthy subjects. *Clinical neurophysiology*. 2008; 119(9):2135-47.
17. Govender S, Rosengren SM, Colebatch JG. The effect of gaze direction on the ocular vestibular evoked myogenic potential produced by air-conducted sound. *Clinical neurophysiology*. 2009; 120(7):1386-91.
18. Gazioglu S, Boz C. Ocular and cervical vestibular evoked myogenic potentials in multiple sclerosis patients. *Clinical neurophysiology*. 2012.
19. Rosengren S, Colebatch J. Ocular vestibular evoked myogenic potentials are abnormal in internuclear ophthalmoplegia. *Clin Neurophysiol*. 2011 Jun; 122(6):1264-7.
20. Rosengren SM, Nogajski JH, Cremer PD, Colebatch JG. Delayed vestibular evoked responses to the eyes and neck in a patient with an isolated brainstem lesion. *Clinical neurophysiology*. 2007; 118(9):2112-6.
21. Patkó T, Simó M, Arányi Z. Vestibular click-evoked myogenic potentials: sensitivity and factors determining abnormality in patients with multiple sclerosis. *Multiple sclerosis*. 2007;13(2):193-8.
22. Eleftheriadou A, Deftereos S, Zarikas V, Panagopoulos G, Sfetsos S, Karageorgiou C, et al. The diagnostic value of earlier and later components of Vestibular Evoked Myogenic Potentials (VEMP) in Multiple Sclerosis. *Journal of Vestibular Research*. 2009;19(1):59-66.
23. Bandini F, Beronio A, Ghiglione E, Solaro C, Parodi R, Mazzella L. The diagnostic value of vestibular evoked myogenic potentials in multiple sclerosis. *Journal of neurology*. 2004;251(5):617-21.

24. Su CH, Young YH. Differentiating cerebellar and brainstem lesions with ocular vestibular-evoked myogenic potential test. *Eur Arch Otorhinolaryngol.* 2011;Jun; 268(6):923-30.

25. Pollak L, Kushnir M, Stryjer R. Diagnostic

value of vestibular evoked myogenic potentials in cerebellar and lower-brainstem strokes. *Neurophysiologie Clinique/Clinical Neurophysiology.* 2006; 36(4):227-33.