

## Retroperitoneal Castleman disease: report of a case and review of the literature

A. Ghafouri, MD.<sup>1</sup>, N. Mousavi, MD.<sup>2</sup>, M. Shamekhi Amiri, MD.<sup>3</sup>, AR Soroush, MD.<sup>4</sup>

*Department of Surgery, School of Medicine, Tehran University of Medical Sciences, Tehran, Iran.*

### Abstract

Castleman disease or giant node hyperplasia is a rare disorder of the lymphoid tissue most often involving the mediastinal lymph nodes. We report a case of localized retroperitoneal hyaline-vascular type of Castleman disease. A 35-year old woman presented with mild epigastric pain with radiation to the back. A mild anemia was the only abnormal associated finding. Abdominal ultrasound and CT- scan showed a homogeneous well-demarcated mass beneath the pancreas. Excisional biopsy on laparotomy revealed a highly vascular encapsulated mass with a diameter of 6 centimeters. Histopathology examination was diagnostic: hyaline-vascular type Castleman disease.

Castleman disease, although rare, is one of the differential diagnoses of a retroperitoneal mass, most often discovered incidentally or due to pain and compressive symptoms. Excision is both diagnostic and curative for management of the localized form of Castleman disease.

**Keywords:** Castleman disease, giant lymph node hyperplasia, localized

### Introduction

Castleman disease or giant lymph node hyperplasia is an uncommon disorder first described by Castleman and Towne in 1954. The most commonly involved regions are the mediastinal lymph nodes; rarely cervical, abdominal, and other lymph node basins are affected.

We encountered a case of retroperitoneal Castleman disease, presenting with abdominal pain, believed to have been a pancreatic tumor.

### Case report

A 35 year-old woman was admitted to hospital complaining of vague epigastric pain during the

past 2 months. The pain had radiation to the back and left shoulder and improved with leaning forward. No other accompanying symptoms were present except occasional sweating. The history and family history were negative and physical examination was normal. A mild hypochromic microcytic anemia was the only abnormal finding on laboratory tests.

Abdominal ultrasound showed a well-demarcated mass 5 cm in diameter at the inferior border of the pancreatic body. Spiral abdominal CT- scan revealed a well-defined homogeneous mass, enhancing with contrast injection (Fig. 1).

On exploration, a highly vascularized encapsulated mass with a diameter of 6 cm was found in the retroperitoneum just beneath the pancre-

1. **Corresponding author**, Professor of General and Thoracic Surgery, Tehran University of Medical Sciences, Shariati Teaching Hospital School of Medicine, Kargar-e-Shomali Ave. Tehran, Iran. Tel:+982188638065-70, email: aghafouri@sina.tums.ac.ir.

2&3. Resident of General Surgery, Shariati Teaching Hospital, School of Medicine, Tehran University of Medical Sciences.

4. Assistant Professor of Surgery, Shariati Teaching Hospital, School of Medicine, Tehran University of Medical Sciences.

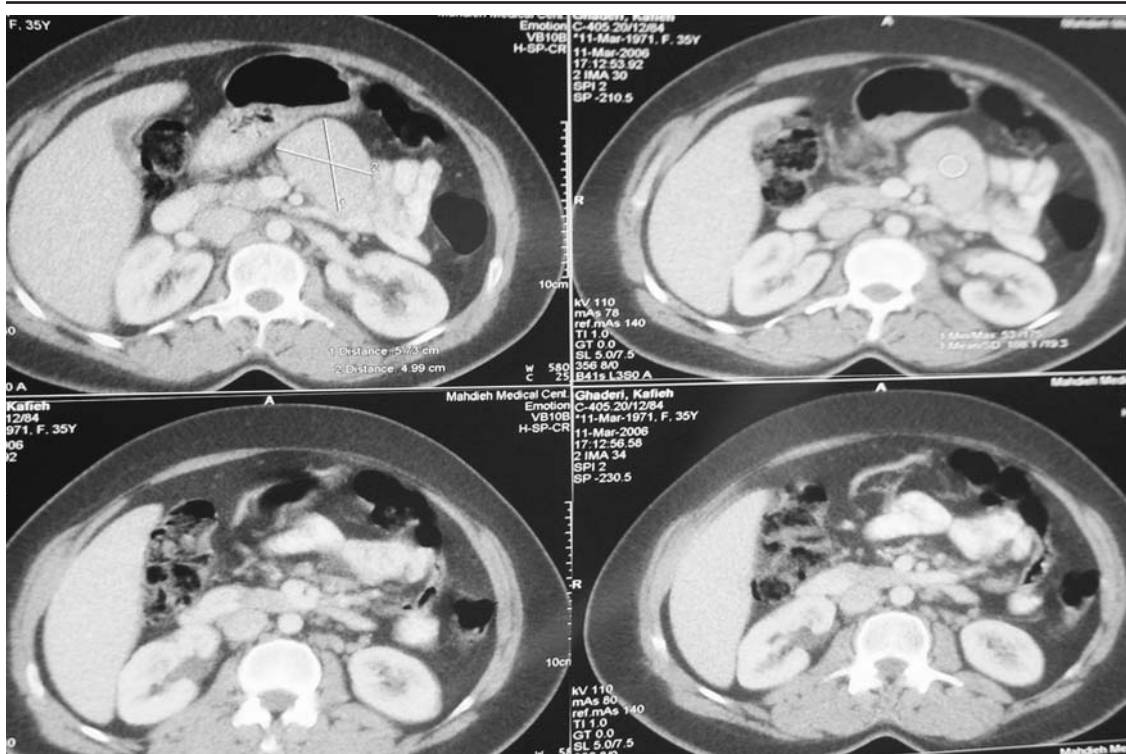

Fig. 1. CT-scan of the patient.

atic body pushing it somewhat upward.

The inferior boarder of the tumor had dense adhesions to the base of the transverse mesocolon. The mass was excised completely and the defect in the mesocolon was repaired (Fig. 2).

Gross pathology showed an encapsulated solid mass with a creamy-red surface. On microscopic examination, numerous evenly distributed follicles with small involuted germinal centers with hyalinization were seen, surround-

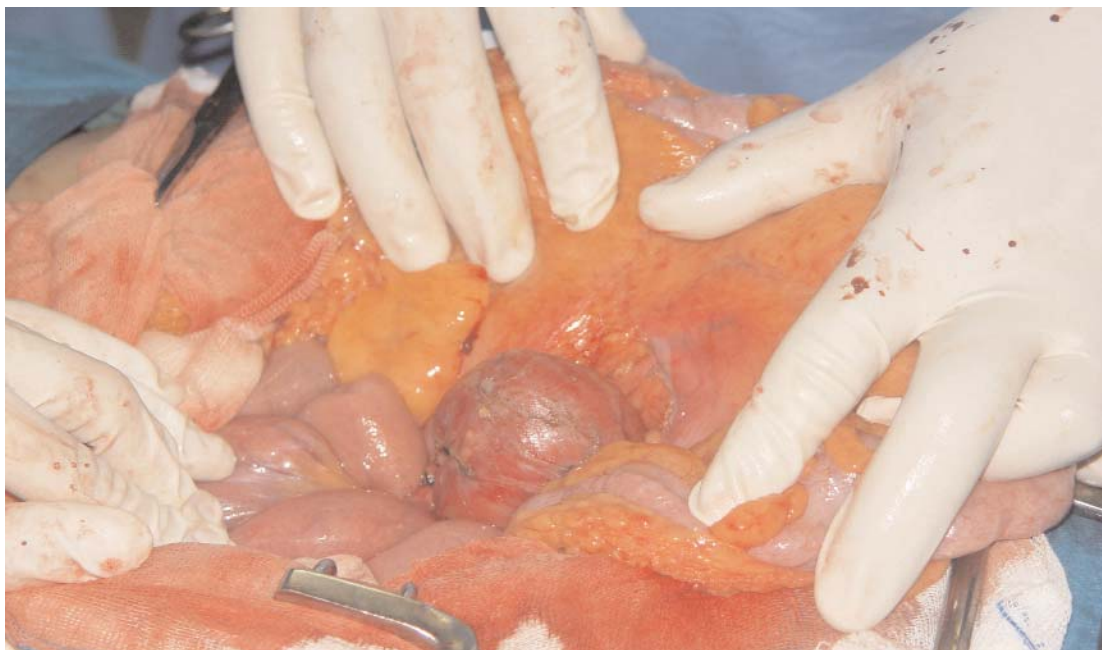


Fig. 2. Laparotomy revealing the mass.

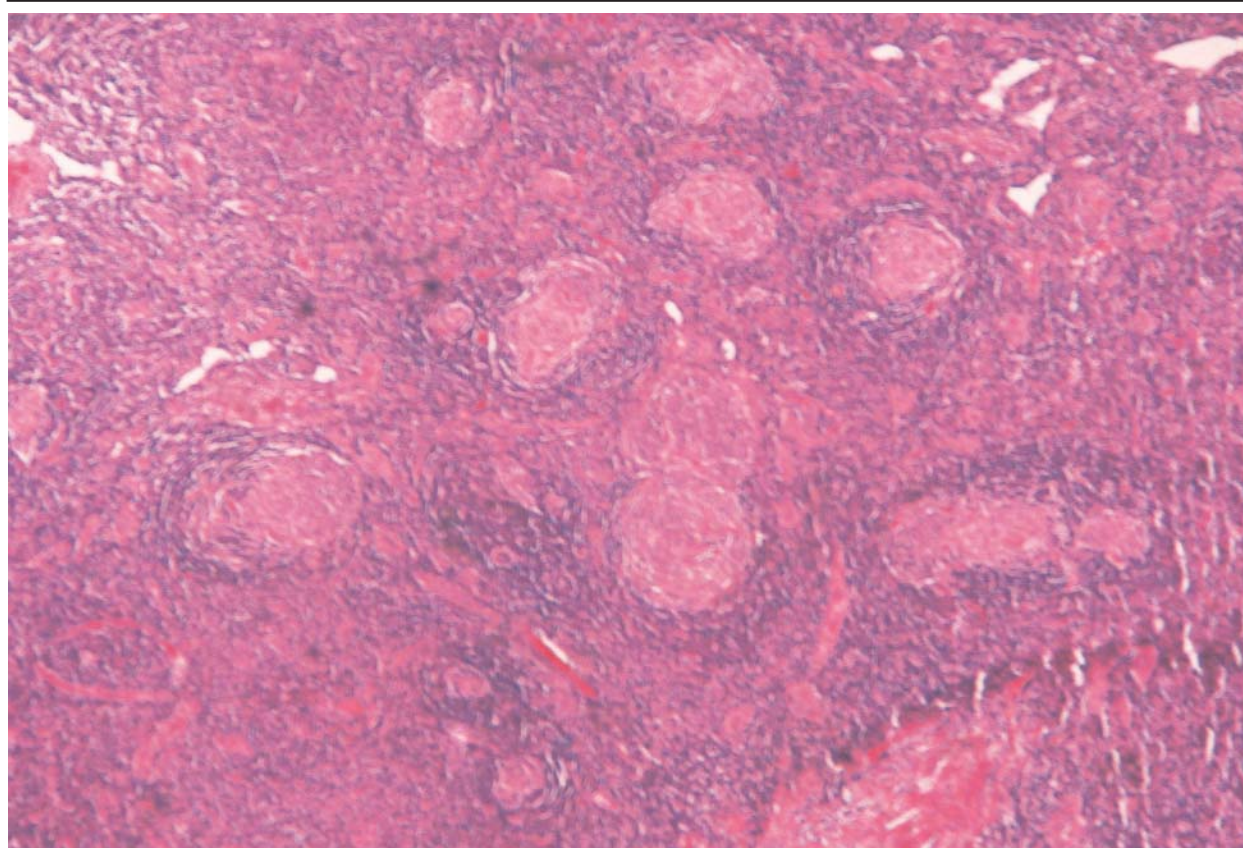


Fig. 3. Pathology of the tumor.

ed by small concentric lymphocytes.

In the interfollicular space, numerous post-capillary venules and lymphoid cells were seen, proposing the diagnosis of hyaline-vascular type Castleman disease (Fig. 3). The patient was discharged after complete recovery.

### Discussion

The localized form of Castleman disease first described by Castleman and Towne in 1956 is a rare disease involving the lymphoid system, most commonly the mediastinal and cervical lymph nodes [1].

Retroperitoneal involvement is rarely seen; in a report of 81 cases, only one was abdominal [2,3].

Castleman disease is seen in all age groups, with a mean age of 43 years at diagnosis [4].

The etiology is suspected to be autoimmune in origin. Overproduction of interleukin-6 by the lymphoblastic lymph node is believed to

have a central role in both the localized and the multicentric form. Two histological variants have been described. The more frequent hyaline-vascular type shows small hyaline-vascular follicles and interfollicular capillary proliferation. The plasma cell type is characterized by large follicles with intervening sheets of plasma cells. This type is often associated with systematic anemia, elevated sedimentation rate, hypergammaglobulinemia and hypoalbuminemia, all normalizing after resection of the tumor. The hyaline-vascular type is not associated with systemic manifestations and is usually discovered incidentally or due to compressive symptoms. Only minor hematologic abnormalities are reported in a few patients (3%); as in our case with the only abnormal finding being mild anemia [2].

“Multicentric” Castleman disease indicates a clinicopathologic entity characterized by the histology of Castleman disease of “mixed”



type, a predominately-lymphadenopathic presentation consistently involving peripheral nodes, manifestations of multisystem involvement and association with Kaposi sarcoma, Human Herpes Virus-8, "POEMS" syndrome and rarely AIDS [5,6].

The hyaline-vascular type lesion usually presents as a single rounded mass with a median size of 5 to 6 centimeters. Adjacent lymph nodes are sometimes enlarged, often similar in structure to the main mass [2].

On ultrasound, a uniform hypo-echoic mass similar to lymphoma can be seen. CT- scan usually shows a solid homogeneously enhanced hypo- to isodense mass. On MRI a nearly isointense to muscle in signal, intensity on T1-weighted image and heterogeneous signal characteristics within the mass on T2- weighted image can be seen [7].

Prominent vascularity of the mass and excessive bleeding is sometimes encountered, correlating with the microscopic vascular proliferation and contrast enhancement on CT-scan. This feature, as encountered in our case, can be challenging for the resection of the tumor, especially in the retroperitoneal and peripancreatic region.

The treatment of choice for localized disease is surgical excision that is both diagnostic and curative. Radiotherapy can also achieve clinical response and cure in selected patients. Multicentric castleman disease does not benefit from surgery and is best treated with combination chemotherapy [8,9].

### Discussion

Castleman disease, although rare, is one of the differential diagnoses of a retroperitoneal mass. It is most often discovered incidentally or due to pain and compressive symptoms. Excision and histopathologic examination leads to the diagnosis and is simultaneously curative for the localized form of Castleman disease.

### References

1. Castleman B, Towne VW. Case reports of Massachusetts General Hospital; Weekly clinicopathological exercises; founded by Richard C. Cabot. Case 40011.N *Engl J Med* 1954; 250:26-30.
2. Keller AR, Hochholzer L, Castleman B. Hyaline vascular and plasma cell types of giant lymph node hyperplasia of the mediastinum and other locations. *Cancer* 1972; 29:670-83.
3. Erkan N, Yildirim M, Selek E, et al. Peripancreatic Castleman disease. *JOP. J Pancreas (online)* 2004; 5(6): 491-496.
4. Sarrot-Reynauld F, Morand P, Buisson M, et al. Groupe francais d'etude de la maladie de Castleman. Maladie de Castleman et infection par le virus HHV-8. *Rev. Med Interne* 1998; 19:4135.
5. Frizzera G. Castleman disease and related disorders. *Semin Diagn Pathol.* 1998 Nov; 5(4): 346-64.
6. Peterson BA, Frizzera G. Multicentric Castleman's disease. *Semin Oncol* 1993; 20:636-47.
7. Barki Y, Shadked G, Levi I. Mesentric Castleman disease: sonographic diagnosis. *J Clin Ultrasound* 1992; 20:486-8.
8. Bowne WB, Lewis JJ, Fillippa DA, et al. The management of unicentric and multicentric Castleman disease: a report of 16 cases and a review of the literature. *Cancer* 1999; 85: 706-17.
9. Chronowski GM, Ha CS, Wilder RB, et al. Treatment of unicentric and multicentric Castleman disease and the role of radiotherapy. *Cancer* 2001; 92:670-6.